This is a digital copy of a book that was preserved for generations on library shelves before it was carefully scanned by Google as part of a project to make the world's books discoverable online.

It has survived long enough for the copyright to expire and the book to enter the public domain. A public domain book is one that was never subject to copyright or whose legal copyright term has expired. Whether a book is in the public domain may vary country to country. Public domain books are our gateways to the past, representing a wealth of history, culture and knowledge that's often difficult to discover.

Marks, notations and other marginalia present in the original volume will appear in this file - a reminder of this book's long journey from the publisher to a library and finally to you.

Usage guidelines

Google is proud to partner with libraries to digitize public domain materials and make them widely accessible. Public domain books belong to the public and we are merely their custodians. Nevertheless, this work is expensive, so in order to keep providing this resource, we have taken steps to prevent abuse by commercial parties, including placing technical restrictions on automated querying.

We also ask that you:

+ *Make non-commercial use of the files* We designed Google Book Search for use by individuals, and we request that you use these files for personal, non-commercial purposes.
+ *Refrain from automated querying* Do not send automated queries of any sort to Google's system: If you are conducting research on machine translation, optical character recognition or other areas where access to a large amount of text is helpful, please contact us. We encourage the use of public domain materials for these purposes and may be able to help.
+ *Maintain attribution* The Google "watermark" you see on each file is essential for informing people about this project and helping them find additional materials through Google Book Search. Please do not remove it.
+ *Keep it legal* Whatever your use, remember that you are responsible for ensuring that what you are doing is legal. Do not assume that just because we believe a book is in the public domain for users in the United States, that the work is also in the public domain for users in other countries. Whether a book is still in copyright varies from country to country, and we can't offer guidance on whether any specific use of any specific book is allowed. Please do not assume that a book's appearance in Google Book Search means it can be used in any manner anywhere in the world. Copyright infringement liability can be quite severe.

About Google Book Search

Google's mission is to organize the world's information and to make it universally accessible and useful. Google Book Search helps readers discover the world's books while helping authors and publishers reach new audiences. You can search through the full text of this book on the web at `http://books.google.com/`

Digitized by Google

1905 wanting

Digitized by Google

Digitized by Google

Digitized by Google

Digitized by Google

TRANSACTIONS OF THE

SECTION ON CUTANEOUS MEDICINE AND SURGERY

of the
American Medical Association
at the Fifty-fifth Annual Session, held at Atlantic City, N. J., June 7 to 10, 1904

AMERICAN MEDICAL ASSOCIATION PRESS
CHICAGO: NINETEEN HUNDRED AND FOUR

Digitized by Google

CATALOGU
MAY 5
M. L.

BOSTON
MAY 5 1936
MEDICAL LIBRARY

CATALOGUED
MAY 5 1936
M. L.

Digitized by Google

OFFICERS FOR 1903-1904

CHAIRMAN.

HENRY G. ANTHONY - - - - - - CHICAGO.

SECRETARY.

R. R. CAMPBELL - - - - - - - CHICAGO.

EXECUTIVE COMMITTEE.

W. L. BAUM, CHICAGO.

HENRY W. STELWAGON, PHILADELPHIA.

JOHN A. FORDYCE, NEW YORK.

OFFICERS FOR 1904-1905

CHAIRMAN.

DOUGLAS W. MONTGOMERY - - - SAN FRANCISCO.

SECRETARY.

R. R. CAMPBELL - - - - - - - CHICAGO.

EXECUTIVE COMMITTEE.

HENRY W. STELWAGON, PHILADELPHIA.

JOHN A. FORDYCE, NEW YORK.

HENRY G. ANTHONY, CHICAGO.

Digitized by Google

Digitized by Google

CONTENTS

PAGE.

Chairman's Address. Developmental Defects of the Skin and Their Malignant Growths. H. G. Anthony 9
Falling of the Hair. R. A. McDonnell 28
Radium and Its Therapeutic Possibilities. W. A. Pusey .. 41
Case of Darier's Disease. D. Lieberthal 66
A False or Cicatricial Keloid. A. Ravogli 80
Hyperidrosis Pedum and Its Treatment by Baths of Permanganate of Potash. L. Weiss 95
Acne Keratosa. W. S. Gottheil 113
Prurigo (Hebra) as Observed in the United States. W. T. Corlett 123
Cutaneous Manifestations in Diabetes Insipidus. A. W. Brayton 129
Cover-glass Cultures and Their Possibilities in Studying Epidermic Fungi. J. F. Wallis 137
Continuous Acrodermatitis. An Instance Where It Was Controlled by the X-Ray. D. W. Montgomery 150
Diagnosis of Scarlet Fever and Scarlatinoid Affections. J. F. Schamberg 155
Comparison of Phototherapy, Radiotherapy, and High-Frequency Therapy in Skin Diseases. C. W. Allen 165
X-Ray Therapy in Skin Diseases. G. E. Pfahler 184
Consideration of Late Hereditary Syphilis. R. R. Campbell 195
Xanthoma. J. V. Shoemaker 210
Practical Notes on Ointments, Their Use and Abuse. L. D. Bulkley 227
Linear Nevi. A Few Clinical and Pathologic Considerations in Reference to Nevi in Particular and to Dermatology in General. M. L. Heidingsfeld 239
Treatment of Lupus Erythematosus by Repeated Refrigeration with Ethyl Chlorid. M. B. Hartzell 261
A Second Case of Creeping Eruption (Lee). H. W. Stelwagon 269
Executive Session 275
List of Members 279
Index 281

Digitized by Google

Digitized by Google

THE DEVELOPMENTAL DEFECTS OF THE SKIN AND THEIR MALIGNANT GROWTHS.

CHAIRMAN'S ADDRESS BEFORE THE SECTION ON CUTANEOUS MEDICINE AND SURGERY, AT THE FIFTY-FIFTH ANNUAL SESSION OF THE AMERICAN MEDICAL ASSOCIATION, AT ATLANTIC CITY, JUNE 7-10, 1904.

HENRY G. ANTHONY, M.D.

Professor of Skin and Venereal Diseases, Chicago Policlinic.

CHICAGO.

The term nevus, originally used by the laity, has been so thoroughly adopted into medical nomenclature to designate congenital blemishes of the skin that any attempt to change or even modify the meaning of the word can only result in confusion, and yet that is the present tendency in dermatology. Unna[1] says that it is questionable if nevus linearis will permanently maintain its place among the nevi because of the rapid development which it frequently exhibits in extrauterine life.

Postnatal development of a lesion of intrauterine origin is a striking clinical fact, but it is hardly of sufficient importance to form the basis of classification. There are few malformations of the skin which may not grow rapidly or even present themselves clinically for the first time in adult life.

French authorities use the expression nevus tardive to designate the late developing nevus. Though well understood in France, I have known this expression to cause misunderstanding in our country.

1. Unna: Histopathologie, p. 1146.

Digitized by Google

In England, Crocker[2] says the word nevus is applied only to vascular growths, and he designates neoplasms of intrauterine origin by the term "embryogenic growths."

The *Pratique Dermatologique* adopts Brocq's definition, "a nevus is any circumscribed deformity of the skin." Under this definition adenoma sebaceum is a nevus.

In my opinion the word nevus should be used simply as a term of clinical convenience to designate any mark on the skin present at birth or developing shortly after birth regardless of its histologic structure and without any attempt at scientific accuracy.

This is still the accepted use of the word in other branches of medicine and it should continue to be employed in this sense in dermatology.

Any expansion of the meaning of the word in dermatology will cause as much confusion as does the double meaning of the word tubercle.

As a term to designate deep-seated deposits, the word nodule should be employed, and we should use the expressions nodular syphilide and nodular leprosy rather than call these lesions tubercular syphilide and tubercular leprosy.

To avoid all confusion of nomenclature and misuse of the word nevus, it would be advantageous to employ the expression developmental defects of the skin, to designate all abnormal conditions of intrauterine origin which are not due to disease of the fetus.

There are two classes of cases, misplacements and anomalies of development. Under the latter class we would recognize anomalies of hair and nails, of keratinization, of pigmentation, of blood vessels, of fibrous tissue and some other forms.

THE CAUSES OF DEVELOPMENTAL DEFECTS OF THE SKIN.

The causes of defective development are probably multiple. At the present state of our knowledge there are

2. Crocker: Diseases of the Skin, p. 932.

Digitized by Google

two which should be carefully sought for in each and every case that passes our observation: heredity and the toxins of the chronic infectious diseases. "Like begets like." A peculiarity of development existing in one generation of a family is frequently observed in succeeding generations. I have observed three generations of a family in which a tuft of hair like a mane grew over the seventh cervical vertebra with no alteration of the skin developing in each instance at the time of puberty. It was present in the grandfather, in his three sons, and one of the sons having four children, in each of the children.

Peculiarities of development in lower animals may also be observed in succeeding generations. The Holland belted cattle illustrate my meaning. They are a breed of cattle which resemble the Holstein in general build, but differ in the fact that they have a broad black belt extending around the body. This black belt once established, the animals breed true, and it is regularly present in the offspring.

One of the most remarkable examples of the manner in which a developmental defect may become a racial characteristic to be found in the animal kingdom is that observed in Polish chickens, in which a greater part of the brain is an encephalocele contained in a vesicular-like bony protuberance of the skull. Aldroini[3] mentioned these fowl in 1600, at which time the deformity does not appear to have developed into a breed characteristic.

THE TOXINS OF THE CHRONIC INFECTIOUS DISEASES.

Charrin and Gley,[4] wishing to study the effect which the toxins of chronic infectious diseases would have on the offspring when administered to the parent animal, subjected rabbits, both male and female, to the influence of such toxins, and after a variable length of time bred

3. Aldroini: Eulenborg's Real-encyclopædie der Gesammten Heilkunde, vol. xv, p. 451.
4. Charrin and Gley: Cliniques de l'Hôtel Dieu, 1897.

Digitized by Google

the animals, sometimes mating a healthy buck with a doe which had been subjected to toxins, sometimes reversing the mating and again breeding animals both of which had passed under the influence of toxins.

The results were most striking and excited great interest in France, especially among dermatologists.

Barthelmy[5] has tried to show that the toxins of syphilis cause various stigmata such as nevi and all kinds of imperfect development in the third generation.

Since my attention has been directed to this subject I have observed a number of cases in which this theory could be invoked, and I have seen some in which no such explanation could be offered; the subject is worthy of consideration.

THE DISPLACEMENTS.

The developmental defects of the skin which are of greatest importance at the present time are those which are formed by the glandular elements of the skin and the pigmentary mole. These conditions have been more discussed by dermatologists during the past few years than almost any subject of cutaneous medicine.

According to Unna pigmentary moles are cell inclusions. Crocker describes adenoma sebaceum as a congenital overgrowth of an adenomatous character, developing from embryonic remnants in the skin. He has seen them develop in adult life and he finds them not uncommonly in the inmates of idiot asylums.

Hydradenome eruptive is described as a nevus in the *Pratique Dermatologique* and most authors describe benign cystic epithelioma as belonging to this disease. Toeroek[6] says that he formerly shared this opinion, but since studying sections obtained from Brooks' case he has concluded that benign cystic epithelioma should be held separate and apart from hydradenoma.

From a study of slides from Fordyce's case I agree

5. Barthelmy: Annales de Dermatologie et Syphilographie, 1897, p. 885.
6. Toeroek: Mracek's Handbuch der Hautkrankheiten, p. 482.

Digitized by Google

with Toeroek. I see no reason to believe that the growth is derived from the sweat glands. The opinion originally expressed by Fordyce that the cells are derived from the rete I believe to be correct. That there should be any controversy on this subject is due to the fact that hydradenoma may clinically resemble benign cystic epithelioma very closely and that those who have studied hydradenoma microscopically have not had slides from benign cystic epithelioma for comparison.

In my opinion these conditions are one and all of them displaced cells, the displacement occurring in embryonic life, carrying with it different parts of the skin in different cases. In one case the displaced cells are chiefly derived from sebaceous glands and develop into adenoma sebaceum in postnatal life. In another case the displaced cells are mostly sweat gland epithelium which will form hydradenoma eruptive. Benign cystic epithelioma results from the displacement of cells of the rete.

The pigmentary mole, which is the most common of all displacements, contains cells which are of an embryonic type. These conditions are in every way the equivalent of dermoid cyst of the ovary, provided we agree with Marchand that dermoid cyst of the ovary is a displacement. It develops in adult life; it may contain teeth, hair or cholesterin and its walls may be lined with a membrane containing dilated sebaceous glands; one or the other accessory organs of the skin preponderating.

THE PIGMENTARY MOLE.

Clinically this malformation of the skin varies within wide limits, from the simple stain remaining unchanged throughout life, to the mammillated plaque of the covered regions of the body or the hemispherical pedunculated pea-sized tumor of the face often having a growth of a few hairs. As a rule it exhibits a gradual increase in size and frequently a decrease in pigmentation as the years go by.

Histologically they are all of the same structure, con-

Digitized by Google

taining displaced connective tissue, displaced epithelioid cells, and displaced hairs with more or less abnormal pigmentation. The variation in the clinical symptoms is due to the amount of tissue displaced and to the preponderance of one element of displacement over another. A simple stain of the skin contains only a small cluster of epithelioid cells, while a mammillated plaque contains large perpendicular strands of epithelioid cells alternating with strands of coarse connective tissue.

The pigmentation differs widely in different cases; it is like that of the negro, present in the form of fine grains in the deep layers of the rete, but it has an uneven distribution.

THE EPITHELIOID CELLS OF THE PIGMENTARY MOLE.

After ten years of discussion regarding the nature of these cells we may state, that the older opinions that they are the cells of lymphatic channels, endothelial cells, etc., have now few supporters and that it is the opinion of most investigators that they are either embryonic connective tissue cells, as Riehl and Rieche believe, or else they are epithelium cells, as Unna and his followers, who are in the majority, believe.

According to Unna's theory the rete pegs grow downward into the corium about as they do in a wart, and clusters of cells become detached from their ends and undergo a metaplasia by which they lose their prickers and revert to the embryonic type, and furthermore, this cleavage of cells in clusters and metaplasia occurs not only *in embryo,* but may even be seen occurring in infancy. Just as drops of water drip from the point of an icicle so do these clusters of cells become more slowly detached from the ends of the rete pegs.

That clusters of cells actually become detached from the rete pegs he determined by serial sections, and his findings have been substantiated by Gilchrist, Schueber, Abesser and others, while on the other hand Ribbert and

Digitized by Google

Rieche[7] find that no separation occurs and they believe that the peculiar figures of the rete pegs which at first view appear to be clusters of cells detached, undetached and in process of being detached from the rete pegs, are produced by oblique sectioning and by outward pressure. Rieche finds that the rete figures occur in nevi of adult life even in the sixtieth year, and he finds no separation in serial sections.

Abesser,[8] who accepts Unna's theory, also finds them in adult life. I have found them as late as in the fortieth year of life, and I agree with Rieche that no detachment of cells occurs.

Unna has observed these same figures in certain cases of fibroma molluscum and he argues that their presence shows that such cases are really cases of nevus. Whitfield[9] finds them in nevocarcinoma even more frequently than in the nevus.

A microscopic finding is one thing, an interpretation of the finding is another thing, and these two things are to be considered separate. Before any attempt is made to elucidate a microscopic observation, every possibility of diagnosis should be considered and that has not been done in the study of this condition.

Unna's theory depends entirely on the interpretation of the figures of the rete pegs, and as I am convinced that no separation occurs, I maintain that his theory should be discarded.

There is no doubt in my mind that the displacement occurred and was completed in early embryonic life. In other words, the pigmentary mole is to be explained by the Cohnheim theory and not by the Unna theory.

Whether the displaced cells are epithelium or connective tissue can not be determined at the present state of our knowledge. Unna gives the reasons for believing

7. Rieche: Archiv für Dermatologie und Syphilis, vol. lxv, p. 65.
8. Abesser: Virchow's Archiv, 1901, vol clxvi, p. 66.
9. Whitfield: British Journal of Dermatology, 1900, p. 267.

Digitized by Google

that they are epithelium and Rieche the reasons for believing that they are connective tissue.

If Kromayer's[10] theory of desmisphasia is accepted as correct, the question is of little importance, inasmuch as a connective tissue cell may be transformed into an epithelium cell.

THE MALIGNANT GROWTHS WHICH DEVELOP IN DISPLACEMENTS.

Hallopeau and Derier[11] have reported a case of hydradenoma complicated with epithelioma, and Audry has reported a second similar case.

An epithelioma developed in Dyer's case of benign cystic epithelioma and also in White's case. Epithelioma may appear in moles and occasionally a spindle-cell sarcoma, but the tumor of greatest interest which develops in moles is the melanotic small round-cell growth which is now called nevocarcinoma.

The melanotic pigmentation which is present in greater or less amount in these growths is one of their most characteristic features. Clinically melanosis may involve extensive areas of cutaneous surface and be present for a considerable length of time before the tumor develops sufficiently to be recognized. It may spread into healthy tissue surrounding the tumor; it may affect the skin in large plaques at a distance from the tumor, as in Bamberger's case, or involving the lymphatic vessels, it may produce a lymphangitis of a bluish color extending from the neoplasm to adjacent lymphatic glands.

Eve[12] has recently reported an important series of cases which show that melanosis may occur in the skin or visceral organs, or metastatic tumors may develop and on examination lymphatic glands will be found in some part of the body as the first sign of disease and in close proximity to a mole which shows no change.

---

10. Kromayer: Archiv für Dermatologie und Syphilis, vol. lxii, p. 299.
11. Hallopeau-Derier: Pratique Dermatologique, vol. i, p. 292.
12. Eve: Practitioner, 1903, p. 165.

Digitized by Google

It is not uncommon for the disease to start from a mole which shows no symptoms of the disease. The case reported by Hanocque[13] in 1868 as a case of primary

Fig. 1.—(Low power.) Simplest form of nevomelanoma. Epithelioma of the epidermis and nevomelanoma with its accompanying pigment in the derma.

melanosarcoma of the axillary glands was possibly of this category. Melanosis is not always a sign of malig-

13. Hanocque: Bull. de la Société Anat., 1868, p. 233.

Digitized by Google

nancy; it exists normally in the iris and some other parts of the body.

Ullman[14] presented a case of cavernous angiomata of the face before the Vienna Dermatological Society which exhibited black pigmentation. In discussion Kaposi stated that he could not conceive of such tumors being

Fig. 2.—(Low power.) Honey-comb-formed nevomelanoma. The nevomelanoma has invaded the epithelioma, producing the honey-combed appearance. The epithelioma represents the comb, and the nevomelanoma and its accompanying pigmentation represents the honey.

present in the absence of sarcoma, and he would advise that a very thorough search be made for the presence of

14. Ullman: Archiv für Dermatologie und Syphilis, vol. xxxv, p. 197.

Digitized by Google

sarcoma cells. His suggestion was followed with negative result; the patient died of septic pneumonia after being under observation for six years, and a careful post-mortem failed to reveal the presence of sarcoma in any part of the body.

Nervous exhaustion or shock may produce melanotic pigmentation. Bark[15] has reported the case of a woman, 53 years old, who, receiving a severe mental shock caused by the suicide of her daughter, developed generalized melanoderma which lasted two years.

I find this difference between the pigmentation of the nevus and that of the nevocarcinoma; the pigmentation of the nevus is associated with the epithelium of the rete, the hair root or the glandular epithelium, while that of the tumor is associated with the epithelioid cells.

NEVOMELANOMA.

Schalek[16] bases his opinion that the malignant growths which develop in nevi are carcinomatous mostly on a study of the chromatophores which have now lost their importance in determining the character of these growths. They are probably leucocytes transporting the superabundance of pigment which the tissues produce to the lymphatics and blood vessels, thereby causing melanemia and melanuria, which are essential features of the disease.

Ravogli[17] especially emphasizes the alveolar arrangement and the relation between the epithelium cells and the pigment.

Green[18] says that the sarcomatous nature of angiosarcoma which has an alveolar arrangement can not be questioned and that the distribution of the pigment in these tumors is not of such a kind as to indicate that the epithelioid cells were derived from the rete. I agree with Bland Sutton[19] that the alveolar arrangement is

15. Bark: Archiv für Dermatologie und Syphilis, vol. xlv, p. 283.
16. Schalek: Journal of Cutaneous Diseases, 1900, p. 117.
17. Ravogli: Journal of Cutaneous Diseases, 1901, p. 270.
18. Green: Virchow's Archiv, 1893, p. 331.
19. Bland-Sutton: Tumors, Innocent and Malignant, p. 110.

Digitized by Google

simply an exaggeration of the normal arrangement of the nevus.

Waldeyer, whose opinion carries greater weight with it than that of anyone else who has accepted Unna's the-

Fig. 3.—(Low power.) Venereal wart-like form of nevomelanoma. The nevomelanoma, with its accompanying pigmentation has invaded the interspaces of the epithelioma-epithelial pearl.

ory, bases his acceptation on an inspection of Unna's slides without showing that he has studied the effect of outward pressure, and the same criticism may be offered of most of the others who follow Unna.

Digitized by Google

For the material which enabled me to study these tumors I am indebted to Professor Herzog of the Chicago Policlinic, and to Professors Hektoen and Le Count for placing at my disposition the splendid material contained in the laboratory of Rush Medical College.

The *Pratique Dermatologique* says "that the characteristic which distinguishes this tumor from all other cancers is that in the structure of its elements and in the texture of its tissue, it is intermediary between a carcinoma and a sarcoma."

That the tumor is derived from the epithelioid cell of the nevus there can be no doubt. Wherever we find one of these tumors forming in the epithelioid cells of the corium we know that an epithelioma like down growth of the rete may be seen in the immediate vicinity (Fig. 1).

This was the finding in Gilchrist's,[20] Waelsch's and Minne's cases and in all the cases examined by me. The microscopic picture which the growth presents depends on the manner in which these two tumors, developing in close proximity, combine.

Waelsch[21] published his cases to demonstrate the fact that the tumor does invade the epidermis. He is quite correct, but he overlooked the important fact that when it does it pushes the epithelium cells aside. The cells of the tumor never mingle with the cells of the epidermis; one can always distinguish the tumor cells with the accompanying pigmentation from the epithelium cells. In some cases, through the development of the tumor cells in the epidermis, a honeycomb-formed tumor is produced.

As is shown in Fig. 2 the epidermis cells form the comb and the tumor cells with the pigmentation represent the honey. In cases where the epithelium cells are rapidly proliferated and imperfectly formed the growth is like a venereal wart, consisting almost entirely of

20. Gilchrist: Journal of Cutaneous Diseases, 1899, p. 366.
21. Waelsch: Archiv für Dermatologie und Syphilis, vol. xlix, p. 249.

Digitized by Google

scrolls of epithelium cells with small interspaces between the scrolls which contain the tumor cells and their pigment (Fig. 3). In this class of cases what is tumor cell and what is epithelium cell can always be determined.

This fact that we can distinguish the tumor cell from the epithelium cell, and the fact that the tumor cell always pushes the epithelium cell aside, are, in my opinion, important in determining the classification of this tumor.

Where a metastasis occurs to a neighboring lymphatic gland or develops in a visceral organ, it is the tumor cell and its pigmentation and not the epithelioma, which is transported.

Green says that the tumor of the choroid which has always been looked on as sarcoma and the formation of which has always been considered to be connective tissue, corresponds fully in architectural structure with the nevomelanoma.

Le Count (personal communication) states that given a metastatic growth of the skin, one can not determine whether the primary tumor was located in the skin or in the choroid, inasmuch as the same form, size and character of cell, the same pigmentation, and the same alveolar structure is present. The primary tumor showing the same characteristics could be distinguished by anatomic landmarks such as an attached piece of normal skin. Anyone with the necessary material at his disposal may convince himself that this statement is correct.

Gensberg and almost all other oculists believe that the choroid tumor is a sarcoma.

There is no tumor classified to-day as carcinoma which differs from all other forms as much as does this form, The rodent ulcer is a distinct variety of epithelioma until it reaches the terminal stage, when it assumes the general characteristics of all other malignant epithelium neoplasms; not so with nevocarcinoma; it presents

Digitized by Google

special clinical and histologic characteristics from beginning to end.

Birch-Hirschfeld[22] says: "In regard to the clinical features of these tumors we will state that the melanosarcoma, as is well known, shows a high degree of malignancy, which is not due to a tendency to local destruction of the growth, as in carcinoma, neither is it due to toxemia, but rather to the multiple development of metastatic tumors which appear in the terminal stage of the disease. This disposition to the formation of embolic metastasis must be considered the essential basis of the clinical malignancy of the sarcoma."

From what we have said it will be seen that this tumor differs both clinically and in its histopathology from carcinoma. It therefore should not be classified as a carcinoma. It develops in displaced embryonic tissue, which is probably of epithelium origin and it should be classified separate and apart from all other malignant growths and called nevomelanoma.

DISCUSSION.

Dr. John A. Fordyce, New York—Much interest is taken at the present time in the development of malignant growths, and a tendency is displayed to discredit the parasitic theory and attach more weight to the possible embryonic origin of malignant growths. A study of such cases as Dr. Anthony has included in his paper certainly has a tendency to encourage a belief in Cohnheim's theory of the development of these tumors in embryonic rests. Regarding the question of the so-called multiple benign cystic epithelioma, experience has shown us that these cases are not always multiple. We may have single tumors on the face which show the clinical features and the histologic structure of benign epithelioma. Some of the rodent ulcers which develop on the face may persist for years as small pearly tumors, possibly due to some congenital displacement of epithelium. I do not intend to say that in every case of epithelioma or malignant disease of the skin there must be some congenital abnormality. In epithelioma of the lip or tongue, chronic irritation, or the pre-existence of some antecedent affection, like syphilis, is the chief factor in bringing about the disease.

Dr. A. Ravogli, Cincinnati—I have had in my practice several cases of nevocarcinoma. I think four, in the course of

22. Birch-Hirschfeld: Real-encyclopædie der Gesammte Heilkunde, vol. xxi. p. 179.

Digitized by Google

three or four years, have died in consequence of carcinomatous metastasis, showing that nevocarcinoma is a very dangerous and malignant affection. I think we should study carcinoma as we do tuberculosis, and I think we shall see that carcinomas vary according to the tissues which are affected. I believe the resistance of the tissues which are affected has a great deal to do with the nature and the spreading of the epithelioma. We have for instance, a mild case of epithelioma which lasts eight or ten years without causing any trouble; a little limited ulcer or tumor, remaining for years without spreading, and later the process goes deeper and affects the tissues of the skin, which are loose and which allow the introduction of the cancerous elements into the system, and then we have the formation of these nodules, the secondary carcinoma, and then the metastases in the skin. I think that from the beginning a superficial epithelioma is not at all different from carcinoma; the only difference lies in the place where the carcinoma is situated and in the resistance of the tissues which isolate it and keep it from spreading. In the same way we have lupus vulgaris remaining for years without producing an infection. But if these nodules go deep into the subcutaneous tissue or lymphatic vessels, then we have the formation of a tubercular gumma, etc. I believe we have the same thing in carcinoma; the tissues of the nevi are very loose and of less resistance, and I believe that this peculiar looseness, this non-resistance of the tissues, has a great deal to do with the extension of the carcinomatous process.

Dr. W. T. Corlett, Ohio—To me the word nevus is more especially associated with derangements of the circulation, and when we apply nevus to abnormalities of development other than vascular, I think it becomes confusing. I am in accord with Crocker, who advocates employing the qualifying term, "embryogenic," when there is reason to believe the defects take their origin in fetal life. I have not seen that the children of syphilitics, or those one or two generations removed from a syphilitic subject, show any more tendency to the development of abnormalities of the skin than those without such antecedents. There is a popular belief among the laity that melanotic sarcoma frequently develops from pigmented moles, and from my clinical experience I think there are strong grounds for believing this to be true, in a large number of cases. One of the cases referred to by Dr. Ravogli, I think, also came under my observation. This woman had a pigmented congenital mole over the sternum. When she was about 25, this gave rise to a melanotic sarcoma, with metastasis, and death. This, in my experience, has been fairly common. I do not, however, wish to be understood as saying that all pigmented moles become malignant.

Dr. A. Ravogli—Of these four cases of nevocarcinoma, two were pigmented and two were entirely unpigmented, and the

Digitized by Google

two that were entirely unpigmented died in the same way in two or three years.

Dr. J. A. Fordyce—It might be well to bear in mind that nearly every one has a mole, but the occurrence of malignant growths is extremely rare.

Dr. M. L. Heidingsfeld, Cincinnati—The lay term nevus includes so many widely dissociated clinical and histologic conditions, angiomata, pigmentations, teratomata, telangiectases, albinism, hirsuties, defects, etc., that I think it unfortunate that it should have ever attained scientific value. I believe that the chairman is taking a retrogressive step, however, in limiting the scope of the term merely to those conditions present at birth. That position was formerly taken by many authors, but to-day the most conservative, Besnier not excepted, include anomalies which develop, not only days and months, but even years after birth. Inasmuch as it must be conceded that many of these anomalies develop from tissues which to all appearances, and as far as positive knowledge permit us to judge, are perfectly normal for a considerable period of time, we can not afford to become too dogmatic in our study of causation and base the etiology of every case on the purely conjectural assumption of misplaced embryonic remains. It is probable that some of these anomalous growths spring from normal glands, follicles and tissues, incited to new growth and development by causes and influences equally obscure as misplaced embryonic remains.

Dr. D. W. Montgomery, San Francisco—I think that the slate-colored nevi are more likely to give rise to malignant growths than the buff-colored ones. I do not know whether that is a feeling simply or whether it is really a fact, but I have always looked on the buff-colored ones as practically innocent. I remember the case of a young girl who had a slate-colored nevus on one side of the great toe. She was being operated on when I first saw this nevus. The surgeon referred to it and said he would like to cut it out also, but he had not gotten permission to do so. Shortly afterward this nevus began to grow irritable and to thicken and leak. The surgeon then burned it down well with the thermocautery, and it healed with a good cicatrix. Soon after the girl consulted me for enlargement of lymphatic nodules in the groin, on the same side as the affected toe. I gave an absolutely bad prognosis, and could not advise operation. She died of very widespread metastasis. These metastases were sarcomatous, some of them inky black, some half black and half white, and some were wholly white, so that the metastasis did not follow exactly, as regards pigmentation, the original growth.

Dr. H. G. Anthony—I have not a doubt, in answer to Dr. Fordyce, that single tumors may occur in benign cystic epithelioma. Furthermore, I believe there are some tumors of trau-

Digitized by Google

matic origin which closely resemble these various malformations of the skin. In a certain number of cases these malignant tumors will develop in places in which there is no evidence of there having been previously a mole; but if you cut the tumor out and examine it, you will often find it has the exact histopathology of the mole. There is a decided difference between a carcinomatous metastasis and metastasis from one of these growths. A characteristic of the carcinomatous metastasis is that it is a transportation of the original tumor to the site of the metastatic growth. If a patient has a primary carcinoma of the stomach and secondary carcinoma of the liver, the secondary retains the character of the primary tumor, and you have an equivalent of a part of the stomach growing on the liver, so that by an examination of the metastatic growth you can sometimes determine in what part of the body it arose. These tumors have exactly the appearance and character of the epithelial cells of the nevus. I have examined metastatic growths in these tumors in all parts of the body, and always found the same cell present.

In regard to Dr. Corlett's statement that the word nevus should be limited to designate vascular growths, I would say that in this country it has never been used in that way. The surgeon and general practitioner use the term for any kind of growth that is present at the time of birth, and if you use it in any other way you will cause confusion. If you speak of a growth of the skin which develops at the time of puberty, and many of these do—benign cystic epithelioma and fibroma molluscum frequently do—they ask, how is it possible that a nevus should appear for the first time in adult life? Because of that objection I use the term developmental defect of the skin. If you use that and omit the word nevus everyone will comprehend your meaning; that is why I want to popularize this expression. In regard to anomalies of development being due to the toxins of infectious diseases, such as leprosy, syphilis and tuberculosis, I am not prepared to pass an absolute judgment on it; I simply hold it out as a suggestion, as one of the things which should be considered. In the majority of instances where dermatologists come in contact with malformations of the skin they make no effort to assign a cause. My position is that we should try our best to see if we can not assign a cause, and those two possibilities I have spoken of should be considered. Eulenberg's "Real Encyclopädie der Gesammte Heilkunde" says that it is settled that syphilis may cause defects in development. In regard to the statement that melanoma from a nevus is common, I do not think it is. If you will examine patients who come into the dispensary for various diseases you will be surprised to note that the person who has not a nevus on some part of the body is exceptional. Of the cases I have gone over since I had this subject in mind

Digitized by Google

90 per cent. had nevi. So a malignant growth developing on one of these nevi is exceptional. As to the color Dr. Montgomery has mentioned, I will state that it is a rule where metastatic growths occur from nevi the different growths differ one from another within wide limits. Without having my attention previously called to the slate-colored nevi, which are more apt to take on malignancy than others, I regard it as incidental. There is one thing that I believe influences to a certain degree the color of these nevi, and that is outward pressure. The outward pressure of tumors seated in the deep skin very frequently will produce atrophy of the epidermis as they press outward, and the pigment will decrease. So that may be an element in producing the color, and when the tumor begins to grow there is a diminution of the color.

Dr. Heidingsfeld's statement that some of these anomalous growths spring from normal glands and tissues is not correct, because, first, they appear in succeeding generations; second, they are usually present at birth; third, they have a systematic arrangement. I agree that it is unfortunate that the word nevus should ever have obtained scientific value and that is the reason I wish to drop it as a scientific term and substitute the expression "developmental defect"; the meaning of which can not be misunderstood and which is not a step backward.

Digitized by Google

FALLING OF THE HAIR.

R. A. McDONNELL, M.D.
NEW HAVEN, CONN.

One of the least acceptable of the accompaniments of civilization is premature baldness. The fact is patent to all that as races advance in the arts and avail themselves of the refinements of civilized life, premature loss of hair is more and more in evidence. It is true that this is no hindrance to an active and useful life, but, nevertheless, it is a source of great annoyance to many who are afflicted.

The whole subject of the growth of hair is so little understood that it has been a lucrative field for the charlatan from time immemorial. Some of the greatest successes among patent medicines are the so-called hair tonics. We, as medical men, know that no single remedy can be used successfully in all cases, but many of us, I imagine, approach a case of alopecia with a vague sense of incompetency. True, we roughly differentiate the oily scalps and the dry—those affected by local diseases and those the result of general conditions—but even the best of us feel that we know none too much about the subject. It seems, therefore, worth our while to consider in what ways modern life is responsible for the increasing loss of hair, and in how far such causes may be removed or guarded against.

The most common cause of premature loss of hair is, without doubt, seborrhea and the resulting eczema. Seborrhea has been demonstrated to be a germ disease, caused by Unna's flask-shaped bacillus. Therefore, it is

Digitized by Google

a communicable disease. When we consider the number of ways in which it may be spread we are appalled and reduced to wonder that the disease is not even more common than it is. Barber shops are probably chiefly at fault. It is only very recently that such places have been brought under the control of state boards of health, and even now they are often conducted in a way which is far from sanitary. In some states barbers are required to cleanse brushes and combs once in twenty-four hours, but while such provision is totally inadequate to prevent the conveyance of diseases from one customer to the next, it is a step in the right direction. The only measure which will effectually prevent transmission of the germs producing seborrhea is a law compelling the barber to provide a sufficient number of brushes so that, no matter how many customers he may have, it will be possible for him to disinfect each brush and comb before it is used a second time.

Barber shops, however, are only one medium for the transmission of this disease. The head-rests of dentists' and physicians' chairs, the hat-pegs at clubs, the backs of railroad seats, and the closer intercourse of members of the family are all possible means of contagion. It is true that this disease may be cured even after it has got well started, but it requires so great attention to detail and persistence in treatment for so long a period that, as a matter of fact, it rarely is cured.

Another common cause of premature alopecia is the practice of literary people, and of those who use artificial lights for other than literary purposes, of overheating the scalp by allowing the heat rays from their lights to be reflected on their scalps, a procedure which results in drying out the oil of the hair and interfering with its nourishment.

In connection with the subject of illumination, it is now a well-known fact that exposure to the x-ray will cause lanugo hairs and, if long continued, those of a sturdier growth to fall out. Such hairs, it is true, will

Digitized by Google

be partially replaced by others, but the experience of many has shown that they do not come back as thick as before, and continued exposure may result in a very noticeable thinning of the hair. Now, the writer thinks he has noticed that the light from common incandescent electric-burners produces a thinning of the hair in some such mysterious fashion, entirely apart from its heating effect. For instance, he believes that those employed in stores lighted in this way are more generally bald, or partially so, than those employed in similar stores lighted in other ways.

Hair dyes and bleaches are certainly responsible for no small amount of baldness. It is probable that no one of them may be used for any considerable length of time without resulting in damage to the hair. I think we do not realize how extensively these preparations are used. Many of the so-called hair tonics contain lead salts, and are, therefore, merely dyes for the hair.

The practice of saturating the hair with water frequently is a damaging one. The hair is allowed to become dry by evaporation after this procedure, and is rendered stiff and brittle thereby. On the other hand, many people do not apply water often enough to the scalp. There is no other part of the body which is allowed by cleanly people to remain unwashed for more than a week, and yet there is no part of the body which furnishes so good a lodgment for dust, germs, rancid perspiration and filth of all kinds as the scalp. We are told by some professional hair dressers that the scalp should be brushed clean every so often, but it is inconceivable that it ever could be brushed clean. I suppose that everyone of us is astonished from time to time by the statement of some dainty-looking woman that she rarely washes her hair more than once in a month or two. I believe that the shampoo should be taken often enough to keep the scalp clean. If the patient be a man who travels much on the railroad, or rides in automobiles, or one who works in dusty places, he may have

Digitized by Google

to wash his head every day or two in order to keep it clean; and, on the other hand, if the patient be a woman who rarely goes out of the house and is not exposed to dust, a washing once in two weeks may suffice, but I conceive that a fair average would be once a week.

All that we can expect to accomplish in the way of a shampoo is cleansing, so that I can not see the advantage of any special shampoo. Soap and water, well rinsed off after they have served their purpose of dissolving oil and dirt, are sufficient. True, some soaps are better for this purpose than others. Castile soap for white or gray hair, and tar soap for dark hair are as good as anything that can be used. After the shampoo I think it is important that the hair should be rapidly and thoroughly dried. This may be accomplished by using two or three hot towels.

Heredity plays an important rôle in the subject we are considering, and yet a person whose predisposition is strong for early baldness may stave off the inevitable for a long time by proper attention to the rules of hygiene here laid down.

The danger of contagion in barber shops has already been spoken of, but there is another danger which is often overlooked. It arises from the practice of allowing a barber to put various kinds of his preparations on the scalp. Many of the egg shampoos and cacao butter shampoos will become rancid if kept up for any length of time, and when rancid they can not fail to act as irritants. Stiff hats by their pressure interfere undoubtedly with the circulation of the scalp and conduce to baldness. This merely needs to be mentioned, as it is already well known.

There are several curious things about the hair which are not easily explained. One is the commonly observed thickness of the hair of consumptives. Why any such wasting debilitating disease should result in increased growth of hair is hard to understand. On the other hand, many febrile and wasting diseases, such as typhoid

Digitized by Google

fever and pneumonia, cause the hair to fall out. It is another curious thing that psoriasis, with its thick accumulation of scales pressing as they must on the hair roots, often causes but little loss of hair, even when persistent for a long time, whereas, seborrhea with its much smaller amount of scaling will usually cause the hair to begin to fall early.

Now, we might tabulate the causes of the loss of hair with an attempt to arrange them in the order of their frequency about as follows:

1. Dandruff.
   - Seborrhea sicca.
   - Eczema seborrhoicum.
   - Tricophytosis.
   - Favus.
   - Psoriasis.
   - Eczema squamosum.
   - Lupus erythematosus.
2. Heredity.
3. Fevers.
4. Improper hygiene.
5. Syphilis.
6. Alopecia areata.
7. Ulceration of follicles.
   - Traumata.
   - Sycosis.
   - Folliculitis decalvans.
8. Stretching of scalp by tumors (wens.)
9. Myxedema.
10. Chronic metallic poisoning (mercury, etc.)
11. Some rare diseases (pityriasis rubra.)

In the foregoing scheme dandruff is assigned the post of honor as being the most fertile source of alopecia, and when it is considered how many pathologic conditions are called by this name, it is small wonder that it should stand at the head. But even if we exclude from this title all diseases but seborrhea sicca and eczema seborrhoicum, dandruff would still be far and away the most common cause, and it is with this limitation that the term dandruff is henceforth used.

An easy deduction, then, is that every person who suffers from dandruff should get rid of it, if he wishes to preserve his hair as long as possible. This may be accomplished in various ways, but the most satisfactory method known to the writer is as follows: The dandruff

Digitized by Google

is at first loosened by vigorous brushing with a rather stiff brush, and then a shampoo is ordered, for example, quinorcin soap.

After the scalp has been thoroughly cleansed by the shampoo, the following formula is to be used:

℞.	Acidi salicylici	1	5
	Sulphuris præcipitati	2	
	Unguenti aquæ rosæ	25	
M.			

The patient is directed to part the hair, and then to rub in a small portion of the ointment along the part, working it well into the scalp at the roots of the hairs. Then another part is made parallel to the first, and more ointment rubbed in. Thus a series of first longitudinal and then transverse parts are made, until the whole scalp has been well anointed. Done in this way, it is not necessary to smear up the whole shaft of the hair, but only to reach the hair roots and the sebaceous glands, where the trouble is located. This process is thoroughly performed for six successive nights, and the seventh night another shampoo is taken. The eighth night the inunctions are commenced again, and this program is continued for six weeks. In almost every case the production of dandruff is checked completely after six weeks' treatment, and the hair, which may have been falling out rapidly before, begins to take firmer root. To be sure, many hairs which are on the point of falling when treatment is begun, will fall anyway, and it may even seem for a time as if the treatment were increasing the hairfall, on account of the mechanical dislodgment of such hairs, but this need never alarm one.

After six weeks of such treatment, the shampoo may be taken less frequently—say once in a fortnight. Yet when one thinks of it there seems every reason why the scalp, which offers such an easy lodgment for dust and dirt of all kinds, and which itself is casting off effete products surely as rapidly as the rest of the body, should be washed at least as often as the other parts of the body.

Digitized by Google

By such treatment, then, we have removed all dandruff, and by the reducing action of the sulphur on the sebaceous glands, have checked its further production for a time. But seborrhea is ultimately due to some one or more of a variety of causes, as follows:

- **Overproduction of sebum is due.**
  - **1. To the skin itself.**
    - **a. Natural tendency.**
    - **b. Poor nutrition.**
      - **Anemia.**
      - **Chlorosis.**
      - **Struma.**
    - **c. Hypernutrition (puberty.)**
  - **2. To reflex action.**
    - **a. From genito-urinary organs.**
    - **b. From digestive tract.**
      - **Constipation.**
      - **Indigestion.**
      - **Toxins.**
    - **c. From nose.**
    - **d. From brain (mental troubles.)**

It need only be remarked here, that the most complete success in treatment can only be attained by reaching and removing the ultimate cause of the seborrhea, and that by far the most frequent of such causes is constipation, or some other gastrointestinal derangement.

Next to dandruff, perhaps the most common cause of early loss of hair is heredity. In some families all the male members, or all who resemble one particular ancestor, lose their hair early. Dark-haired families and races, as a rule, become bald earlier than those with light hair. At first thought, it would seem as though nothing could be done to prevent premature baldness when heredity is the cause, but this is a mistake. Careful hygiene of the scalp (which will be considered later) will often counterbalance hereditary predisposition for a number of years, and even after the hair has actually begun to fall, proper stimulation will, to a certain extent, and for a limited time, often restore to the hair its pristine thickness and strength. Any of the rubefacients may be prescribed for this purpose for daily use, such as croton oil, 1½ per cent.; tincture of cantharides, 15 per cent.; oil of cinnamon, 40 per cent.; tincture of capsicum, 15 per cent.; oil of mustard, 1 per cent., or any one of a dozen others. Tincture of capsicum

Digitized by Google

is one of the best, and for a routine prescription the following has served me well:

℞.	Resorcini	5
	Tincturæ capsici	15
	Olei ricini	10
	Alcoholis q. s. ad	100
	Olei Rosæ q. s.	

M.

It is recommended that the stimulant be changed from time to time, so as not to rely on any one to the exclusion of the others. Jaborandi, oxygen gas, quinin and other agents have enjoyed a great reputation as hair producers for a time, and have then taken their proper position as aids, but not specifics, in restoring the hair.

It is a well-known fact that after many fevers, especially those accompanied by great depression, such as pneumonia, typhoid, puerperal or scarlet fever, the hair is very liable to fall out during convalescence. This is brought about in a variety of ways: In scarlatina the hair papilla shares in the general desquamation; in typhoid and the other fevers, the baldness may be the result either of the excessive seborrhea, which often accompanies these diseases, or may be caused by the general lowering of nutrition of the body. Unless the hair-fall be accompanied by considerable dandruff (in which case the above-recommended treatment should be vigorously employed), the ordinary hygiene of the scalp will result in a restoration of the hair in most cases, but the employment of moderate local stimulation, with the use of good general tonics, will hasten this end. It seems to me unwise to cut the hair of ladies short in these cases, because the baldness is practically never complete, and a certain proportion of the hairs will retain firm root. These may be augmented by a switch made of the hair which has fallen out, until the new hairs shall have grown long enough to do up well. In this way all of that oftentimes most annoying short-hair period is avoided.

When improper hygiene is given as a frequent cause

Digitized by Google

of falling of the hair, it is with a due appreciation of the fact that savage tribes which devote little or no time to the care of the scalp are often characterized by a most bushy growth of hair, even to advanced old age. This means only that they have made up in some directions for their lack of care in others. An active life in the open air, conducive to a proper performance of all functions and to a general vigor of the system, as well as free ventilation for the scalp and an avoidance of pernicious modes of dressing the hair, are some of the reasons why a good head of hair is preserved under such conditions.

Fashion dictates that the hair of men should be kept cut pretty short, and of women never cut at all. Probably a mean between these two ways (*in medio tutissimus ibis*) would be best—say about as long as a football player wears his; for women's hair very often becomes frayed out and ragged at the ends, and men's hair is not allowed to grow long enough to serve its purpose as a protector against changes of temperature. The farmer, musician and artist decline to be governed by fashion in this respect, and as classes, have generally well-preserved hair.

The advice has been given to part the hair for a time on one side and then on the other, the idea being that if the part is invariably made in one place it tends to grow so wide before long as to constitute true baldness. This must be very rarely the case, for most individuals have their hair parted on one side from childhood to old age, and yet baldness is almost always symmetrical on the two sides. Women should avoid, in dressing the hair, any arrangement which causes constant tugging on any of the hair roots. In other words, it should be done up rather loosely. If this necessitates more frequent attention in order to keep it looking neat, so much the better for the hair.

Syphilis is such a well-known cause of alopecia that many men, on applying for relief from falling of the

Digitized by Google

hair, hasten to assure us that they have never had any private disease. This assurance is unnecessary, as the syphilitic alopecia is generally very characteristic. The hair looks as if it had been nibbled off here and there, leaving tufts of normal length between the bald spots. These occur on all parts of the scalp alike, differing in this respect from other alopecias, and what is still more characteristic, the eyebrows often share in the nibbled appearance. This kind of alopecia is not permanent, but may last for months. Mercurial treatment internally, and ammoniated mercury ointment rubbed in to the scalp every night, will shorten the period greatly. The head should be shampooed at least once a week during this treatment. Destructive syphilitic lesions of the scalp sometimes produce patches of baldness which, in this case, is of course irremediable.

As for the other causes of premature loss of hair, they are so plainly diagnosed, and the prognosis and indications for treatment are so evident, that they are introduced here merely for the sake of completeness, and will not be further discussed.

In conclusion, it may be stated that the object of this paper has been to call attention to the great variety of causes which may produce falling of the hair, and to show that no treatment is liable to be successful unless based on a proper analysis of the case.

DISCUSSION.

Dr. Ludwig Weiss, New York City—A physician who had infected himself while operating, and also had a long illness with the resultant general infection, suffered after recovery with general absolute alopecia, but he regained his hair within two years. That seborrhea is an incurable disease, as Unna believes, is true, but it is incurable in a minor degree, fortunately. If it were really as it is regarded theoretically we would see a much larger number of baldheads than we now do in assemblies. Barbers are the main cause of the dissemination of baldness and other parasitic skin diseases. Pennsylvania has done pioneer work in this respect. The state of New York and the city of New York have issued regulations to barbers which are, however, as far as I know, mostly a dead

Digitized by Google

letter. It would be easier for each individual to have his own outfit, his own brush, and not depend even on the brushes which have been disinfected by the barber. As has been stated here, seborrhea causes more alopecia than psoriasis. I think that is explained in this way: The sebaceous glands, as we know, serve to grease the hair within the follicles, while the lubrication of the skin is dependent mostly on the ~~color~~ glands. oil In psoriasis there is more hyperkeratosis present, which, however, does not extend down into the follicle, therefore the hair root is not checked, and this practically explains why in a severe sickness the hair does not fall out as in seborrhea. I have noticed that when an extracted hair bulb presents a dry, black appearance then another new growth can not be expected. I have not ascertained whether or not this is a pigmentosis of the hair bulb, but it seems to me a necrosis of the hair bulb due to the bacilli invading the hair root.

Dr. J. B. Kessler, Iowa City, Iowa—I do not think any dermatologist has as much trouble in caring for any other class of cases as he does with seborrhea or baldness. In almost any medical class, of forty or fifty, before they are through with their senior year one-fourth will apply to the dermatologist for treatment for this trouble, but I think as we progress we will have fewer people with baldheads. Why? Because it has only been in recent years that dermatology has been taught in our medical schools to any extent, and particularly where the students have been required to pass an examination on the subject. The result has been that most students, crowded for time in the last few months of their senior year, let go of what is called the superficialities and take the so-called "full chairs," and they go out to practice internal medicine or surgery, the vast majority not knowing anything about treating seborrhea or diseases of the scalp. So far as hereditary alopecia is concerned, I think it is a difficult question to determine. You ask a patient if his father or his grandfather was bald, and he may say yes, or supposing he says no, that is no argument that the father or grandfather did not have seborrhea. It is very hard for a son to remember or for his father to tell him whether he had disease of the scalp. He simply remembers he was not bald, but that is no argument that he did not have seborrhea sicca. It is very difficult to determine whether an old hereditary baldness played any part in a recent case of seborrhea. In reference to cleansing the scalp, as mentioned in the paper, it has always been a question with me whether mental work had not a great deal to do with hereditary baldness. As you are aware, there are in each of your respective towns or cities coal haulers, for instance, or people who do that kind of work, whose scalps I do not believe have been cleansed from the time their mothers washed them until they die, who have an abundance

Digitized by Google

of hair, baldness being the great exception. This makes me believe that there is something in mental strain, causing congestion and pressure on the hair bulbs. This, in my opinion, has something to do with premature falling of the hair.

Dr. E. L. Cocks, New York City—I have half a dozen cases at the hospital with complete baldness due to *x*-ray treatment. The first was a case of alopecia areata and the *x*-ray was used to help it, how I do not know. The result was general alopecia. The second case was psoriasis. The *x*-ray removed the psoriasis and also the hairs. This was a year ago and the hairs have just commenced to reappear. The third case was that of a young man, aged 21, an epileptic. All other methods of treatment having failed to diminish the number of attacks, the *x*-rays were applied to the crown of the head. A few days after the third application he noticed that the hair was coming out in bunches. I saw him six months later, at which time there was complete alopecia. At the present time there is no sign of the hair returning. He has placed the case in the hands of his lawyer and I hope ere it comes to trial a new crop of hair may adorn his head for his own glorification and that of the *x*-ray therapeutist. Some say that where hairs come out they will come in as before, but that has not been my experience. The fourth case was syphilitic alopecia, and a mistake was made in the diagnosis, the physician thinking it was alopecia, but not due to syphilis. The result was the same. I think we ought to be more particular in giving instructions to the patient. We tell them to take this or the other ointment and use it, but in very few cases is it used as it should be. In order to treat the scalp properly we need a retinue of nurses, and unless we do treat such cases properly they will drift into the hands of the charlatans, and if they do I feel that we have ourselves to blame for it.

Dr. A. Ravogli, Cincinnati—Seborrhea is one of the most effective factors in the production of alopecia, especially seborrhea sicca, when masses of scales containing a fatty substance are formed, covering nearly the entire scalp. In such cases there is great loss of hair. Sometimes we have a seborrhea that is scarcely perceptible, a very mild case, but it is often more dangerous because the patient does not take any care and then the hair begins to fall, and when the hairs have once fallen it is difficult to do any good. Another point: Sometimes we see patients who have never had real seborrhea, only a mild seborrhea oleosa. The scalp is usually clean, and yet they are losing their hair. I have found that these are the people who, on account of their business, usually wear hats continually, and I believe lack of circulation and the moisture which results from constantly wearing the hat has a great deal to do with the production of alopecia. In the treatment I have already pointed out that the use of formalin, a 2 per cent. solution in

Digitized by Google

alcohol or eau de cologne, has given me good results on account of its antiparasitic properties, and sometimes also its stimulating effect on the circulation of the scalp.

DR. R. A. MCDONNELL—A number of cases of alopecia due to exposure to the x-ray have come to my notice. In some cases where patches have been produced there was isolation of parts that ought to be isolated, but loss of hair was brought about, over exposed parts, and in those cases, so far as I have observed, there has been no recurrence amounting to anything. I think it is stated by Bulkley and others with experience that the hairs do not come back as strong or in as great numbers as before. So far as the use of lotions to cure seborrhea is concerned, it has seemed to me that you can not get results. An aqueous solution will pass over the seborrhea like water from a duck's back. Formalin in alcohol might dissolve off the outer layer of the sebum but would not go where it is needed. It seems to me it needs something greasy or oily that will mix with the sebum and thus reach the sebaceous glands.

Digitized by Google

RADIUM AND ITS THERAPEUTIC POSSIBILITIES.

WM. ALLEN PUSEY, A.M., M.D.
Professor of Dermatology in the University of Illinois.
CHICAGO.

There is at the present time very general interest in the question of the therapeutic use of radium. It may also be added that there is very hazy knowledge as to what has actually been done with it. I have, therefore, thought that it would be worth while to consider the subject now in so far as is possible with the facts which are before us. Let me say at the outset that I have made no attempt to review all of the literature on this subject. I have only attempted to consider such authentic literature as seemed to me to have some bearing on the problem which I have undertaken to consider, viz., the therapeutic possibilities of radium. While the public press is teeming with vague and sensational accounts of the use of radium in disease, actual tangible facts are surprisingly few in the authentic literature of the subject. There does, however, seem to be enough data at command to warrant one in hazarding a pretty definite answer to the problem under consideration.

PROPERTIES OF RADIUM.

Radium is an element which belongs in the group of alkaline earths along with barium, calcium and strontium. As all the world knows, it was discovered by M. and Mme. Curie. Its elementary character was determined by spectrum analysis by M. Demarçay, who found that it gave a definite spectrum. Its atomic weight, as

Digitized by Google

determined by the Curies, is about 225. Its atomic weight, therefore, is greater than that of any other known elements except thorium (231) and uranium (239). It is not known in the metallic state. It is obtained usually in the form of the chlorid or bromid of radium, and in the impure salts it is combined chiefly with barium chlorid or bromid. As suggested by the Curies, the activity of radium is expressed in units, the radioactivity of uranium being taken as the unit of measure. The activity of pure radium bromid is of 1,500,000 to 1,800,000 units.

The therapeutic interest in radium is dependent on the fact that it is an apparently spontaneous source of energy, and that some of this energy produces changes in living tissues. In any consideration of the therapeutic possibilities of radium, therefore, the properties of its radiations must have attention. These properties are the more interesting because they are peculiar to the group of substances of which radium is the most powerful and the type.

Radium gives off three kinds of rays: α rays, β rays, and γ rays.

THE α RAYS.

The α rays are believed to be a stream of positively charged particles of matter of about twice the size of the hydrogen atom. The amount of energy and the mass of these rays is enormously greater than those of the β rays and γ rays. The α rays have a positive electric charge and are deflected by the magnet. The velocity with which they are projected is approximately 20,000 miles per second, much less than that of the other rays, and their penetrating power is very slight. The α rays are a form of radiation new to us.

THE β RAYS.

The β rays consist of a stream of negatively charged particles (electrons) of about 1/1,000 the size of the hydrogen atom. They are deflected by the magnet, but owing to the difference in their electric charge they are

Digitized by Google

deflected in the opposite direction from the α rays. They are projected at approximately the velocity of light. They correspond exactly in all their characteristics to the cathode rays of Crookes, and there is every reason to believe that the two are identical in character. When they strike a solid in their path, in all probability they generate x-rays.

THE γ RAYS.

The γ rays differ from either of the others in that they are apparently vibrations of the ether without mass. They travel with enormous velocity, and, like x-rays, are not deflected by the magnet. In their physical characteristics, so far as determined, they are identical with the x-rays from a hard tube.

Ninety-nine per cent. of the energy in radium radiations is found in the α rays, and 1 per cent. only in the β and γ rays. The amount of energy in the β rays, moreover, is much greater than that of the γ rays, perhaps ten times as great—Williams estimates it as being fifteen times as great—so that in the γ rays there is probably not more than 1-10 per cent. of the entire energy represented in radium radiations.

The α rays have very slight if any actinic properties. The β and γ rays are highly actinic, and this is of particular interest in our consideration, because these actinic properties are probably solely responsible for the effects on living tissues which are produced by radium. The β rays and the γ rays, like x-rays, affect the molecular structure of sensitive silver salts in a manner indistinguishable from that of light, and they produce changes in tissue cells analogous to those produced by x-rays.

Radium radiations, further, excite phosphorescence and fluorescence in certain substances, these substances being those in which similar phenomena are excited by light and by x-rays. They cause ionization of gases and thus render them conductors of electricity, so that electrified bodies in their presence are discharged as

Digitized by Google

shown by the discharge of the electroscope in the air in the presence of radium. They all penetrate to a greater or less extent solid substances, but in this respect they differ enormously, the penetration of the γ rays being approximately 10,000 times as great as that of the α rays and 100 times as great as that of the β rays. Their relative penetration, according to Rutherford, is as follows:

α rays are cut down to one-half value in passing through a sheet of aluminum .0005 cm. thick.

β rays are cut down to one-half value in passing through a sheet of aluminum .05 cm. thick.

γ rays are cut down to one-half value in passing through a sheet of aluminum 8. cm. thick.

According to Williams, β rays are not effective on tissues at a greater depth than one-half inch, while γ rays from pure radium will pass entirely through the human body. The penetration of α rays is so slight that they will not pass through the glass tube or the thin sheet of mica which form the usual containers for radium.

In addition, radium gives off what Rutherford has called an emanation, which is capable of inducing radioactivity in other substances. This emanation is in the nature of a luminous gas. It can be confined within the walls of a closed receptacle, and it is condensed by intense cold—150 C.

Radium also gives off heat. Pure radium maintains its temperature at about 1½ C. above the surrounding atmosphere; it emits heat at the rate of about 100 calorics per gram per hour.

Finally, radium apparently gives off the recently discovered gas, helium.

Some of these properties have no interest for us in a consideration of the therapeutic possibilities of radium. For example, the facts that radium gives off heat and perhaps the gas helium, the most inert substance known, are of no importance to us, nor is the fact that it is a spontaneous source of electric energy; we already have

Digitized by Google

satisfactory methods of producing heat and electricity, and so far as we know we do not need helium.

The interest which attaches to it pertains to the properties of the rays which it gives off and to its emanation. The gaseous emanation from radium does not come into consideration in the clinical experiments which have thus far been made, for the reason that the radium in these experiments has been in closed containers, which prevent the escape of the emanation. The fact, however, that the emanation from radium produces radioactivity in other substances has been used as a basis for the attempt to render substances radioactive, and then to utilize this radioactivity as a therapeutic agent. No facts as to the value of this highly ingenious application of radioactivity exist, and it is not probable that the small quantity of radioactive energy that can be thus imparted will prove of any definite value in therapeutics. I believe this suggestion will prove to be only a bizarre idea. Shoddy has suggested the inhalation of this emanation in the treatment of diseases of the respiratory tract. Nothing definite has been determined along these lines.

Of the three kinds of rays from radium the therapeutic interest attaches to β rays and γ rays. The penetration of the α rays is so slight that they do not influence the tissues below the most superficial cells, and in all the clinical experiments which have been made with radium thus far the effect of the α rays must be thrown out of consideration for the reason that they do not penetrate the walls of the glass and mica containers in which the radium has been held. The β rays, which correspond to the cathode stream, have relatively a slight penetration and are absorbed by the first half-inch of the tissues. The γ rays alone penetrate deeply into the tissues. Thus the effect of the β rays will be obtained only in superficial tissues, while the γ rays can penetrate all of the tissues, and accordingly produce more or less effect on them. As very few of the γ rays are absorbed

Digitized by Google

by the skin, and about all of the β rays are absorbed by it, there is no reason to doubt that the effects upon the tissues which have thus far been observed, including the necrotic burns, are the result of the β rays. In addition, according to Williams, the quantity of β rays given off from radium is fifteen times as great as that of γ rays, and this relative preponderance of β rays still further influences the relative importance of these rays in the production of the effects on tissues. Indeed, the quantity of energy obtainable in the γ rays from any mass of radium preparations now in existence is so small that it would seem that any appreciable effect on tissues from the γ rays is impossible. For example, the quantity of energy represented by the γ rays from 100 milligrams of pure radium bromid is almost infinitesimal in comparison with the quantity of energy in the x-rays from a very hard tube, and yet we all know how the tissues will stand the bombardment of the highly penetrating x-rays from a very hard tube. Leaving out of consideration all other facts except the relative quantity of energy represented in the β and γ rays, if we wish to get a reaction in the tissues from γ rays an exposure must be given about fifteen times as long as that necessary to produce a reaction by the use of the β and γ rays combined.

A consideration of the foregoing properties of the different forms of energy given off by radium seems to indicate that in their actinic properties, and in their effect on living tissues we have to do with agents strikingly similar to x-rays. Now, what do the histologic and clinical facts thus far obtainable show?

GROSS EFFECTS ON LIVING TISSUES.

When the skin is exposed to radium there first appears an erythema; if the process goes beyond erythema, there develops a livid dermatitis; if it progresses further, vesicles develop upon the surface, the cells that are most affected undergo necrosis and indolent ulcers are produced. The process may not go beyond an erythema

Digitized by Google

or congestion. If so, the erythema or congestion, first diffuse and later sharply circumscribed, becomes less marked and finally fades out. Scaling of the epidermis occurs, and at last a pigmented area is left to mark the site of the reaction. If the process goes on to the formation of ulcers the lesions that occur are very indolent. In the burns which M. Becquerel and M. Curie produced on their own persons the ulcers did not heal for about two months, and the duration was longer in the case reported by Hallopeau. All this is, of course, very strikingly like *x*-ray burns. Indeed, most of the descriptions which have been given of radium burns and the changes produced by radium in skin lesions might with perfect accuracy be applied to similar *x*-ray reactions.

Mackenzie Davidson has described a peculiar reaction which occurred in the course of the treatment of a case of carcinoma of the face with radium. In this case, after a long exposure to radium, an attack of what appeared to be erysipelas developed, with a temperature of 105, nausea, vomiting and prostration. A second similar attack occurred in the same patient, with a temperature of 103 after another long exposure. That these attacks were probably not true erysipelas is shown by the fact that culture experiments made from the serum, the blood and the secretion from the burn were negative. The explanation of these phenomena is probably a toxemia resulting from the absorption of cells rapidly degenerating, as the result of a very acute radium reaction.

According to Scholtz, the incubation period of radium burns is twenty-four to forty-eight hours, much shorter than that of *x*-ray burns, but an examination of the literature does not bear out this statement. The burn on Curie's person developed fourteen days after exposure, and Becquerel's developed ten days after exposure. In Halkin's experiments on young pigs, to be described later, the diffuse livid color developed eight

Digitized by Google

days after the first exposure; the microscopic effects were most marked at the end of twenty-five days; after thirty-eight days the area showed only diffuse pigmentation and a few scales. In another of Halkin's experiments the first effect showed fifteen days after the first exposure. In the cases of epithelioma and lupus which have been treated with x-rays, the effects apparently developed usually from three to eight days after exposure. In a carcinomatous ulcer reported by Exner and Holzknecht, the lesion healed seventeen days after the first exposure, and twenty-nine days after the first exposure all trace of it had disappeared. It would seem, therefore, that the incubation period of radium burns is not strikingly different from that of x-ray burns, and with greater experience we may find that the difference is even less than appears at first glance.

EFFECTS ON THE EYE.

Radium produces luminous effects on the retina even when the eyes are closed. This is due either to fluorescence of the tissues of the eye, or to direct effect on the optic nerves, probably to the former. This effect has been taken advantage of by Javal, London and others in experimenting on the blind with radium. In his experiments Javal found in two cases of blindness in which there still remained a slight perception of light, that the patients perceived a light sensation when radium was held before the eyes. In two other cases of blindness, one due to optic atrophy and the other to glaucoma, both patients being absolutely blind, there was no perception of light from exposure to radium. London's results are to the same effect. Blind subjects who still retained a slight perception of light perceived a visual sensation when radium was applied to their eyes. In those totally blind the results were negative. Other observers have obtained the same results.

EFFECTS ON THE NERVOUS SYSTEM.

The effects on the nervous system are interesting and

Digitized by Google

have been studied chiefly in young mice. London found that mice exposed to a strong preparation of radium were killed. There was first redness of the ears and blinking of the eyelids, then drowsiness, slowness of movement and feeble response to stimuli. This was followed by paralysis, then coma, and finally death. The symptoms developed about the third day of exposure, and the animals died on the fourth or fifth day. Along with these nervous symptoms were well marked effects on the skin. The hair and epidermis were loosened and the subcutaneous tissue was greatly congested. Similar experiments have been made on mice by placing the radium in actual contact with the surface. In a young mouse, one month old, in which a tube of radium was placed under the skin over the vertebral column, paresis occurred at the end of three hours, ataxia after seven hours, tetaniform convulsions and death in twelve to eighteen hours. Mice three to four months old died with the same symptoms in three to four days; those one year old died in six to ten days; guinea pigs, eight to twelve days old, died with similar symptoms in six to eight days. Adult guinea pigs and rabbits treated in the same way did not show any nervous troubles, but died with skin lesions some weeks or months afterward. An adult rabbit, in which a tube was placed under the dura for eight hours, developed a hemiplegia on the third day. It is probable that the difference in results in these experiments in young animals and in adults is due to the fact that the cartilages and soft bones of the young offer little resistance to the radiations from radium, while the well-developed bones of the cranium and spine of adults offer an effectual barrier to the α and β rays.

In brief, the symptoms are: First, depression of the central nervous system, followed by arrest of the functions of the cerebrospinal system, and then death. The explanation of these nervous symptoms lies doubtless in the disintegration of the nerve cells produced by the Becquerel rays.

Digitized by Google

MICROSCOPIC EFFECTS ON TISSUES.

The microscopic changes produced in tissues by radium have been studied by Exner, Scholtz, Halkin and others. The studies of Halkin are the most elaborate and are particularly interesting because they were made on young pigs and can be compared with the very thorough study by Scholtz of x-ray burns produced experimentally in pigs. Halkin's studies, epitomized as briefly as possible, are as follows:

He used for experiments to determine the action of Becquerel rays on the skin guinea pigs and young pigs, the cutaneous structure of the latter corresponding very closely to that of the human skin.

Microscopically, there was no change from the normal one day after exposure. After three days the first changes were evident, these consisting of increased prominence of the capillaries of the upper part of the corium. After five days the capillaries were noticeably dilated, but there was no change visible in their walls and no surrounding infiltration. After seven days a slight infiltration was visible around the vessels, and there were some leucocytes in the connective tissue, and all of the capillaries and small vessels were much dilated and filled with blood. The cells of the intima were swollen and their nuclei were larger than normal. As yet no change had appeared in the epidermis. Twelve days after the first exposure the changes in the blood vessels were still more marked. There was much degeneration of the cells of the vessel walls, which were markedly vacuolated, and some of which had dropped off into the lumina. Pigment cells in the corium were much more numerous than normal. In the center of the affected area the connective tissue of the corium was degenerated. There was marked vacuolation of the cells and the connective tissue was infiltrated with leucocytes. The entire palisade layer of the epidermis showed numerous vacuolations. The protoplasm stained with difficulty, the nuclei were fragmented and the boundary between the epidermis

BOSTON
MAY 5 1936

Digitized by Google

and the cutis was indistinct. A few leucocytes were present in the epidermis. After twenty days there was present a condition of ulceration. The horny layer of the epidermis was raised up, broken into flakes and contained some nucleated cells. The rete malpighii had almost entirely vanished, being represented only by one or two rows of irregularly swollen cells with faintly stained nuclei. The only remains of the palisade layer was a mass of cell remnants and fragmented nuclei. There was much more pigment present than normal, lying among the fragmented cells. The corium presented in a more advanced degree the changes already described. There were only a few leucocytes to be found in the exudation. The hair follicles showed the same degenerative changes as the epidermis, but to a less marked extent. After twenty-four days the dilatation of the blood vessels was advanced to such an extent that they were represented by large spaces through which hemorrhage had taken place into the tissues.

From this series of observations it is evident that the Becquerel rays affect at the same time all of the elements of the skin, epithelium, connective tissue and blood vessels. The effect on the vessels appears first, but there is no reason to look upon this as the cause of the other phenomena.

Halkin has also exposed areas of lupous tissue to the Becquerel rays. Here, both in the normal and in the lupous tissue, there was cellular degeneration, dilatation of the vessels and hemorrhage. The changes appeared, however, only in the most superficial layers of the skin, and the deeper portions were unaffected, not the slightest change being visible.

Time does not permit me to compare here with these studies of Halkin's the studies of Scholtz on x-ray burns in young pigs; but comparison would be interesting and instructive on account of the striking similarity of the findings. Indeed, one description might almost be substituted for the other, so closely do they agree, and the

Digitized by Google

two studies seem to leave little room for doubt that the histologic changes produced in tissues by x-rays and those produced by radium are almost identical in character. The chief difference, indeed, is the greater depth of the x-ray effects. There is the same inflammatory reaction, the endarteritis and the degeneration of the affected cells. And doubtless the explanation of the changes is the same. The living cells are susceptible to the actinic energy of Becquerel rays, as they are to the actinic energy of x-rays, and under the bombardment of this energy their structure is at first disturbed and then disintegrated. And in my opinion, although we have no microscopic studies on which to base the statement, the explanation of the disappearance of epitheliomata and similar growths under Becquerel rays is the same as after x-ray exposure. The tumor cells are as susceptible as the healthy cells to the actinic effects of Becquerel rays, but they are of lower resistance, and their structure is disintegrated, and they degenerate before the healthy cells are so violently affected.

EFFECT ON BACTERIA.

According to the meagre experiments thus far available, Becquerel rays have bactericidal properties. Aschkinass and Caspari found that three hours' exposure to radium killed the bacillus prodigiosus in cultures. Pfeifer and Friedberger found that cultures of typhoid and cholera bacilli exposed at one cm. distance from radium were killed, and Henry Crooks reports similar results on various bacteria exposed to Becquerel rays.

THERAPEUTIC APPLICATION.

Now, what are the therapeutic possibilities which are held out to us by these various properties of Becquerel rays? In a general way, I think there can be no doubt that the therapeutic indications for the use of Becquerel rays lie along the same general lines as the therapeutic indications for the use of x-rays.

Perhaps Becquerel rays have greater bactericidal prop-

Digitized by Google

erties *per se* than x-rays, but x-rays do indirectly cause the destruction of bacteria in living tissues, and I doubt very much if it will be proved that there is any material difference in this respect between these different forms of energy.

The effect of Becquerel rays upon the nervous system may possibly in future have some therapeutic application—he would be a bold man who would deny any possibility to such an agent—but it is not easy to see any practical application of this property at present. The skull and spine present an effectual barrier to all of the radiations from radium except γ rays, and the effect of γ rays is so slight that we are practically precluded from producing any effect upon the central nervous system by radium, without removing the bony envelope covering the area which we wish to affect. But even were it possible for us to get the effect of Becquerel rays upon any part of the central nervous system, I know of no conditions except new growths in which the application of the agent offers any present possibilities.

It is hard to see what application can be made of the fact that in persons who are partially blind a visual sensation can be produced by Becquerel rays. The experiments thus far simply indicate, what we already know, that the opacities which interfere with the passage of light and thus prevent its producing a sensation upon the retina, do not interfere with the passage of Becquerel rays, so that Becquerel rays can produce their normal effect on the retina of these subjects.

The probabilities thus seem to be that the field of usefulness of Becquerel rays will be in the destruction of bacteria, in the influence which they have on the metabolism of cells, and in the capacity which they have for causing destruction of cells of low resistance; in other words, along the same lines along which lies the usefulness of x-rays.

A consideration of the clinical applications which radium has thus far had lends further probability to this position.

Digitized by Google

CLINICAL RESULTS.

Aside from the use of radium in malignant neoplasms, it has been given a very limited trial in a few cutaneous diseases.

Acne.—Williams reports that he has treated one case of acne by exposing each pustule to the radium through an opening in a sheet of lead foil. These applications were followed by healing of the pustules.

Eczema.—Williams, in two cases of eczema, gave two exposures with some improvement.

Psoriasis.—Williams, in two cases of psoriasis, used radium over some small areas, which healed a few days after the exposure. Holzknecht also has reported beneficial results from radium exposures in psoriasis.

Lupus.—A number of cases of lupus successfully treated with radium have been reported by various observers, including Danlos, Scholtz, Holzknecht, Davidson, Williams, Blandamour, Abbe and MacIntyre. The results are of the same character as those gotten from the use of *x*-rays, and seem to indicate that we now have a third method added to those at our command for the treatment of this disease. But there is no evidence that it is better than either *x*-rays or ultra-violet light, and, according to Halkin's experiments, the lack of depth of the effect on the tissues would indicate that it is not so efficient as either of these other methods. In some of the cases a successful result has been produced by only one exposure, so that there may be a possibility of greater rapidity of results with radium than by other methods.

Keloid.—Williams has treated two small keloids in one patient, one with radium, the other with *x*-rays. He has had improvement in both lesions, but this has been more rapid in the one treated with radium.

Telangiectases.—Holzknecht has exhibited a case of flat vascular nevus in which at points of application of radium there had been a reaction followed by destruction of the blood vessels, so that at these points there were islands of skin of normal white color.

Digitized by Google

In the very limited trial which radium has had in the foregoing affections the results are apparently the same that are gotten from the use of x-rays. From what we know of the effect of radium on tissues, and bearing in mind the similarity of this effect to the effect of x-rays, I believe it will be found that radium has a distinct field of usefulness in some of these cutaneous diseases. In chronic intractable eczemas, in psoriasis, in lichen planus and in similar chronic inflammatory diseases of the skin there are good theoretical reasons for expecting benefit from the effect of Becquerel rays. In acne, too, there is a possibility of usefulness of this agent, and perhaps in sycosis, though if it is to be useful in these conditions it would seem necessary to be able to treat the cases by general exposures rather than by attempting to give an exposure to each individual lesion. In lupus there are certainly good grounds, both from theoretical considerations and from definite results already obtained, to attempt the use of radium. In keloid and nevus there is good ground to hope for the usefulness of this method of treatment. With Holzknecht, I believe from theoretical considerations that radium probably offers us a better method of treating vascular nevus than we have either in x-rays or ultra-violet light.

Epithelioma.—The successful treatment of epitheliomata with radium has been reported by a number of observers—among others, by Sichel, Scholtz, Davidson, Williams and Abbe. Including with epithelioma rodent ulcer, Williams has reported twenty-eight cases treated with radium. About half of these cases are healed and half show improvement more or less great. Most of the cases reported by the various observers are small epitheliomata, such as offer no difficulty of treatment by x-rays, and the results do not indicate that radium is either more or less efficient in these cases than x-rays. Williams has reported a case of epithelioma of the lower lip which has shown greater improvement under radium than under steady exposures to x-rays, and

Digitized by Google

Mackenzie Davidson has had a similar favorable experience in an epithelioma successfuly treated with radium, which had resisted both Finsen's and x-ray treatment. On the other hand, MacIntyre has reported a case of epithelioma which was not affected by exposures to radium, but which was cured by x-rays, although the radium used in the case produced burns on normal skin with much less exposure than was given the epithelioma. There are, in addition to the cases of moderate severity referred to above, a few severe cases of cutaneous carcinoma treated with radium which reflect distinct credit on this method of treatment. The following case of Davidson's is one of these: There was an extensive carcinoma on the right side of the face in which the right cheek had been destroyed, the tongue and teeth laid bare, the upper and lower lips destroyed to within an inch of the middle line, and the hard and soft palate extensively invaded. After vigorous exposures for some time there was on two occasions the development of an erysipelas-like reaction, which was followed by great improvement. At the time of the report the discharge was greatly lessened and not at all offensive, the tongue was clean and the patient could speak distinctly. Cicatrization was going on slowly but steadily. Both x-rays and operation had failed in this case. The improvement in this case is not unlike that which has been noted under x-ray exposures in numerous equally severe similar cases, but the fact that x-rays had failed in the case is to be borne in mind, and the improvement under radium after the failure of x-rays should be allowed due credit.

Carcinoma.—In carcinomata beneath the skin the reports indicate that radium will clean up small subcutaneous nodules, but there is nothing to indicate that it will be anything like so efficient an agent as we already have in x-rays for any but the most superficial growths.

Davidson has treated several cases of carcinoma with radium with no good results, and he epitomizes his ex-

Digitized by Google

perience with the statement that "the conclusion forced on us is that with the present method of application radium is of no use whatever in carcinoma."

Reed has caused the disappearance of subcutaneous nodules of recurrent carcinoma of the breast by exposures to radium, and Williams has treated three cases of recurrent carcinoma of the breast with improvement.

On account of its convenience of application, radium may have a field of usefulness, in the palliative treatment at least, of carcinomata in the cavities of the body, and benefit has been seen in carcinoma of the rectum, of the uterus, and of the esophagus.

Carcinoma in the Cavities of the Body.—In two cases of cancer of the uterus Abbe found the symptoms much ameliorated, with marked loss of cancerous cachexia as the result of treatment with radium, and he saw similar improvement in cases of rectal carcinoma.

Cleaves has had great improvement from the combined use of radium and *x*-rays in uterine carcinoma.

I also have seen apparent benefit from the insertion of a tube of radium into the cervix uteri in carcinoma of the uterus.

Carcinoma of the Esophagus.—Exner has very ingeniously used radium to overcome impermeable strictures of the esophagus. He introduced the radium imbedded in dammar and fastened to a No. 16 bougie. In five cases the stricture became enlarged, and the dilatation persisted after the treatment was stopped. The increased permeability of the stricture, he thought, was due to the necrosis of the tissues under the influence of the radium. Of course, this treatment should not be undertaken without due consideration of the possibility of perforation.

I think it possible that radium may be used to advantage in similar manner by insertion into tuberculous and other sinuses, and into the substance of malignant growths, as has been suggested.

Sarcoma.—Radium has had a very limited applica-

Digitized by Google

tion in sarcoma. Abbe has briefly referred to one giant cell sarcoma of the jaw, under treatment with radium, which has shown noticeable improvement.

Exner and Holzknecht have demonstrated a case from Professor Gassenbauer's clinic, Vienna, of melano-sarcoma of the left humerus. Three years before a sarcoma had been removed, and after eight months several subcutaneous dark colored nodules had been noticed. A section from one of these proved them to be melano-sarcoma. Nodules exposed to the point of producing dermatitis disappeared, their place being revealed only by depressed cicatrices. In another case of melano-sarcoma they had similar success in removing cutaneous metastases with radium.

Cleaves has reported a sarcoma of the left cheek which has been improved under radium exposures.

SUMMARY OF RESULTS.

The results which have been obtained from the use of radium in cutaneous carcinomas, epitheliomas and rodent ulcers are certainly interesting, and show, I believe, that we have in the use of radium another efficient method of treating small cutaneous carcinomas with radiant energy. And if that is so, there is certainly the best possible reason for making every effort to determine the full limit of usefulness of radium in these conditions. Whether radium or *x*-rays will prove the better agent for the treatment of cutaneous carcinomas without metastases, which are now so well treated with *x*-rays, only future experience will show. I do not believe that radium or any other method can possibly give better results than are now gotten in most cases of this sort from the use of *x*-rays, but with improved technic as a result of greater experience it may be found that radium will prove the more convenient and the more easily applied of the two agents. If it shall be proven by future experience that radium is the better method of treatment, I believe its superiority will be found to rest on unessential questions of convenience and ease of

Digitized by Google

application, rather than on any essential superiority. Possibly in epithelioma, and, indeed, lupus and other conditions that ordinarily yield to x-rays, some of the very rare cases which fail to yield to x-rays may be found to yield to radium, as already found in one of William's and one of Davidson's cases.

Doubtless also we will find cases which will not yield to radium, and these cases may be among the very large proportion that yield to x-rays. Indeed, exactly this has happened already in a case of MacIntyre's which yielded to x-rays after a strong preparation of radium had failed. Thus the two agents may be of value in supplementing each other in certain cases which prove insusceptible to one or the other. According to William's experience, and this is confirmed by some other reports —the improvement in epitheliomas and certain other conditions which yield to x-rays and to radium, is more rapid under radium than under x-rays, but our data are not sufficient yet to allow any definite conclusions upon this point. The length of treatment with x-rays, and doubtless with radium, is largely dependent on the manner in which the exposures are given, and the question of rapidity of cure, therefore, is in part a matter of technic.

The attempts at treatment with radium of malignant neoplasms beneath the surface are not encouraging, and on theoretical consideration I do not believe that we may expect much usefulness from radium in the treatment of any sort of malignant growths beneath the surface. I believe that in this particular we will find radium distinctly less valuable than x-rays. On the other hand, radium, I believe, will have a definite though limited field of usefulness in the treatment of lesions situated in inaccessible locations where it is difficult or impossible to apply x-rays, but where radiations from radium can be applied readily. For example, in carcinoma of the uterus, of the rectum, and of the mouth, the application of radium offers no difficulty, and if it proves an

Digitized by Google

agent of even slight efficiency in controlling the growth of malignant neoplasms it surely has a field of usefulness in malignant growths in the less accessible cavities of the body. This is shown already in its use in carcinoma of the rectum, of the uterus, and of the esophagus. I think I may say that I have found it distinctly of value inserted into the cervix in uterine carcinoma, and I have certainly found it valuable in the treatment of lesions in the mouth that were impossible of direct exposure to *x*-rays. Radium also offers a possible advantage over *x*-rays in the accuracy of dosage which its use makes possible when we have definitely determined its range of activity. With a given preparation of radium we can give a definite dose of the radiations, the only varying factors in the exposure being the distance from the lesion and the duration of the exposure. Such accuracy, of course, is impossible with *x*-rays. That this advantage will prove of material value in the hands of experts I think questionable, since the *x*-ray exposures can already be given with sufficient accuracy as to dosage for all practical purposes. On the other hand, *x*-rays have a very important advantage over radium in the quantity of energy at our command. The amount of energy available in a well-excited *x*-ray tube is enormously greater than that emitted by any quantity of radium now obtainable or likely to be obtainable.

GENERAL CONCLUSIONS.

To sum up, then, the situation, in my opinion, is about as follows: Radium produces effects upon the tissues closely analogous to if not identical with those produced by *x*-rays. The indications, accordingly, for its therapeutic uses are along the same lines as those for *x*-rays, viz., in certain inflammatory diseases of the skin, like eczema, psoriasis, lupus erythematosus and lichen planus. In certain bacterial diseases of the skin, like acne, sycosis, lupus vulgaris and blastomycosis. In certain diseases where we wish to cause destruction of tissues of

Digitized by Google

low resistance, as in lupus vulgaris, carcinoma and sarcoma.

These are exactly the indications for the therapeutic use of x-rays, and future experience alone can determine which of the two agents will prove of the greater practical value in meeting these indications. In some respects I believe radium will prove superior; in the far greater number it seems to me that x-rays will have the larger field of usefulness. In the treatment of lupus and cutaneous carcinoma, we have sufficient experience to give us a fairly accurate technic in the use of radium. For its use in affections other than those which are sharply circumscribed to small areas, the technic has not yet been developed.

It is probable that Becquerel rays will be efficient only to a very limited depth. This conclusion is based, first, on the fact that the greatest effect on the tissues is produced by the β rays, which have a relatively slight penetration, and, second, on the studies made by Halkin on the effect of radium on tissues. On account of lack of depth of effect it is not likely that radium will be as effective as x-rays against lesions of more than half an inch in thickness or subcutaneous in situation. Becquerel rays have theoretical advantages over x-rays in the accuracy of dosage which will be possible after we have obtained experience in their use. They also have advantages in their ease of application at inaccessible points. They have a disadvantage in the relatively small quantity of energy available, and in the limitation accordingly of any single efficient exposure to a very small area.

It is highly improbable that the use of radium is going to be of epoch-making importance in therapeutics. It supplements and it may add materially to the methods now at our command for using actinic radiant energy in therapeutics. If it becomes less expensive and obtainable in relatively larger quantities, it may supplant to a limited extent the use of x-rays and ultra-

Digitized by Google

violet light, although in my opinion this is not probable. At the present time it is not an entire substitute for either of them, and is to a very great degree less efficient than x-rays in its general therapeutic usefulness.

Finally, the therapeutic possibilities of radium have, in my opinion, rather been overstated than understated in the foregoing estimate.

DISCUSSION.

Dr. William T. Corlett, Cleveland, Ohio—I have seen the effect of radium in Cleveland and can corroborate some of the statements made. It does have an effect on certain structures in certain diseases of the skin, lupus and epithelioma especially, but so far as I have been able to see has less effect than that produced by the x-ray. Certain cases in Cleveland have been treated as was the following: A case of lupus vulgaris was treated with the x-ray successfully at first, but there came a time when the x-ray failed to produce any further effect and then it was supplemented by treatment with radium, and for a time apparently with marked benefit. There was a reaction which kept up for a certain length of time, so that the disease was decidedly better than when the x-ray was discarded, but continued treatment failed to produce any further favorable effect. It was thought it might act as a stimulant to the effect of the x-ray. Those of you who have had experience know that a point is frequently reached when further treatment is useless. I had an opportunity of seeing these cases subjected to the Finsen light when benefit from the x-ray failed and those cases usually went on satisfactorily. You can see cases in Finsen's laboratory of lupus vulgaris where there came a stage of the treatment when the Finsen light failed to have further effect and the x-ray applied would complete an apparent recovery. So we thought in Cleveland that radium might serve this purpose, but so far our experience has been rather disappointing.

Dr. Jay F. Schamberg, Philadelphia—In the Philadelphia Polyclinic we have employed radium in a limited number of cases of cutaneous diseases. Most were carcinoma of the skin; some were extensive and perhaps we should not have expected any favorable result from the use of radium. In several other cases, however, the extent of the growth was limited. The radium employed was said to be of 1,400,000 activity, made by Tschamer of Hamburg. In only one of the patients treated was there any definite reaction from the radium. The applications were made by contact with the skin. In the last patient, treated a few weeks ago for a small superficial epithelioma of the side of the nose, there was a very distinct

Digitized by Google

reaction after perhaps five or six treatments of one hour each, given about twice a week; the reaction was followed by a superficial necrosis which, after healing, was followed by a very great softening of the induration. At the present time the epithelioma is considerably improved, but will require further treatment.

While we may have in radium a remedy which permits of accuracy of dosage, there must be considerable difference in the reaction of the skin of different individuals to this remedy. In a patient with blastomycosis of the skin radium was applied for 15 treatments, one hour each, without the least reaction being visible. In another patient, the case just referred to, after five treatments there was a very distinct alteration of the skin. It seems to me that in radium we have an agent with a very restricted field of usefulness. We know that the penetrating power of radium is extremely limited. We attempted at the Polyclinic to photograph the hand of a cadaver with the particle of radium mentioned and exposed the hand twenty-four hours; at the end of this time the plate was developed and showed merely a shadowgraph of the entire hand without distinction of the bone structures. I therefore agree with Dr. Pusey that the amount of energy which is given off from radium is extremely small and not to be compared with the great quantity of energy radiated from an excited Crookes tube. If radium is to acquire a place in the therapeutics of cutaneous and other diseases it will probably find its most fertile field of usefulness in inaccessible mucous cavities. It is possible that radium of high activity may be advantageously employed in the deep recesses of the nose, mouth, vagina or rectum, but up to the present time no wonderful results have to my knowledge been obtained. Indeed, I do not know that radium has cured any conditions that would not have yielded to other approved methods of treatment.

The public press is largely responsible for the highly colored and exaggerated accounts of the therapeutic virtues of radium. Newspaper articles have excited the popular mind to a state of expectancy which practical results have not justified. The physical properties of radium far transcend in interest and importance its virtues as a remedial agent. Physicians should be very slow to advise the application of radium for the relief of conditions which can perhaps be better treated by safer and more efficient methods.

Dr. L. Duncan Bulkley, New York City—I entirely agree with the conclusions Dr. Pusey has drawn. I have been observing radium in the New York Skin and Cancer Hospital clinic for six months. We have had a dozen or more cases submitted to its application. Unquestionably radium has a powerful effect on the tissues; in several cases we got burns quite

Digitized by Google

as marked as with the x-ray, only of small size, because the application of radium only covers a small area. So there is no question that it can have a powerful effect if the applications are made long enough. We began with an application of 15 minutes' duration on a boy 13 years old who had had lupus on the cheek since early childhood. I was enthusiastic, having read the accounts in the French journals six or eight months ago, and I spoke of it in the clinic and insisted that we would have this boy well after half a dozen applications. After three months the lupus was still there. The boy was a pay patient that I had sent to the hospital, and I did not feel justified in carrying out further experiments with him. He was then exposed to the x-ray for six or eight months, and when I saw him a week ago we could barely perceive one or two little points, the majority of the surface being smooth and to all intents he was well. We tested several other cases of lupus with the same result. I think, however, as Dr. Pusey said, radium is going to be a valuable addition to our armamentarium in the application to inaccessible cavities. We have had at the hospital several cases of epithelioma within the buccal cavity thus treated. In one case the man with epithelioma beneath the tongue, in front, declining operation, was treated by radium, and certainly the disease melted down nearly half. Another case of epithelioma of the tongue, far back toward the tonsil, which would have required a very formidable operation by surgical means, was melted down in the same way. The effect of radium in that case was certainly marvelous. I think we are only beginning to study the subject, but Dr. Pusey's paper is very timely in view of the extravagant statements in the newspapers and what the French have said in the skin journals. I think, however, that we have never seen such results as they claim to have produced.

Dr. M. L. Heidingsfeld, Cincinnati—On what exact distinctions do scientists base their division of Alpha, Beta and Gamma rays? Is it a purely arbitrary and empirical division, based largely, as noted in the paper, on the varying degrees of facility with which some of these rays penetrate interposed layers of resistance? It appears to me that the exact nature of these rays is still an unsolved problem, much the same as their analogous and apparently somewhat closely allied x-rays. A more rational explanation would be that they consist of minute radioactive material particles, driven with intense but with varying degrees of velocity and penetrative power.

Dr. William Allen Pusey—I think that the general experience corresponds to what I have gathered from the literature and to my own experience. I believe we must make some allowance in the difference in our results for the fact that there is a very great difference in the activities of the preparations of radium available. The German radium bro-

Digitized by Google

mid, of which Dr. Schamberg spoke, is highly active, but I do not think that even it will give such marked effect as some of the preparations of radium of the Curies. As to the use of radium of seven, ten or twenty thousand units activity, it is relatively so weak that its application must be very long to obtain any effect. I agree with Dr. Schamberg that there is probably a very decided difference in the susceptibilities of different individuals to radium radiations. I have also attempted to use in conjunction with radium other radioactive substances. Dr. Schamberg has used uranium. I have tried thorium nitrate and oxid, which are more active than uranium and comparatively cheap, but I have not seen any definite effects from them.

Digitized by Google

A CASE OF DARIER'S DISEASE.

PSOROSPERMOSE CUTANEE FOLLICULAIRE VEGETANTE OR KERATOSIS FOLLICULARIS (WHITE).

DAVID LIEBERTHAL, M.D.

Professor of Skin and Venereal Diseases, Illinois Medical College; Consulting Dermatologist Lakeside Hospital; Dermatologist to the Chicago Home for Jewish Orphans; Dermatologist to the Michael Reese Hospital Clinic.

CHICAGO.

In the last fifteen years, since this affection became known under the above names, there was published in all thirty cases.[1] Cases under this heading demonstrated or published by Mansuroff, Zeleneff, Kroesing, Savill, Gra-

1. The following is a list of these thirty cases:
1. Darier et Thibault: Annales de Dermatologie, July, 1889, and Thèse de Paris, 1889.
2. Darier: International Dermatological Congress, Paris, 1889. (These two cases were subsequently published in the International Atlas of Rare Skin Diseases, Part 8, 1892, ii.)
3-4. White: Journal of Cutaneous Diseases, June, 1889, and January, 1890.
5-8. Boeck: Archiv f. Dermatologie, vol. xxiii, p. 857, 1891.
9. Lustgarten: Journal of Cutaneous Diseases, January, 1891.
10. Buzzi and Miethke: Monatschefte f. Dermatologie, vol.. xii, p. 9, 1891.
11. Boeck: Second International Dermatological Congress, 1892. Ref. Archiv f. Dermat., vol. xxiv, p. 1000.
12. Schwimmer: Archiv f. Dermat., vol. xxiv; Ergänzungsheft, p. 76, 1892.
13. De Amicis: Second Internat. Dermat. Congress, 1892.
14. Schweninger und Buzzi: International Atlas, Part 8, 1892, ii. (One of these two herein published was previously reported by Buzzi and Miethke, under 10.)
15-16. Pawloff: Archiv f. Dermat., vol. xxv. Ergänzungsheft, p. 195, 1893.
17. Fabry: Archiv f. Dermat., vol. xxvi, p. 373, 1894.
18. Mourek: Ibid., vol. xxvii, p. 361, 1894.
19. Jarish: Ibid., vol. xxxi, p. 163, 1895.
20. Neumann: Wiener klin. Wochenschrift, No. 3, 1896.
21. Bowen: Journal of Cutaneous Diseases, June, 1896.
22. Hallopeau et Darier: Annales de Dermatologie, 1896, pp. 737-742.
23. Bowen: Ibid., 1898, p. 6.
24. Melle: Giornale Ital. delle Malattie, etc., 1898, p. 365. Ref. Annales, p. 506, 1899.
25. Jacobi: Verhandl. d. Deutschen dermat. Gesellschaft, VI Congress, p. 406, 1898.
26. Caspary: Festschrift, Kaposi, p. 199, 1900.
27. Ehrmann: Wiener med. Presse, No. 46, 1901.
28. Hallopeau et Fouquet: Annales, p. 228, 1902.
29. Schwab: Inaugural Dissertation, Freiburg i. Breisgau. Ref. Annales, p. 627, 1903. (This case seems to be identical to that of Jacobi.)
30. Weidenfeld: Archiv f. Dermat., vol. lxiv, p. 275, 1903.

Digitized by Google

ham, Little, Sokoloff, Bogroff and Huber lack many essential features, and can not therefore be considered as cases of this affection.

HISTORY OF THE AUTHOR'S CASE.

Our case, which represents the thirty-first of all cases, and the sixth of the cases occurring in the United States, concerns a young man of 25, born in a small town in the south of Wisconsin. His parents are German, and claim that they do not know of any skin disease occurring in their family except the present case. They themselves have always enjoyed excellent health, as did their two daughters of 17 and 18 respectively, and their younger son of 14. The patient passed through an attack of measles in early childhood, but was otherwise well, except for accidental injuries. He was vaccinated at the age of one year, and soon afterward the first pimples were noticed on the scalp, on the face and behind the ears. They gradually and slowly increased in number until the age of 12, when they spread over the chest and back, some appearing on the arms, and very numerously on the legs. His condition grew steadily worse, especially on the legs, where three years ago the first signs of horny growths appeared. His nails became thick and broke at the free edges. Itching was scarcely noticed. He enjoyed good health, but was annoyed by the dark coloring of his face.

The patient appears strong and healthy. His hair is black, his eyes dark brown, and the whole integument rather dark. Accessible mucous membranes and internal organs normal; inguinal glands slightly enlarged. On close approach to the legs, a slight odor was perceptible. On inspection of the integument, the following symptoms were noted: The scalp showed a thick growth of healthy hairs, which appeared as if imbedded in a thick layer of dirty white brittle masses, after the removal of which the scalp looked as if worm-eaten. The face was intensely dark and greasy. The hand, on glid-

Digitized by Google

ing over it, felt a rough surface. This roughness was caused by minute horny elevations, closely aggregated. Over the brows, around the alae of the nose and on the chin were found elevated brown papules, forming plaques. These papules were of pinhead size or slightly larger, the greater number of these showing a central horny mass.

The ciliary margins of the upper eyelids were beset with sparse horny nodules pierced by ciliæ, resembling ciliary blepharitis. Behind the ears, in close proximity to the insertion of the auricles, there were located dark, almost black, tumor-like formations, fissured in different directions resembling papillomatous growths. These plaques were composed of numerous coalescing papules, with central horny plugs.

On the nape of the neck, along the hair line, on the back in the suprascapular regions and along the spine, as well as over the sternum, numerous densely arranged papules of sizes to that of a split pea were found. They were either of the color of the surrounding skin, or yellow or brown, containing a central horny plug, which latter could with difficulty be pressed out, leaving behind a crater-like opening, the base and margins of which looked as if torn. Nowhere was there found a pink or red areola around the papules. Intermingled with the papules were comedones.

Other parts of the trunk showed scanty single lesions of the above-described type, but the axillæ and inguinal regions were free.

The upper extremities showed here and there a scattered lesion. The dorsa of the hands and of the fingers were covered with numerous flat warts, and the nails showed longitudinal striation, and were split at their free margins. The genitals and circumanal regions were free from the affection.

The lower extremities, down to and including the aspects of the knee joints, showed scanty lesions, while below the knees, encircling the tibiæ, were irregularly-

Digitized by Google

shaped, uneven, warty, tumor-like masses, yellowish-brown in color, some of them covered by firmly adherent crusts, which were loosened at their margins, thus exposing a red oozing basis. The attempt to lift the crusts reminded one very vividly of an attempt to lift the thick, rough bark from a tree when that bark is loosened at the edges.

Within the lesions there appeared crater-like openings in the rounded elevations, which resembled those on the

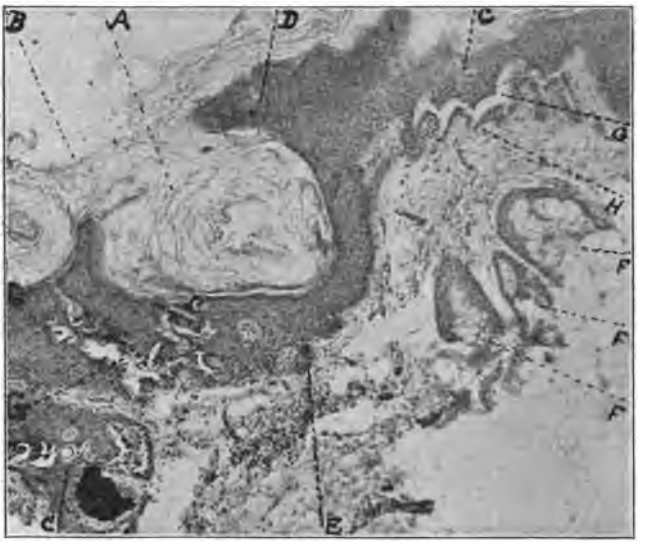

Fig. 1.—Magnified 150 times. A. Heart-shaped, horny plug in hair follicle. B. Granules of eleidin. C. "Corps ronds." D. Thickened stratum granulosum. E. The rete forming a broad band (under a horny plug), and a corresponding flattening of the underlying papillæ. F. Sebaceous glands. G. Fissures or lacunæ in the rete. H. A few layers of rete covering the papillæ beneath lacunæ.

trunk, but were larger. On the anterior aspect of the left tibia, from a thick, hard crust there emerged a form resembling a cornu cutaneum.

Between these large plaques, and around them, were scattered small papular lesions. The dorsa of the feet and the posterior aspects of the external malleoli were covered with numerous flat, small warts. The nails of

Digitized by Google

the toes showed no abnormal condition. It is necessary to add that the solitary papules everywhere were quite firm to the touch, while the above-mentioned aggregations over the eyebrows, in the naso-genial furrows, on the chin and behind the ears were comparatively soft and greasy to the touch. A plug squeezed out from one of the papules, examined in aqua ammoniæ showed a number

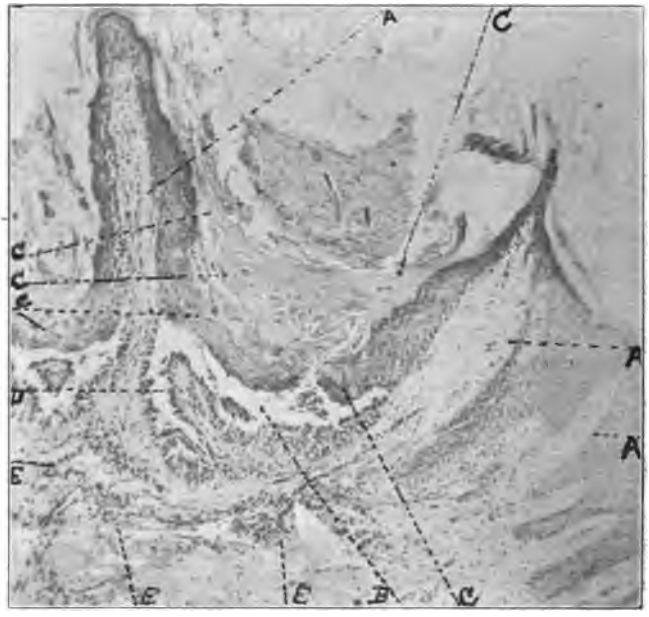

Fig. 2.—Magnified 150 times. A. Elongated papillæ. B. Gap or lacuna in the rete. C. "Corps ronds." D. Club-shaped papilla covered by two lowermost layers of the rete. E. Infiltration.

of epithelial cells, most of them containing a nucleus and bodies which, as the so-called "grains," will be considered later.

HISTOLOGY OF THE TISSUES.

For examination, a number of papular lesions from the back and a piece of papilloma-like mass from behind the ear were excised, fixed in Mueller's fluid plus formalin and imbedded in paraffin. The sections were stained

Digitized by Google

in hematoxylin, eosin, carmin, Unna's alkaline methylene blue and other solutions.

The horny layer, thickened as a whole, shows nodulations which represent horny plugs. These are mostly confined to the upper part of the hair follicles, and consist of densely-arranged lamellæ, or a horny network. These plugs are frequently heart-shaped and constricted at the upper part, where they are grasped by the surrounding epidermis, as a precious stone is held in its

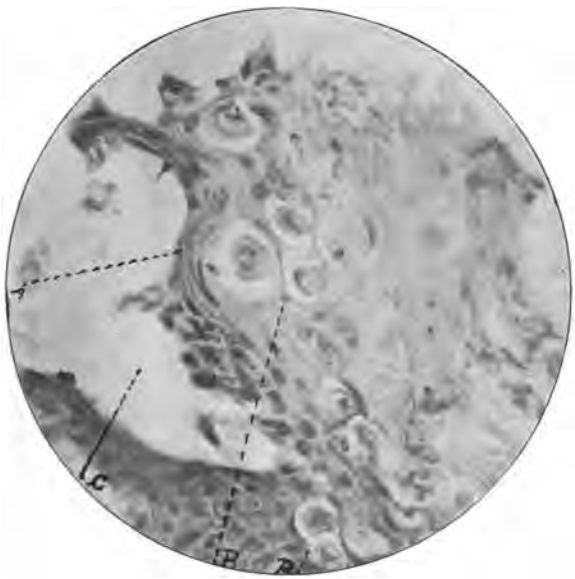

Fig. 3.—Magnified 500 times. Shows very numerous "corps ronds" near the gap C in the rete. A. Flattened epithelial cells surrounding "corps ronds." B. Flattening of the membranes of "corps ronds" situated in close proximity.

setting (Buzzi and Miethke) (Fig. 1, A). In the ducts of some of the sweat glands a dense horny peg is found reaching down to the level of the granular layer. There are horny plugs to be found independent of both these appendages, especially in sections of the papilloma-like formations, but the plugs confined to hair follicles are in the majority. In the upper strata of many plugs are granules of eleidin (Fig. 1, B), while in the deepest lay-

Digitized by Google

ers of densely lamellated ones numerous so-called "grains" are noted. The same are found at the bottom of plugs in certain ducts of the sweat glands. The stratum granulosum surrounding these plugs, especially at their upper portion, is thickened (Fig. 1, D), but is entirely wanting beneath most plugs showing grains. The rete

Fig. 4.—Lesions on the posterior aspect of the legs.

shows various conditions. In some places, beneath the plugs, it forms a broad band with an inferior convex border (Fig. 1, E), with nearly a complete absence of interpapillary processes. There is correspondingly a total flattening of the papillary body.

Digitized by Google

At the sides of many of the plugs the rete projects with considerably elongated processes into the corium. In other places beneath the plugs the rete is reduced to a few rows of cells, being thus atrophied. The cells of the rete under the plugs have undergone considerable changes, showing vacuolation, and having lost, in the lower portion of this layer, their intercellular union. For that reason gaps or fissures are seen separating two, or at most three, lower layers from the rest of the rete. (Fig. 1, G; Fig. 2, B; Fig. 3, C.) These latter layers (Fig. 1, H,

Fig. 5.—Lesions on the anterior aspect of the right leg.

and Fig. 2, D) cover closely the underlying papillæ and are for the most part in a normal condition.

In some places, where long plugs have fallen out, the cavity communicates directly with the aforesaid clefts in the rete. Throughout the rete are found numerous "corps ronds," one form of Darier's so-called psorosperms. These show various sizes, and are by far larger than normal rete cells. They contain a nucleus which is surrounded by a translucent zone, separating it from a granular coat of protoplasm. The whole is enveloped in a transparent membrane which, in the smaller forms, is doubly contoured. These bodies (Figs. 1, 2 and 3) are found throughout the rete, but most numerously near the

Digitized by Google

lacunæ or gaps, and near and within the stratum granulosum. Their size diminishes the further up they are situated, which is due to the transparent membrane becoming thinner, as well as to the diminution of the en-

Fig. 6.—The lesions on the back.

closure. In the stratum granulosum some of these cells have lost their membrane, and appear shrunken and homogeneous, with a faintly stained nucleus. These round or oval bodies represent the "grains," the second

Digitized by Google

form of Darier's psorosperms. The "grains" found in the plugs show the same characteristics.

In some places of the rete, especially in the middle layers, some "corps ronds" are surrounded by flattened cells (Fig. 3, A), which look as if compressed. In a few places two or three "corps ronds" are united, and the translucent membrane is flattened at the site of juncture. (Fig. 3, B.) The cells of the rete, at its lower portion, show a large mass of finely granular pigment. The corium does not show very marked changes. The elastic network is normal, and there are found foci of infiltration (Fig. 2, E), which consist of round cells, some plasma and a few mast cells. An eosinophilic cell was also occasionally found. The papillæ beneath certain plugs are totally flattened (Fig. 1, E); under others they appear club-shaped (Fig. 2, D), while at the sides of the plugs they are elongated. Especially is this so in the lesions presenting plaques, where they are very considerably elongated (Fig. 2, A), and, together with the proliferation of the rete, present a picture quite similar to that found in true papilloma.

The sebaceous and sweat glands appear normal, except that the ducts of the sweat glands occasionally contain plugs. Thus the clinical as well as the histologic conditions correspond entirely to the requirements of a true case of Darier's dermatosis.

COMMENTS ON THE HISTOLOGY.

Although the "corps ronds" and "grains," the so-called psorosperms, do not represent micro-organisms, as first claimed by Darier, nevertheless credit is due him for his original work in that this malady is known as a dermatologic entity.

The first to examine thoroughly the nature of these bodies and to pronounce them as atypically cornified epithelia was Bowen, whose views were corroborated by most of the later writers, and at last accepted even by Darier.

The presence of these bodies is essential, together with

Digitized by Google

the other details, to determine histologically the diagnosis, inasmuch as there are found similar conditions in other dermatoses where these bodies are absent. This fact has led some observers to class cases under this heading which do not belong to it. If we compare, for intance, sections of lichen planus hypertrophicus,[2] we encounter similar conditions. Thus we find horny plugs in follicles, in the ducts of sweat glands, and independent of both. There are also gaps in the rete, vacuolation of cells of the latter and a cellular infiltration of the cutis similarly arranged, but the typical bodies found in Darier's disease are absent. It is interesting to note that clinically the above mentioned form of lichen occurs in hyperkeratotic plaques, with depressions filled with horny masses.

Another interesting point to be considered is the question of the follicle being the principal seat of the affection. White, whose first case was published at about the same time as Darier's, found all the eruptions confined to the follicles, and, therefore, he called his case keratosis follicularis. In Darier's cases the same condition was found, and he therefore added to the original name the adjective "folliculaire."

White's cases were examined microscopically by Bowen, who found, in these, as well as in his own two cases, published later, the hair follicles the favorite seat of the plugs. But various other authors found the horny plugs more frequently independent of the hair follicles, and in Buzzi's and Schweninger's cases the ducts of the sweat glands showed the majority of horny plugs.

In serial sections of papular lesions of our case the hair follicles contain most of the plugs; only here and there one is found in the sudoriferous ducts, while in the sections from the plaques the plugs occurred also independent of either structure, but the majority in the hair follicles.

Since the cells above described, the "corps ronds" and the "grains" did not prove to be micro-organisms, the

2. THE JOURNAL A. M. A., Jan. 11, 1902.

Digitized by Google

original term for this affection proposed by Darier, viz., "psorospermosis," had to be abandoned. Inasmuch as hyperkeratosis and parakeratosis are main features of the process, White's name, "keratosis," could be substituted, although the adjective "follicularis" should be omitted, because in quite a number of cases published the follicles were not the favorite seat of the affection. In suggesting, therefore, a new term somewhat descriptive, embracing characteristic features, it would not seem inappropriate to add the name of Darier as well as that of White to the term "keratosis," and to call the disease "keratosis Darier-White."

Notwithstanding the fact that the etiology of this affection is unknown, it seems that heredity plays a certain rôle. Thus White's two cases are represented by father and daughter. Of Boeck's first four cases, three are those of father and two sons. Mourek's case is the father of Ehrmann's case. In Jacobi's case the mother of the patient was undoubtedly afflicted with the same disease.

This dermatosis offers the greatest resistance to all treatment. The present case was treated by applications of sulphur, ichthyol, resorcin and salicylic acid, and while under treatment the condition slightly improved. The face was treated with the *x*-ray exclusively, which benefited him so far that nothing remained of the eruption, the whole face becoming perfectly smooth, but the pigmentation remained as intense as before.

Owing to a severe accident the patient had to discontinue the treatment. Three months after the last application the father reported that the face still retained the improved condition, and March 29 of this year, nearly six months after the *x*-ray was discontinued, he presented himself for further treatment. His face was now free from eruption, there were but few lesions on the temple, and the pigmentation had nearly disappeared. The effect of the *x*-ray on the other lesions will be reported in due time.

103 State Street.

Digitized by Google

DISCUSSION.

Dr. Mortimer A. Moses, New York City—I have a case of this disease under observation at Mt. Sinai Hospital, the same case Dr. Lustgarten described some 14 years ago. In this particular case the treatment has been varied without much success. The patient has become cranky and does not submit to treatment well. We tried the *x*-ray on him once, but he claimed that he felt so weak and debilitated after the treatment that we had to desist, consequently we do not know how that agent will act. Lustgarten told me recently that he still considers the cause of the trouble coccidia and does not think it proved that it was a degeneration of the cells.

Dr. A. Ravogli, Cincinnati—I have had several cases of the same type as those reported by Dr. Lieberthal. After a while I began to study similar formations and found the same round bodies in lichen planus and other affections, and I accepted the opinion of Unna that these round bodies are nothing else than nuclei of the epithelial cells in a state of degeneration, and probably two, one on top of the other, which accounts for their peculiar appearance.

Dr. L. Duncan Bulkley, New York City—I would like to ask the gentleman who spoke of the case at Mt. Sinai Hospital if it was a man about 55 years of age.

Dr. Moses—Yes, sir.

Dr. Bulkley—We have all had him under observation, and some time ago I lectured about him as a case of psorospermosis. I have had a few of these cases, and recently one, not yet published, in the Skin Hospital. She was with us for many months, nearly a year, and the interesting part I wish to speak about is the result of the *x*-rays on certain portions of the disease. She had the eruption very well marked on the forearms and around the line of the hair running up into the scalp, and has been exhibited a number of times. We all agreed as to the diagnosis. Her palms and soles became enormously affected; the soles of the feet were simply a mass of epithelial growths, forming prolongations with fissures between them, one-fourth inch in depth, and so excessively sore and painful were they that she was bedridden for a number of months, and could not step on the floor. This was before the hospital had an *x*-ray apparatus. She was treated in various ways, and time and again the whole affair was curetted out, under ether, down to raw flesh. She repeatedly asked us, "Can't I be scraped again?" It would afford her relief from distress of the feet for months. After the scraping the feet were treated with all kinds of antiseptics. I think ichthyol gave the most relief; something like a 50 per cent. solution was used, also bichlorid, permanganate of potash and various other things. From what I had seen of the *x*-ray I promised her

Digitized by Google

that it would give her relief. She had a series of applications to the feet, fairly strong (I can not now tell the duration or distance), and within two or three months her feet cleared up entirely, so that she not only put on shoes and walked around the ward, but left the hospital, and comes now as an outpatient for the treatment of some portions around the face. Her feet have not troubled her since; I think she has an occasional application of the ray to the feet for prophylaxis. I have examined the feet, and the epidermis is in a normal condition, and she now has perfect comfort and satisfaction. The *x*-ray has not been applied around the face because the follicles are just in the line of the hair, but it was simply marvelous the influence exerted on the hypertrophic disease of the soles; it was beyond anything I had expected. Of course, none of us knows the reason or the method of action of the *x*-rays, but I felt that I ought to put the case on record in connection with this paper.

Dr. David Lieberthal—I am glad to hear that Dr. Lustgarten's case is still under observation. I am aware of the fact that Dr. Lustgarten still adheres to his opinion that the "corps ronds" are micro-organisms, although it has been conclusively proven that they contain keratohyalin, and, therefore, can only be considered as epithelial cells. I am cognizant of the case of Dr. Ravogli, which was reported before the Eleventh International Congress, showing some similarity to the affection under discussion. In reply to Dr. Bulkley, the case here reported is now published for the first time.

Digitized by Google

A FALSE OR CICATRICIAL KELOID.

A. RAVOGLI, M.D.
CINCINNATI.

The name of keloid was given by Alibert[1] to neoplasms made up of connective tissue in the form of patches, strips or tuberosities, having identity with cicatricial tissue. One kind of keloids is developed spontaneously in the derma, with which the keloids are intrinsically connected, while others take their seat on the cicatricial tissue. After they have attained certain proportions they may remain without change indefinitely, though in rare cases they may undergo involution and disappear.

Alibert himself divided the keloids into two varieties, one true or spontaneous, developed without perceptible injury of the skin, and another false or spurious, produced on cicatricial tissue as the result of a trauma, to which Kaposi[2] added a third one, the hypertrophic scar.

The difference between the two kinds of keloid was denied by Welander, Schütz[3] and other authors, but it must be maintained for the reason that between the two kinds there are differences of a clinical and histologic order.

We[4] have already had occasion to report a case of multiple spontaneous keloid, one of which had assumed such enormous proportions as nearly to surround the

1. Alibert. Maladies de la Peau, Paris, 1810.
2. Kaposi, M.: Lehrbuch der Hautkrankheiten.
3. Schütz, J.: Ein Fall von sogenannten, wahren Keloid combinirt mit Narbenkeloid, Arch. f. Derm. und Syph., vol. xxix, No. 1.
4. Ravogli, A.: Multiples Spontankeloid, Monatshefte f. prakt. Derm., vol. xxii, p. 624.

Digitized by Google

whole neck. In that case we were unable to find any previous wound or scar which could have been considered the starting point of the keloid. Moreover, in the same man there was a large scar on his forehead from a severe trauma, which was as smooth and regular as it

Fig. 1.—Cicatricial keloid.

could be. We agree, therefore, with Berliner[5] and Max Joseph[6] on the necessity of maintaining the difference of the keloids as true or spontaneous, and in false or of a

5. Berliner, C.: Ueber spontane und Narbenkeloid, Monatshefte f. prakt. Derm., vol. xxxiv, p. 321.
6. Joseph, Max.: Ueber Keloide, Arch. f. Derm. und Syph., vol. xlix, Ref. Derm. Zeitschr., vol. vii, p. 291.

Digitized by Google

cicatricial order. The spontaneous ones are tumors of obscure or at least unknown causation, developing in the depth of the skin, without any apparent previous scar, while the cicatricial keloids have their origin on the base of scars, which are the result of injuries of any kind, more often of cauterizations and burns.

Both kinds of keloid, when they have attained a certain degree of development, remain unchanged for an indefinite time, show no tendency to involution, nor to any other degenerative process. They do not spread in metastatic forms, but when removed they are quickly reformed, assuming larger proportions. In the spontaneous keloid the relapse occurs in the form of a cicatricial keloid. In the cicatricial keloid, however, especially when produced on a burn, the relapse takes place with remarkable rapidity, but without any tendency to malignancy.

History.—The case to which I call your attention was in a colored man 38 years old, of an excellent physique, who had never suffered any disease, nor have we been able to detect signs of syphilis.

In an accident by fire he had his back badly burned, for which he did not have regular treatment, using only some vaselin to dress the wounds. The healing of the burned surface was slow, it having taken a few months to obtain complete cicatrization. As soon as the scar was formed a kind of tumor began to grow up, forming a hypertrophic growth, reaching the size and proportions shown in the illustration. While the cicatrix was taking on this hypertrophic development pain began to trouble the patient, which became much worse when the entire area was cicatrized.

Examination.—Present examination reveals several brownish-white areas on the ears, neck, hands and arms, which are the result of small burns. On his left forearm, on the flexion surface, is a superficial whitish scar, the result of the same burn, which covers a round area wider than a silver dollar. It contains in the center a group of five keloids, dark brown, shiny, elevated above the cicatrix, of the size of beans.

The most important lesions are on the neck and shoulders, where the burns had been most extensive (Fig. 1). On the back of the neck is a long keloid surrounding horizontally the inferior part of the neck, elevated for more than a half a centimeter above the regular cicatrix darkly pigmented with round, thick edges. From there two elongated keloids five to

Digitized by Google

six inches in length and three to four in width descend on the shoulders, intersecting both scapular regions. Dark brown in color, they have a polyhedral base seated on the scar, which, on the contrary, is thin, smooth, whitish and destitute of hair and pigment.

On the left side of the neck on a recent cicatrix is a group of keloids, five or six in number, the largest of the size of a cherry. Another keloid is seated under the left axilla on the lateral region of the chest. It is semilunar in shape, two inches in length and half an inch wide, dark brown in color, heavily pigmented, with round, thick edges, elevated above a thin and smooth scar.

Fig. 2.

The patient was suffering intense pains from the keloids on the shoulders. The pains were sudden and spasmodic, jerking and contracting, so that they caused restlessness and the impossibility of sleeping.

A piece of keloid was removed for histologic examination, to which I will briefly refer. The body of the tumor is formed by hard fibers of collagenous tissue, arranged in a horizontal direction resembling waves (Fig. 2). In the cicatricial keloid the fibers result of a granular mass in opposition to the clean and neat fibers, which are found in the spontaneous keloid. In our cicatricial keloid the papillary layer shows no papillæ;

Digitized by Google

it has been changed into a kind of granular connective tissue, in opposition to the spontaneous keloid, where the papillæ of the derma are well preserved, with little or no alterations. The stroma is made up of collagenous substance organized in thick connective bundles, entirely destitute of elastic fibers.

In our case of cicatricial keloid the epidermis appears to be much thicker and dense in the horny layer (Fig. 3). The Malpighi layer is also much thicker and is seen to be of large nucleated epidermic cells strongly

Fig. 3.

pigmented and densely packed without any order. There are no epidermic projections, because there are no papillæ nor interpapillary spaces. The epidermic cells are large and thick and of the kind found in the stratum granulosum, directly implanted on the connective tissues forming the stroma of the cicatricial keloid.

The epidermis in general shows only traces of the openings of the follicles or of sweat glands, and they are plugged up with thick epidermis. The collagenous tissue which, in the form of thick bundles, forms the stroma of the tumor, is contained in sepiments which

Digitized by Google

are the remnant of the cicatrix as shown by Max Joseph.[7] Between the sepiments in a horizontal direction lymphatic vessels and lymphatic spaces are very perceptible (Fig. 2, A), and on these are crowded thick concentric fibers of the connective tissue.

Some of these cells are greatly enlarged with large round nuclei (Fig. 4). The body of the cell is oval and is usually not well stained. These cells are in strict relation with the adventitia of the blood vessels, against which they are pressed and crowded.

Indeed, as is shown in Figure 5, the blood vessels are greatly increased in quantity, and can be followed in their ramifications in the whole structure of the tumor. They are, however, small and compressed in the midst of the mass of cells and of the thick connective bundles. The condition of the blood vessels varies somewhat according to the age of the keloid. In a recent keloid Crocker[8] found the blood vessels increased and dilated, surrounded by abundant cells. Unna[9] found that the branches or shears of a growing keloid contained enlarged blood vessels, running in a longitudinal direction, on which the bunches of collagenous fibers were densely crowded. The blood vessels are intimately connected with the growth of the keloid, which Unna considers to be a kind of perivascular tumor.

In old keloids (Fig. 6), however, the blood vessels, on account of the pressure of the cells and of the dense fibers, are compressed and reduced to strings, which can be scarcely recognized. In these tumors the cells can not be seen; they have been all changed into connective tissue fibers.

In our case, and with a larger power, elongated tumor cells are seen, and the nuclei so abundantly found in the structure of the keloid, appear to be corpuscles of the

7. Joseph, Max: Ueber Keloide mit mikroscopischen Demonstrationen, Berliner derm. Gesellschaft, Jan. 10, 1899.

8. Crocker, R.: Die Anatomie des Keloids in einem früheren Stadium, Brit. Med. Jour., 1886, quoted by Unna.

9. Unna, P. G.: Die Histopathologie der Hautkrankheiten, 1894. p. 844.

Digitized by Google

connective tissues, which have taken on an enormous development in number and size. The connective tissue corpuscles are more developed in the vicinity of the blood vessels. The specimens were stained with polychromatin, Unna Tanzer, and some, washed in 1 per cent. solution of carbonate of potassium and decolorized with glycerin ether mixture, Grübler. With 1/8 power they showed a layer of large violet cells, which resembled a great deal the Unna plasma cells. The presence of the plasma cells in the cicatricial keloid was also

Fig. 4.

found by Jadassohn.[10] He has seen plasma cells in nearly all cases of a chronic inflammatory process, but he never has found the same cells in cases of acute inflammation.

One of the important features in the structure of the cicatricial keloid is the nearly total absence of the elastic fibers. We have tried to show their presence by staining with orcein and then hydrochloric acid, with osmic acid and tannin, but we have failed to do so. In fact,

10. Jadassohn: Archiv f. Derm. und Syphilis, Supplementary No. 1, 1892. Ref. Monatshefte für prakt. Derm., vol. xv, 1892, p. 79.

Digitized by Google

Schütz[11] is of the opinion that in the keloid the elastic fibers either are lost on account of the pressure of the connective tissues, or they are subject to peculiar chemical degenerations, and in consequence can not be stained. Joseph, with the use of stains of Unna for elastin and elacin which consist of wasserblau and saffranin, was unable to find the presence of the elacin, and concluded that the elastic fibers are entirely destroyed. In our specimens we can see a few thin elastic fibers toward the cicatricial tissues. The elastic fibers are of the greatest importance for the functions of the derma. H. Müller[12] was the first to recognize the relationship between the connective tissue fibers and the elastic fibers in the intercellular substance. Kuskow[13] after a while tried to prove that the elastic fibers in their development are in strict relation with the nuclei of the cells. Blaschko[14] had already described a fine superficial net of elastic fibers which is directly under the rete Malpighi. Unna[15] connected all those discoveries and stated that fasciæ, cutaneous muscles and subepithelial net are the three points of insertion for the whole system of the elastic fibers of the skin. The elastic fibers have important functions to perform; they maintain the skin in its normal position, and when the skin is stretched bring it back to its normal condition. The elastic fibers in the pars papillaris are much stronger; they form a peculiar network, from which fine elastic fibers, as proved by Unna, extend to the rete Malpighi. They maintain the papillæ in their normal order and bring them back when they have been disturbed.

To all this we should add another function, which is

11. Schütz: Quoted by Max Joseph, Berliner derm. Gesellschaft, Ref. Derm. Zeitschr., 1899, p. 219.
12. Müller, H.: Bau der Molen. Verhand. d. phys. Med. Gesellsh. in Würzburg, 1860, x, p. 132; quoted by Ludwig Zenthoefer. Topographie des elastischen Gewebes, 1892, Derm. Studien von Dr. P. G. Unna.
13. Kuskow: Archiv. f. micr. Anat., xxx, 1887.
14. Blaschko: Monatshefte f. prakt. Derm., v, 1886.
15. Unna, P. G.: Monatshefte f. prakt. Derm., Supplementary No. 1, 1887.

Digitized by Google

to maintain the connective tissues in their normal position, and to limit their growth. In fact, Iwanow[16] has recently examined histologically the white atrophic cicatricial spots around the follicles of the skin in individuals suffering with acne. He has found that the alterations mostly consisted in the disappearance of the elastic fibers of the corium which normally surround the sebaceous glands and the hair follicles, as a result of the chronic inflammation of the glands. To this destruction of the elastic fibers he refers the frequency of the

Fig. 5.

white spots and of the multiple keloids which have their origin in the acne cicatrix. With his observations he renders much more plausible the opinion of Goldman, that the white spots are the forerunners of the keloid, and that the keloid is the result of the disappearance of the elastic fibers.

According to our observations, we can say that the growth of the connective tissues is greatly increased by the loss of the elastic fibers. It seems that the office of

16. Iwanow, W.: Russ. Jour. f. Haut und Ven. Krank., No. 4, 1903; Ref. Derm. Zeitsh., 1904, No. 2, p. 113.

Digitized by Google

these fibers is that of maintaining the connective tissues up to a certain degree of development. The elastic fibers, when destroyed, are never formed again.

In the structure of the keloid all traces of glands, hair follicles, cutaneous muscles are lacking.

ETIOLOGY.

From the above-referred observations it clearly appears that the destruction or the degeneration of the elastic fibers is the predisposing factor for the production of the keloid. As a determining cause, many have thought of a peculiar infectious pathogenic cause. Balzer and Leroy[17] showed a case of a large keloid of the presternal region of twelve years standing, which had its origin in a small wound made with a penknife. On the same occasion Darier expressed his opinion that the cause of the keloid ought to be found in a local infection. Hallopeau, however, found that the keloid was an affection of embryonal origin. The idea of a local infection in the keloid is also shown by Marics and Fournier,[18] who deny the special predisposition, maintaining, however, an inclination to keloids of the skin of the negroes.

Indeed, the statement of Unna, that all true keloids must have had their origin from a scratch or from a patch of seborrheic eczema, would tend to strengthen the possible infectious origin. Joseph referred to a case of a keloid developed on a small wound caused by a piece of glass. Ehlers[19] showed to the Danish Dermatological Society a boy six years old with five keloids, each one on a vaccination scar. An identical case of keloids developed on the cicatrix of the vaccination was shown by Besnier, and has been made in maulage, which is kept in the museum of the hospital, St. Louis.

---

17. Balzer and Leroy: Societé de Derm. und Syphil., June 9, 1898; Ref. Derm. Zeitschr., vol. v, p. 834.
18. Fournier: Journal des Malad. Cut. et Syph., November, 1898, No. 11, p. 671.
19. Ehlers: Dan. Dermat. Gesellschaft, Sitz, May 3, 1899; Ref. Derm. Zeitschr, vol. vi, p. 755.

Digitized by Google

L. Nielsen is of the opinion that keloid has its origin in a local infection, and relapses after its removal occur on account of a focus of infection remaining in the surrounding tissues.

Thiebierge[20] also favored the microbic origin of the keloid. The same views are entertained by Leredde,[21] who believes that in the acne pustules, which have given origin to the keloidal tumor, there were probably parasites capable of producing the hypertrophy of the tissues.

Fig. 6.

In our studies with the keloids we have never met with any form which suggested to us the idea of a microbic origin. We are rather inclined to maintain that the lack of the elastic fibers is of great enough importance to explain the abnormal development of the connective tissues. If the keloid is developed on a cicatrix, it is for the simple reason that in the cicatrix the elastic fibers have been destroyed, or have undergone degeneration.

20. Thiebierge, G.: Maladies de la Peau, Paris, 1895.
21. Leredde: Revue Pratique des Mal. Cutan. Syphil. and Vener., March, 1904, p. 77.

Digitized by Google

TREATMENT.

Nearly every one who has removed keloids has had the disappointment of seeing, sooner or later, the relapse of the tumor. In consequence, the keloid has been referred to the class of those affections called by the ancients noli me tangere.

Leredde, however, on the authority of Darier, Tillaux, Sabourand and others, maintains that a keloid can be removed and relapse will not follow, if it is completely removed and healed up by first intention. But anyhow he advises not to take the chances if the keloid, in case of relapse, should produce more grave deformity.

In our case, on account of the locality and of the extension of the keloids, no surgical operation could find any indication. The patient was suffering excruciating pains, and so we have resorted to simple medication. A salve containing

℞. Resorcin ..... ʒss
Acid. salicyl. ..... gr. xx
Ol. olivæ q. s.
Lanolin .... ℥i

spread on muslin, was applied. This afforded for the first three weeks great relief, but after awhile the keloids began to get inflamed, the epidermis to excoriate and ooze some serum, so that it was necessary to discontinue its use. Then we began to dust the surface with boracic acid, 5 parts in 100 parts of starch powder. Under these applications the irritation subsided, the epidermis was formed again and the pains and the tenderness entirely disappeared. It seems that the keloids of the neck and shoulders had undergone a process of regressive metamorphosis, as they were reduced by more than one-third of their former size.

Dr. Evans, on taking charge of the service, began to treat the case with the *x*-rays, which were applied for a few minutes two or three times per week. The result has been rather satisfactory, the keloid tumors have become much harder to the touch, they have reached nearly the

Digitized by Google

level of the skin, and the pains and the tenderness have entirely left.

DISCUSSION.

Dr. W. S. Gottheil, New York City—I agree with Dr. Ravogli's paper thoroughly save in one particular. I rather hold with those who believe that every case of keloid is cicatricial in its origin, and that there is no such thing as spontaneous keloid. The facts that the so-called idiopathic keloid occurs almost always on the back or sternum, where acne and similar lesions are frequent, or on the face, hands or arms, which are especially exposed to traumatisms, is a strong point in favor of this view. The very smallest lesion may be the starting point of a large, new growth. I have failed also to find any microscopic differences between the two varieties. It has been advised to treat keloid in the same way as a malignant new growth, and to make a wide excision. Good results have been claimed, but I have not seen any; all the cases that I have operated on have relapsed. Actinotherapy has given no results at all in my hands. On the whole, I do not think that we have made any progress in the treatment of the affection and I think that the best service that we can do for most of these patients is to persuade them to leave their keloids alone.

Dr. D. W. Montgomery, San Francisco—I had a case of spontaneous keloid in a negro. It was quite symmetrical on the shoulders, back and chest. I took out one of the keloids and found the papillæ obliterated, just as in true keloid. I instituted some treatment which did not do any good, but the microscopic picture was the same as in so-called true keloid.

Dr. J. F. Wallis, Philadelphia—Speaking of vaccination, when associated by the Bureau of Health of Philadelphia, I frequently noticed healing delayed in vaccination, sometimes for months, and instead of the natural cicatrix we would find a soft, jelly-like substance in the tissue remaining livid in color for a considerable time and often breaking down on the slightest pressure or irritation. These cases eventually recovered, but with the scar livid and prominent. I have wondered whether tuberculosis was responsible for this peculiar condition inasmuch as all cases gave a tubercular history.

Dr. H. C. Baum, Syracuse, N. Y.—I remember one early case, a large keloid growth occurring on the scar of lupus vulgaris. Hans von Hebra recommended thiosinamin injections for recent keloids. In this particular case a keloid had also developed on the back of the neck, where the patient had burned herself with a curling-iron and recovery was followed by a large olive-shaped keloidal tumor. Thiosinamin injections flattened down the old keloid on the lupus cicatrix, but did not remove them. It did remove the recent keloid, which rather confirmed Hans von Hebra's employment of it. I felt quite fortified then

Digitized by Google

for handling keloid, for if the injections controlled recent keloids, they should prevent recurrence after removal. Another case came to me with a typical keloid over the sternum, which I excised, following that with thiosinamin injections, the value of which ought to be proven there. The result was that not only the original keloid returned, but a keloid tumor at the site of each puncture of the needle.

Dr. Mortimer A. Moses, New York City—There is one point in the etiology of keloid that I have not heard mentioned, that is the production of keloid on previous lesions. I saw one case of keloid developed on the site of a maculopapular syphilitic eruption in a young woman. I do not think that the differences between the so-called true and false keloid are sufficiently marked to enable one to differentiate between the two from the histologic picture. In fact, I think that they are one and the same disease, only that in the "true" keloid the traumatism has not been evident. In regard to treatment, I have seen two cases benefited by the use of thiosinamin injections, and Pernet of London has suggested using a 15 per cent solution, but instead of dissolving it in alcohol, using a mixture of equal parts of glycerin and water. This gives less pain than an alcoholic solution.

Dr. M. L. Heidingsfeld, Cincinnati—My histologic experience leads me to concur with Drs. Gottheil and Moses, that a differential diagnosis between false and true keloid can not be made. I am loath to believe that the disappearance of elastic fibers is of any etiologic significance. Their absence is due to pressure atrophy, the same as we find in many infiltrating forms of cutaneous new growths, and is an effect and not a cause. The mere absence of elastic fibers does not produce keloid, as is abundantly evidenced by lines of pregnancy, stria atrophica and similar lesions, where there is a complete absence of elastic fibers, and the lesions are atrophic and distinctly depressed.

Dr. A. Ravogli—Joseph first maintained that false and true keloid are the same thing, then later he found that it is a necessity for the pathology and for the treatment to maintain a difference between the two keloids. I find that in true keloids it is sometimes very difficult to find the first scar which has produced a keloid. However, when we see a keloid on a cicatrix we call it a cicatricial keloid, which, on account of the infiltration and of the running of the keloid, shows some differences in its histopathologic structure. I think the maintenance of a distinction between cicatricial and spontaneus keloid is interesting and useful for the pathology and for history of this disease. As to thiosinamin, I note that Hebra used it a great deal, but at present it has been nearly abandoned. Recently Peré resorted to interstitial injections of 5 per cent. solution of creosotal in order to produce reabsorption of the

Digitized by Google

tumor, but the results have been rather poor, and instead of seeing a diminution of the keloid they have seen it take larger proportions. I can not state what the relation is between tuberculosis and keloid. In the cases I have had occasion to observe I have found the patients in good physical condition, with no signs of tuberculosis. It may be that some cases have shown tuberculosis, but I think that is more of a coincidence than anything to do with the existence of a keloid. So I can say also with syphilis. I see a great deal of syphilis, but very rarely have I seen a case of keloid come on a syphilitic lesion. In regard to the elastic fibers, I believe they are lost only in those affections where we have a great deal of hypertrophy of the collagenous tissues, for instance, we often find in fibroma of the skin that very little elastic fibers remain. I believe the lack of elastic fibers is the secret of the formation of the keloid.

Digitized by Google

HYPERIDROSIS PEDUM AND ITS TREATMENT BY BATHS OF PERMANGANATE OF POTASH.

LUDWIG WEISS, M.D.

Attending Physician to the Skin and Genito-Urinary Service of the German Poliklinik; Consulting Dermatologist Hebrew Orphan Asylum.

NEW YORK CITY.

DEFINITION.

By hyperidrosis we understand an excessive production of sweat due primarily to anomalies of the nerve centers influencing the sweat secretion; and secondarily, to circulatory disturbances depending on the altered state of the vasomotor nerves.

The definition tries to embrace the two main central causes of overactivity of the sudoriparous glands. It will be shown later that there are also peripheral causes for hyperidrosis. It is impossible to determine how much the other follicular secretions—those of the sebaceous glands and the hair follicles—contribute to the volume of exuded material. We have no reliable method of separating both kinds of secretions from each other. Already Meissner[1] maintained that the coil glands serve as fatty lubricators, and more recently Unna[2] tried to prove that the sebaceous glands contribute only in a small degree to the function of lubricating the skin with fatty material, and that the coil glands mainly perform this office. The secretion of the sebaceous glands, he asserts, serve mostly to grease the hairs within

1. Jahresb. f. Anat. u. Phys., 1856, p. 285.
2. Handbuch d. Spec. Pathol. u. Ther., vol. xiv, p. 92.

Digitized by Google

their follicles. Kaposi,[3], Ziemssen,[4], Torok,[5] and others, while not denying the fact that the coil glands contain fat cells, yet uphold the theory dear to us all, that the coil glands are the main sources of the sweat.

PHYSIOLOGY OF PERSPIRATION.

Perspiration is a secretory and excretory process of the system. It is to be regarded as a supplementary respiration through the skin and, if not paramount to the lung respiration, yet in certain co-ordination to it. When the perspiration becomes condensed because it is secreted too voluminously to be evaporated speedily, we call it sweat, and the process of doing so "sweating." This is a more correct term to express fluid accumulation on the skin than the word "perspiration," which really means only skin breathing by evaporation. But its usage, although not correct, is sanctioned by custom.

The net-work of capillaries of the skin is the origin of a perpetual exhaling process, an evaporation of moisture which takes place almost unnoticed and unfelt, and called, therefore, *perspiratio insensibilis*. It consists of a carbonic dioxid gas as an end-product of oxygen burning-up, which takes place in the capillaries of the lungs as well as in those of the skin.

The so-called *materia perspiratoria* as it appears on the skin, is derived mainly from the coil glands, and in a minor part it is the result of a transudation from the papillary vessels and intracellular sap-channels of the epidermis. Both components of this excretion appear in the mouth of the sweat-pore, as sweat. The sweat, therefore, is a complex mixture of different origin and sources, and presupposes a healthy, well-working, follicular apparatus and nerve influence. The sweat secretion stands mainly under the influence of the central

3. Hautkr. III, Aufl., p. 140.
4. Vol. xiv, p. 117.
5. Eine Erklarung d. Krit. Schweisses, Pester Med.-Chir. Presse, 1901, No. 29.

Digitized by Google

nervous system; in a minor degree it depends from the circulation and the blood pressure in the capillaries, which again is influenced by the impulses which govern the state of the vasomotor nerves. This influence may be of central (psychic, sensory, etc) or peripheral origin. (Irritation of different kinds, caloric influences, etc.)

For instance, I have repeatedly noticed excessive sweating in patients treated with electricity. That reflex irritation influences the sweat secretion is shown also by the fact that even an amputated limb could be made to sweat when irritated by electricity. This goes to show that the vasomotor nerves carry also sweat-secretory filaments. Coyne[6] has found peripheral ganglia of the sweat glands. The coil glands, therefore, or the glomeruli of which they consist, must be looked on as so many minute central organs open to central as well as to peripheral influences. Luchsinger[7] thinks that the sweat nerves are solely of sympathetic origin. Adamkiewitz[8] attributes to them a spinal origin also. Strange and unexplained, however, for the present are the contradictory phenomena of excessive as well as retarded sweating, due to the identical influences. Parts affected with paralysis may show sweating, as do also those parts irritated or excited. For instance, facial paralysis and facial neuralgia. Vulpian[9] explains this by assuming that, beside the excito-sudoral filaments of the sympathicus, there are also inhibitory filaments running alongside, which influence sweat secretion. This would then represent the central and, by the way, the most common influence, while the fine network of nerves running from the ganglia to the glomeruli of the coil glands would represent the stations or entrance for the peripheral influences governing the different enunciations of sweat secretions. That cerebral centers for the sweat secretion can also be assumed to

6. Compt. rend., 1878, vol. lxxxvi, p. 276.
7. Archiv f. ges. Phys., 1878, xviii, p. 494.
8. Die Secr. d. Schweisses, Berlin, 1878.
9. Cited by Geber in Ziemssen's Handb. d. Sp., Path., a. Ther., vol. xiv, p. 276.

Digitized by Google

exist has been shown by Bloch[10] ("Unilateral Perspiration After Fracture of Temporal Bone"); Bouveret[11] ("Gumma of the Brain"), and Adamkiewitz[12] ("Ataxia of the Arms Due to Cortical Lesions").

Hyperidrosis has been reported to exist where depressions of the brain prevail. In the comatose conditions of acute infectious diseases; in systemic intoxications, like chronic lead poisoning; in the depressive state of acute alcoholism, in calculous and toxic nephritis. From these idiopathic hyperidroses, we may distinguish the symptomatic ones: The critical sweats in pneumonia and typhoid; the profuse acid perspiration in rheumatism, the colliquative sweat in phthisis and in pyemia, hysteria, neurasthenia, anxiety, sometimes cause general hyperidrosis due probably to spinal irritation.

Peripheral influences, like too warm dressing, hot baths, overexercise, hot beverages, cause heat accumulation. It seems that in these instances the capillary hyperemia stimulates the coil glands to a more active secretion.

Very little is known about the structural changes of the coil glands in connection with hyperidrosis. According to Mracek,[13] only in one instance has such an examination been made by Virchow, who found fatty degeneration of the epithelium of the coil glands in a phthisical patient.

Beside general and local, unilateral and crossed hyperidrosis, there are also qualitative changes of the sweat secretion. It may contain products of metabolism in more than the usual minimal proportions. In anuria, the skin has been found covered with a dew-like film of urea crystals. At times the fatty acids, salts and other organic and inorganic substances had been found in disproportionately large quantities. Such a perspiration will already be secreted with an odor: osmidrosis or

10. Thése de Paris, 1880.
11. Des Sueurs Morbides, Thése de Paris, 1889.
12. Ziemssen: Ibid., 277.
13. Handb. d. Hautkr., Wien., 1901, vol. i, p. 293.

Digitized by Google

odorous sweat. It differs from bromidrosis, where the disagreeable odor is due to a decomposition of the sweat after it had been secreted. Other qualitative anomalies of sweat secretion are chromidrosis, hematoidrosis, etc.

The prototype of bromidrosis is the excessive perspiration of the feet. This underestimated ailment may be the source of the greatest unhappiness to its bearer. The penetrant odor, in spite of the most scrupulous cleanliness, remains insuppressible. It makes the bearer a nuisance to his surroundings, stamps him socially impossible, encroaches on his earning and producing capacity, and transforms the sunniest disposition into a recluse—or to an obtrusive individual.

ETIOLOGY.

The etiology of hyperidrosis pedum is not clear in every case. It may be inherited. Wilson[14] reports a case in a gentleman whose mother was similarly affected; his two brothers were similarly troubled, but his two sisters escaped it. In other cases faulty circulation, due either to active or passive congestion in the capillaries, is the cause. Patients of the latter class will exhibit the symptoms of chloranemia, cold hands and feet, lividity of the toes, fingers and other vasomotor disturbances. In another series of cases an overactivity of the coil glands seemed to be the causative factor. Sometimes the etiology is entirely wanting.

CAUSES.

The causes of excessive perspiration of the feet coincide, as far as pathologic changes are concerned, with the etiology. But there exist contributive external causes which, to a great extent, act as an excitant to the loathsome ailment. Foremost among them is the absolutely irrational footgear of civilized beings. Those who will live in centuries yet to come, where fashion will, it is expected, be subordinate to hygiene, will look

14. Diseases of the Skin, p. 204.

Digitized by Google

on some mistakes of our environment and habiliments, especially footwear, in amazement and pity.

To mention a few instances: The dry and dust-laden heating of our houses by our antediluvian furnaces, so eminently favorable to catarrhal diseases; the enveloping of our heads with starched felt, called hats, and causing more or less developed "full-moons" in seven-eights of men; the squeezing in of the thorax and epigastrium of our women into an armored cuirass, called corset, interfering with respiration and causing the well-known corset furrow or groove of the liver; and last but not least, the encasing of our feet into a water and air-tight, narrow, unyielding compartment, called a shoe, causing the finest corns, bunions, calosities, a selection of malimposed and superimposed toes, and a genuine sweatbath, even in those not inclined to perspire freely. This picture is not overdrawn. But the remedy, simple as it is, will not come to pass so soon. The ancients have shown us what practical footgear is. Their sandals permitted evaporation of their foot perspiration—we civilized beings permit it to be retained. The Japanese gather the contents of their nose secretion in paper handkerchiefs, to be thrown away after use. We of the civilized ones, carefully fold the bacteria-teeming linen handkerchief, preserving its contagious treasury in our pockets and endanger the laundry woman next Monday. At the same time we disseminate, broadcast, instructions on how to avoid infection. The Chinese wear a half-open, permeable, porous shoe; so do the Japanese; and on inquiry I was told that foot-sweats are infrequent with them. Look at a Chinaman. The cleanest part of his economy is his feet, with the snow-white stocking visible and clean.

SYMPTOMS.

The symptoms of hyperidrosis of the feet vary with the intensity of the affection. In milder cases the feet are moist, dewy and overheated. In severe cases the contact surfaces, the tips and the furrows between the

Digitized by Google

backward-bended toes and soles become fissured and painful. In the severest cases the soles look parboiled, whitish, with red inflammatory areas between them; an exceedingly painful condition.

Moderate perspiration of the feet is a normal condition. It assumes a pathologic aspect only when the sweat secretion becomes augmented and when this increased secretion is not evaporated quickly enough, and this it can not do with our footgear. The sweat, as such, even when secreted in increased quantities, is in most cases devoid of any odor. This is plainly evidenced by hyperidrosis of the palms of the hands, where there are only sweat and no sebaceous glands present. This surface produces, so to say, the purest and unadulterated perspiration. Being uncovered, evaporation from the palms is also unhampered. On the contrary, there are many points which make the feet predestined to fetid perspiration. Foremost is the increased and pent-up sweat secretion, which undeniably contains fat. Contributive to this is the admixture of sebaceous material from the sebaceous glands so abundantly present on the foot; third, the decomposition of both secretions through moisture and warmth; fourth, the almost absolute lack of evaporation; fifth, the admixture of macerated, softened epidermis, débris; sixth, the persistent motion of the feet, acting as a peripheral stimulant to the sudoriferous glands; seventh, the condensation of vapor—with which the atmosphere surrounding the feet is so highly charged—into fluid perspiration, and finally retarded circulation in the compressed foot and deficient oxygenation of the recurrent blood. Lesser,[15] in Leipsic, has especially drawn our attention to the coincidence of sweating feet and talipes, already emphasized by Trendelenburg,[16] that talipes, even in the incipient stage, predisposes to enlargement of the small cutaneous veins, which in turn act as a stimulant to the secreting epithel-

15. Schweissfuss u. Platfuss., Deutsche med. Woch., 1893, No. 44, p. 1070.
16. Verhandl. d. Deutsch. Ges. f. Chir., April, 1892, i, p. 52.

Digitized by Google

ium of the coil glands. As soon as the varicosity becomes pronounced, atrophy of the skin and of the coil glands takes place. The hypothesis seems to me a feasible one. I have found analogous conditions in cases of local hyperidrosis of the nose tip, that is, of the skin covering the cartilaginous part. In all such cases there was present a strumous condition, manifesting itself by a thick, quite enlarged organ due to venous stasis, and with abundant sweat secretion. Here also increased amount of carbonic dioxid of the blood seems to generate excessive perspiration.

TREATMENT.

While we may expect some results from systemic treatment in general or unilateral hyperidrosis, by trying to influence the underlying causes, and by the administration, on general principles, of atropin sulphate 1/100 of a grain, once or twice a day, or by agaricin ⅛ to 1 grain t. i. d., and a host of other mostly ineffective remedies, we are pretty powerless with general treatment as regards local hyperidrosis.

In excessive perspiration of the axillæ, palm of hands, inguinal folds, but especially in that of the feet, local remedies only are promising of results, which in most cases are only temporary ones. Like in all intractable affections, the number of so-called "sure cures" is in inverse ratio to their effectiveness. The local treatment of hyperidrosis pedum could be divided into a feasible and unfeasible mode of treatment. It is a seemingly strange division, but a rather apt one. The question is, shall the reign of irrational and unhygienic footgear remain supreme forever, or not? If the former is the case —and I fear it will be—let us abdicate and be content to attain only temporary cures. Permanent cures will only be possible when our footgear becomes rational, natural and hygienic, as was that of the ancients. As this is not intended to be a symposium on shoes, the intricacies of which the author professes neither to understand nor to exploit, these rudimentary remarks should only

Digitized by Google

give the hint that a rational treatment of excessive foot-sweat should of necessity begin with a reform of the useful commodity of footwear. But, in spite of all the disadvantages, I do not hope for a reform, and under the circumstances we will have to confine ourselves to the second or feasible part of interference, i. e., to treat the perspiring foot as best we can, with the irrational footwear as an impediment.

Before enumerating, partly at least, the different external remedies, I will dwell, cursorily only, on the old question: Is there reason to fear suppression, and should excessive perspiration of the feet be treated? From time immemorial, it was held that suppression of the cutaneous exhalation causes the accumulation of deleterious waste products and manifold illnesses. The experiments of shaving and varnishing guinea-pigs and rabbits proved deleterious to these animals. In larger animals whose evaporative surface and weight are more proportionate, the consequences are less stormy; but urea in the urine was increased by this experiment. The tarred patients of Hebra did not show any pathologic symptoms besides those of absorption of tar products through the lungs and through the skin. Senator's varnished patients did not exhibit any symptoms at all. To me it seems that Nature, having provided the soles with about 2,600 (Zulch) sweat glands to the square inch against 400 on other regions, and about 640 on the dorsum of the foot up to 1,111 on the palm of the hand (Kölliker), has clearly shown her intention of utilizing this vast apparatus for the purpose of excretion. We find that the skin exhales from 3 to 30 grams of carbon dioxid gas and excretes about (Seguin) 917 grams= 1/64 of the body weight—a day of fluid secretion. The urea is present only in very small quantities and with other organic and inorganic salts, the sweat is by no means an indifferent product. Different opinions to the contrary, it is not a simple transudation, but a real secretion, and the coil glands, therefore, must be regarded as

Digitized by Google

excretory organs also. It is therefore obvious that the old contention about the danger of suppresion of foot-sweats has some foundation; but the fabulous tales of the dire consequences are the results of misconstrued humoral-pathologic doctrines. Already Barensprung[17] and Hebra[18] have held that suppressed perspiration is not the cause but the consequence of some illness, i. e., the anemia resulting from it. The thousands of other sweat glands and the kidneys will be able to cope with the excretory demand of the system. Hyperidrosis must be regarded as a pathologic overactivity, and as such may be combated with impunity, as we do seborrhea or polyuria. Unfortunately, we are as yet unable to cure excessive perspiration of the feet permanently, and therefore, those who do feel inclined to dread suppression need not be uneasy.

The external or local treatment is the only available means then, in hyperidrosis pedum. The number of remedies is legion, and they are employed mainly for their exsiccating influence on the epidermis. I may be permitted to forego a classification and enumeration of them. I will only casually mention alcoholic lotions of resorcin, salicylic acid, tanin (1 in 200), also bichlorid (1 in 400 water), Burow's solution, boric acid, alum, soda solutions, vinegar water, naphthol (10 to 200) which may benefit mild cases. In severe cases more powerful remedies are employed. For the fissures, a 5 to 10 per cent. solution of nitrate of silver application is used. Kuster[19] recommended salicyclic acid as a lotion and as a dusting powder. Heussner[20] recommends balsam of Peru 1.0, acid formicum 5.0, chloralhydrate 5.0, alcohol 100.0, to be applied with cotton. He thinks that the formic acid acts as an inhibitory agent, and that the nascent formic and other rancid acids contained in profuse perspiration, when eliminated too quickly, permit the sweat to become of alkalin reaction. The bacterium

17 and 18. See their text-books.
19. Allg. med. Centralzeitung, 1876, No. 82.
20. Deut. med. Woch., 1895, p. 730.

Digitized by Google

found by Thin,[21] called bacterium fetidum, which bears strong resemblance to the bacterium coli commune, will, in patients not scrupulously clean, change the urea in the sweat into carbonate of ammonia, thus rendering the sweat alkalin and easily decomposed. This formic acid is also the active principle of chloral employed in 5 per cent. solution in alcohol. It develops hydrochloric and trichloracetic acid and splits into chloroform and formic acid. On this principle are based the most patent remedies for this ailment. Recently formalin and tannoform have been recommended on the same principle. The former is a very serviceable but painful remedy, especially when fissures are present. Its fumes irritate the mucous membranes. I would not recommend its use in a stronger than a 5 per cent. solution. Fredrique,[22] Adler,[23] Richter[24] and others recommended tartaric acid. It is used as a spray in a 10 to 20 per cent. strength; after evaporation a fine, white, dust-like deposit remains on the skin. It is also used as a dusting powder.

The best known among these remedies is salicylic acid. It was the official remedy for sweating feet in the German army. The formula is: Acid salicylici, 3.0; amyli, 10.0; talci, 87.0. Kobert[25] recommends: Talci, 100.0; aluminis usti, 20.0, and praises this combination as dehydrating, astringent and devoid of danger, in contrast to the much-used chromic acid, which is employed in 5 per cent. solutions. The soles are painted with it on three consecutive days, and after drying a dusting powder is applied. In one or two weeks the epidermis becomes detached in large horny layers. It leaves a very sensitive, thin and soft new skin underneath. It is a good but very dangerous remedy. Its absorption in form of a chromic salt through the blood may cause nephritis, hydrops and different ulcerations. Ko-

21. Proceedings of the Royal Society, 1880.
22. Annal. de la Soc. Med. de Gand., 1886, No. 9.
23. Prager, med. Woch., 1896, p. 434.
24. Allg. med. Centralzeitung, 1897, No. 73.
25. Fortschr. d. Med., 1890, viii, p. 36.

Digitized by Google

bert would admit its use only in war, when an efficient infantry is imperative; else, other less dangerous remedies should be used.

As to the well-known Hebra's cure, it consists in the application of his diachylon ointment, spread on coarse linen and renewed every twenty four hours. This is kept up for two weeks. Soon the epidermis comes off in large yellowish layers. The new epidermis then appears white, soft but somewhat sensitive. The disadvantages of this method are: that while it may be employed with the patient about, yet, to be successful, it is better for him to enjoin rest in bed. Beside, it is an unclean and uncomfortable method and ill-adapted to our climate.

The treatment I advocate is devoid of all dangers and lacks the unpleasantness of the remedies just enumerated. It is not a new remedy; no unutterable synthetic formula gives it the dubious glory of supplying a long-felt want. It is an unassuming friend, our old honest permanganate of potash. Neither is its employment in regard to foot-sweats new. All I claim as original with me is the manner and its concentration in which I employ it. It is applicable in every stage of the disease, and fissures between the toes are no contraindication to its use. The theory of its employment is a threefold one. First, its facility to give up its oxygen in the presence of organic matter; second, its precipitation on the skin as manganese dioxid in a layer proportionate to its concentration; third, the exsiccating and in stronger percentages its keratotic action on the epidermis. It imbibes itself in the epidermis cells, percolates through them, acts as an astringent to the papillary vessels and is taken up by the mouths of the pores and follicles. In his histologic researches on reductive substances used in skin affections, like tar, anthrarobin, etc., Lutato[26] has shown, as did Unna,[27] with ichthyol and resorcin;

26. Monatsh. f. Pract. Dermat., 1904, vol. xxxviii, No. 6, p. 257.
27. Dermatol. Studien, 1886.

Digitized by Google

Buck[28] with pyrogallol and Hodara[29] with salicylic acid and chrysarobin, that they act differently according to concentration, mode and durance of application, and cause artificial reduction of living tissues. Mild percentages cause a thickening and hornification of the epidermis, inhibit the growth of prickle cells, narrow and close the lymph channels, and act as astringent to the papillary vessels. In stronger concentration the epidermis becomes macerated, the prickle layer undergoes disintegration and softening of the collagen tissue takes place. To avoid this latter eventuality so common with chromic acid, there is, in my opinion, no better substance than permanganate of potash. Its action is not strong enough to macerate the skin, but it will harden and toughen it without rendering the underlying new skin congested and sensitive.

Permanganate of potash, diluted solutions of which are of rose color, stain the skin a yellow brown; concentrated solutions, which are of a deep violet-red color, will stain the skin a deep brown. In its highest concentration (6 per cent.) it stains almost ebony color. This color scale, although not exact, serves as a good practical index for estimating the strength of the solutions. It is interesting to note the way the different parts of the immersed foot stain. The horny substances, nails and corns take the stain almost at once and hold it to the last. The lunulæ of the nails remain unstained for a few days, making a rather striking appearance of color differentiation. Next come the callous places, then the heels, ankles and dorsum of the leg and the interphalangeal spaces. At those places on which the body weight rests and on those which are in apposition to each other and to the shoe, the stain becomes effaced until the next bath, but finally retains the stain, especially when the highest concentrations are used. These places are the skin over the achilles tendon, the flexor parts of the

28. Monatsh. f. Pract. Dermat., 1895, vol. xxi. No. 12.
29. Ibid., 1896, vol. xxiii. No. 3, and 1900, vol. xxx. No. 2.

Digitized by Google

toes and the cushion-shaped metatarsal region. Finally, after a few days' use of the stronger solutions, the whole foot becomes stained and takes on a deep mahogany and the nails an almost ebony color. The treatment begins with taking a footbath before retiring. We start with a warm footbath of borax water and soap, followed by a thorough scrubbing and careful drying. With a cotton pledget soaked in benzine the foot is now thoroughly cleansed from all epithelial débris. No more cleansing footbaths are taken until cessation of treatment.

These preliminaries finished, we immediately commence treatment. Irrespective of the severity of the case we start with a 1 per cent. solution or 10 grams to 1,000, equal to 2 drams to quart of water, temperature 104 degrees. It is best to use a china wash bowl and preferably a separate one for each foot. The fluid should be ankle-deep; duration of immersion fifteen minutes. This done, the foot is placed on some old toweling to drain and not rubbed off, but left to dry, which is accomplished in a remarkably short time. The patient now goes to bed, covering his feet only lightly. A pleasant feeling of dryness is felt in contrast to the accustomed damp sensation. Next morning the whole foot is slightly dusted with the following powder: Potasse permanganatis, 13.0; aluminis, 1.0; talci, 50.0; zinci oxydi, lapidis calaminaris, aa 18.0. The interphalangeal spaces must also be dusted and separated with absorbent cotton. Daily change of stockings and shoes is desirable.

The next evening the permanganate bath is again taken. We will soon notice a scum floating on the surface. This is due to the oxydation of organic matter which has accumulated since the last footbath. As the cure progresses this scum will be noticed to become less, finally appearing only on the surface of the red fluid as a faint light streak of flotsam. After fifteen minutes the foot is taken out, allowed to dry and the patient goes to bed. The baths are thus taken for a fortnight or three

Digitized by Google

weeks in increased strength. The average duration of a treatment is two weeks. Most conspicuous and encouraging to the patient is the immediate absence of odor and sensation of comfort as the dryness of the feet and interphalangeal spaces become established. Another noteworthy and pleasing effect of the permanganate baths consists in the painless healing of the interdigital fissures and inflammation around the nailbed caused by pressure of superimposed toes. The disappearance of these concomitant and unpleasant symptoms, which add so much to the discomfort of the patient as to make it noticeable in his gait and distressed facial expression, turns the patient a most willing helpmate to attain a cure. After the third bath the strength of the solution is increased to 2 per cent., i. e., 20 grams to 1,000, equal to 4 drams to one quart of water for each bath. It should be rather warm now, as the permanganate dissolves easier. In the beginning of the second week the footbaths should be taken, 30 grams to 1,000, i. e., one ounce to a quart of very warm—as hot as can be borne—water. The last three baths should be taken full strength: 60 grams to 1,000 or two ounces to a quart of water, temperature as before. As the presence of alum enhances the liberation of oxygen, one dram of it may be added to the permanganate.

I will add here that neither the weak, medium nor saturated solutions cause the slightest pain, burning or caustic sensation. The fissures by this time have filled up with a fine precipitate of manganese dioxid, under the cover of which healing has taken place. The foot, which until now has been stained a dark mahogany color, will assume under the influence of this concentrated solution an almost jetblack hue. The precipitation on the surface of the skin is now so copious that it looks as if varnished, and accordingly the drying takes place almost immediately as the foot is taken out of the bath. In a week after cessation of treatment, the skin commences to desquamate slightly; first on the dorsum,

Digitized by Google

then in the interdigital spaces, and finally on the soles and heels; the nails, as I said before, retaining the stain for months. It may be mentioned as an unintended but welcome consequence that the stained corns become friable and are easily removed.

By this time the sweating has ceased, the cotton between the interdigits showing only the slightest perceptible trace of dampness but no fluid accumulation. The last-named incident serves as a criterion for the cessation of treatment. In every other place the fluid perspiration has already ceased days before the interdigital spaces have become dry. When this latter state is reached, cure has been obtained and treatment may be abandoned. The dusting is now to be continued morning and evening, and pledgets of cotton be worn only through the daytime. It is advisable to wear blotting-paper betwen sole and shoe and have it changed daily. Every drug store sells some kind or other of cut and shaped paper soles, for a trifle. Low-cut shoes and thin hose are imperative as long as weather permits.

The foot is now left alone. Some tightness of the skin is now felt, and the pleasing sensation of dryness, ability to walk unmolested, the grateful impression of a dry, odorless stocking when undressing, a foot devoid of dampness and malodorous emanation, a pleasing sense of cleanliness which could not be obtained by the most vigorous washing, make the patient feel happy, contented and socially again possible.

The only disadvantage, if such it is, is the staining. But this is the case also with tannoform and chromic acid, the permanganate sharing none of their other unpleasant properties. As the staining carries with it the exsiccating and curative properties, its removal is of course contraindicated. If for any reason discolorization is desired, a diluted solution of oxalic acid, or better yet, the following formula will serve excellently: natrium subsulfurosum, 120.0; aquæ, 250.0; acid hydrochlorici

Digitized by Google

diluti, 60.0. Use with a pad of absorbent cotton. This mixture develops free sulphuric, which is bleaching.

The advantages of this treatment are:

1. The remedy employed is absolutely devoid of any danger, is painless and heals the dreaded fissures without the previous painful application of silver nitrate.

2. It can be employed in every stage and form of sweating feet.

3. Relapses are less common than with any other method and rarely appear before the third month.

4. The use of the dusting powder has in some cases made the interval even longer.

5. Its action consists in its reducing power and consequent keratisation of the epidermis. It stands to reason that it penetrates into the secretory cells of the coil glands, inhibiting or decreasing their physiologic overactivity.

6. After desquamation the new epidermis is not sensitive, and walking is not impaired as after the use of chromic acid.

7. The mode of employmen —medicated footbaths— is a pleasant one.

616 Madison Avenue.

DISCUSSION.

Dr. L. Duncan Bulkley, New York City—I have had a good many cases of hyperidrosis of the feet and have found it a very troublesome affection. I have not used permanganate of potash in the way suggested, but I have generally found fair results from foot baths of white oak bark and the rather free use of salicylic acid in the stockings; the acid, thoroughly powdered, may be mixed with starch and chalk. Two per cent. to 5 per cent. of the acid suffices, and generally this proves to be a very satisfactory mode of treatment. I should like to remind the gentlemen present of the value of permanganate of potash in other conditions. I do not know how much it is being used to relieve itching, but I am employing it continually in chronic eczema, especially about the groin and legs. A 2 or 3 per cent. solution of permanganate of potash is a very efficient antipruritic. I learned it from a patient, I think, of Dr. Montgomery of San Francisco.

Dr. E. C. Hay, Hot Springs, Ark.—I have used salicylic acid in alcohol in this condition with excellent results. I had one

Digitized by Google

case in a physician, a friend, who after trying everything else, used two drams of salicylic acid in eight ounces of alcohol. For six or seven years I have invariably prescribed this and have never had it fail. It is absolutely painless. I have the patient take a footbath on retiring at night, and then apply this solution to the soles of the feet, being careful not to get it on the hands; it is applied between the toes with a brush. Three or four applications will destroy the odor, and its use is continued until the trouble entirely subsides.

Dr. A. Ravogli, Cincinnati—Hyperidrosis is an interesting subject. In armies, especially in the infantry, men are subject to hyperidrosis, which makes them incapable of taking long marches. Formalin has been used recently in the armies to prevent and also to cure hyperidrosis of the feet. Formalin has a very good astringent action on the secretion of perspiration. It diminishes this secretion, and destroys the odor resulting from the excessive perspiration. Formalin, 2 to 5 per cent., is used for the bath, and is also used to paint the feet of the infantry. In Switzerland a 40 per cent. solution is applied on the normal skin and the feet washed immediately. Also a few drops of a 40 per cent. solution of formalin are put into the soldiers' shoes, and it has been found that in this way they are able to stand marches and also suffer less from this excessive perspiration.

Dr. Ludwig Weiss—I know of these remedies and they are good. Salicylic acid has been used in the German army, but I have found that it leaves such an irritated, inflamed skin behind as to make walking painful. I would warn against the use of formalin; it is exceedingly painful, especially when there are fissures, and patients get inflammations which prevent them from walking and confine them to the house. I would again plead for the extended use of permanganate of potash as an innocent, painless and very effective remedy.

Digitized by Google

ACNE KERATOSA.

WILLIAM S. GOTTHEIL, M.D.
Dermatologist to the City, Lebanon and Beth-Israel Hospitals.
NEW YORK CITY.

Under the varying designations of acne keratosa, acne cornée, keratotic acne, keratosis follicularis contagiosa and acne sebacea concreta, a peculiar glandular affection of the skin has been recorded by a few observers. I have had occasion to study two cases during the past winter, and the accompanying notes are based on them. The literature of the affection is scanty; I have been able to find but 11 cases in all. Crocker and Jamieson[1] describe 4, J. C. White[2] 2, and Du Castel,[3] Giovannini,[4] Hallopeau,[5] Hallopeau and Macrey,[6] and Tenneson and Leredde[7] one each. On these, the descriptions in the text-books of Thibierge,[8] Jarisch,[9] Kaposi[10] and others are based.

Some even of these few cases are open to doubt. Thus those of White seem to have been cases of Darier's disease; psorosperms were afterward demonstrated in them

1. Crocker and Jamieson: British Journal of Dermatology, January, 1899, and August, 1901.
2. White, J. C.: Journal of Cutaneous Diseases, June, 1899.
3. Du Castel: Monatshefte für praktische Dermatologie, vol. xxxiii, p. 439.
4. Giovannini: Gazetta Medica di Torini, No. 41, 1899.
5. Hallopeau: Annales de Dermatologie et de Syphiligraphie, 1899.
6. Hallopeau and Macrey: Monatshefte für praktische Dermatologie, vol. xxii, 1896, p. 77.
7. Tenneson and Laredde: Annales de Dermatologie et de Syphiligraphie, No. 4, 1895.
8. Thibierge: La Pratique Dermatologique, Besnier, Brocq and Jacquet, vol. i, p. 251.
9. Jarisch: Die Hautkrankheiten, Vienna, 1900.
10. Kaposi: Pathologie und Therapie der Hautkrankheiten, Vienna, 1893.

Digitized by Google

by Bowen. In spite of the paucity of recorded material, however, I can not think that the affection is so very rare. Cases are very liable to be regarded as instances of ordinary acne, molluscum contagiosum or warts. This happened to my own before they came under my observation.

A study of the recorded cases shows very plainly that the designation "acne keratosa" has been applied to lesions different in kind, but alike in the facts that the eruption consisted of isolated acuminate lesions surrounding the glandular orifices of the skin, and with corneous accumulations in the openings. At least three types have been distinguished.

The first and simplest is that described long ago by Hardy,[11] where yellowish-gray or blackish prominences, acuminate and firm, and one-half to one millimeter in diameter, appear on the skin. The integument surrounding the tumors is normal; pressure on it causes the extrusion of the central corneous mass, and the follicular orifice remains patent until renewed corneous formation occurs. The lesions may be isolated, disseminated or grouped; they appear especially on the face around the nose, but are also found on the trunk and limbs. Though they cause no functional troubles, they are chronic in their course and very rebellious to treatment. They are seen at all ages, but occur especially in the young. Their cause is entirely unknown.

The anatomy has been studied by Leloir and Vidal.[12] They found that the process was essentially a pilar folliculitis, with considerable thickening of the corneous epidermis of that structure. In the midst of the corneous accumulation were stainable epidermic cells, showing that the process of keratinization was incomplete. The hairs were strangled in the cell accumulation, and there were slight signs of inflammation in the surrounding tissue. Leloir and Vidal regard this type

11. Hardy: Lecons sur les Maladies de la Peau, 1865, p. 108.
12. Leloir and Vidal: Comptes rendus de la Societe de Biologie, April, 1882.

Digitized by Google

of the affection as a folliculitis, and not an acne, since the hair sacs, and not the sebaceous follicles, are the parts affected.

A second type is that described by Tenneson and Leredde[7] under the rather inappropriate name of acne cornée exanthematique. The lesions were similar to those of the first type, but the eruption was much more general and grouped or policyclic in arrangement. The microscope showed thickening of the corneous layer at the orifices of the sebaceous glands, forming a true crater around the hairs, but the follicles and glands themselves were not affected. The case was evidently closely related to true acne.

Finally, the cases recorded by Brooke[13] under the name of contagious follicular keratitis differed from those heretofore mentioned, in that they developed spontaneously in several children of a family, appeared to be contagious, and progressed rapidly and spontaneously to recovery.

Crocker's four cases[1] resembled those of the first type in some respects, and especially in their early stages. But when the corneous plugs were removed by scratching, on account of the irritation that they occasioned, the lesions continued to enlarge, there was renewed corneous formation, and there finally resulted large, even nail-sized marginate excoriations covered with horny masses. Healing was very slow; the lesions lasted for months, and showed great tendency to return *in situ;* and in one of Crocker's cases the disease had lasted forty years. There was difference of opinion as to the results of the microscopic examination, Crocker holding that the hyperkeratosis began in the sebaceous glands. while Jamieson thought it pilar in origin.

Du Castel's case[3] was of the second variety, for the characteristic lesions were grouped in plaques on the arms, neck, chin and legs. Both the reporter and

13. Brooke: La Pratique Dermatologique, Besnier, Brocq and Jacquet, vol. 1, p. 252.

Digitized by Google

Darier claimed that the hair follicles were the seat of the disease; it was a follicular keratitis, rather than a corneus acne in the restricted sense of that term. Giovannini's[4] case was similar clinically, but the sebaceous glands were atrophied and filled with cells identical with those of the malpighian layer. On the basis

Fig. 1.—Acne keratosa. Lesions in various stages of development.

of his examination the author is inclined to regard the affection as an atrophy of the sebaceous glands, with the hyperkeratosis as a secondary phenomena.

In the case reported by Hallopeau,[5] the concretions were found to be seated in both the sebaceous glands and the hair follicles.. Chemically and microscopically, they were composed mostly of fat. J. C. White's cases,[2] as above stated, were finally recognized as true psorospermoses. That of Tenneson and Leredde[7] showed gen-

Digitized by Google

eralized grouped lesions, mixed with those of ordinary acne. The microscope demonstrated their sebaceous origin. As did Giovannini,[4] these authors recognized an atrophy, probably from pressure of the gland lobules.

Fig. 2.—Acne keratosa.

Hallopeau and Macrey[6] failed to find Unna's acne bacillus in their case.

In the present state of our dermatologic knowledge, it seems to me that the multiplication of disease types by emphasizing minor clinical or anatomic differences

Digitized by Google

is a service of very doubtful value. We are overwhelmed with the mass of observations and astray in the desert of terminology. The time for classification, for simplification, for synthesis, has evidently arrived, and we anxiously await the advent of the new Hebra who will bring order out of the chaos.

In view, therefore, of the essential clinical identity of the lesions in all these cases, we can disregard variations of arrangement, or even of precise anatomic origin. We have an eruption composed of acneform lesions, non-suppurative and but slightly inflammatory, with the formation of hard plugs composed chiefly of keratinized epithelial cells in the gland orifices, prob-

Fig. 3.—Acne keratosa. Nodule with partially extruded plug.

ably locally contagious, and tending after a time to spontaneous recovery. This is a definite clinical entity.

Of my own two cases one has been under observation during the past winter, and has been studied with some care. The second case has only recently appeared, and as the lesions are precisely similar to those of the first patient, I shall confine myself chiefly to this latter.

Case 1.—A. B., aged 12, Dec. 13, 1903. Since his second year the lesions of which he complains have come on his face, head and hands; they have never appeared anywhere else. They come and go slowly; sometimes they are more and sometimes they are less numerous; but he has never been entirely free from them. They cause no subjective sensations save a

Digitized by Google

little itching. Each lesion appears as a minute red spot, which gets larger and larger. Then there appears a black mark on the top, which is hard, and which reappears when it is scratched off. Nothing ever comes out of them. After increasing to a certain size the lesion slowly "dries up" and goes away, leaving a stain. Then others come out in different places.

The patient is a perfectly healthy lad; he has had measles and some tonsillar trouble. There are two other children;

Fig. 4.—Acne keratosa. Corneous plug, showing persistence of the epithelia.

neither they nor any other members of the family have had anything of the kind.

Examination.—The lesions present are mostly round, acuminate, hard nobules, slightly erythematous at their bases, and varying in size from less than a pinhead to a large pea. Each one shows a more or less brownish or blackish horny

Digitized by Google

concretion in its center. This is recognizable with a magnifying glass even in the very minutest of them; and it can be felt as a hard, pointed projection even where it is hardly visible to the naked eye. In the larger and older rounded lesions the corneous plug is the size of a small round pea; the outer layers are brownish-black; the central portion is black, pointed, sometimes curved, and projects a millimeter above the surface of the skin. Firm pressure on the base of the tumor effects expression of the plug; a gaping glandular orifice is left behind. There are no acne lesions of the ordinary kind anywhere, nor is there any serum or pus in any of the efflorescences. (Fig. 1.)

There are some lesions present, however, of different appearance. They are oval or crescentic areas, with slightly indurated and erythematous margins similar to the smaller lesions, and with large, somewhat elevated, dark colored, hard, horny accumulations in their centers. Removal of these central masses, which are but moderately adherent, leaves an excoriated depression behind. Some of these lesions are quite large; one of them is over half an inch in size. The patient says that generally when the spots reach pea size, and the central concretion falls or is scratched off, retrogression begins; but sometimes the lesions continue to grow. The central accumulation may be removed and may reappear a number of times, and it may be several months before definite healing occurs. (Fig. 2.)

All the lesions are on the hands and face; there have in the past been some on the scalp, but never any on any other part of the body. On the back of the right hand there are 15, together with some superficial stains and scars marking the sites of former efflorescences. On the back of the left hand are 12; on each cheek, 3, and there is 1 on the center of the forehead. Palms and soles are free and have always been so, nor have the feet ever been affected.

Microscopic Examination.—During the next few weeks I excised a number of lesions for microscopic examination. A peculiar circumstance was the fact that sometimes, and apparently oftenest when the excision was confined as closely as possible to the affected nodule, and included no healthy skin, the resultant lesions assumed all the characters of the larger efflorescences described above. The edges became a little hard and red, a blackish corneous accumulation appeared in the center, and the usual slow course of extrusion preceded the final healing.

Sectioning presented unusual difficulties. No matter how carefully the material was hardened, the corneous central plug was an almost insurmountable obstacle to the preparation of satisfactory sections. In almost every case the plug was displaced during the manipulations, and when a perfect

Digitized by Google

section was obtained it was usually too thick for microphotographic purposes or even for satisfactory examination. The accompanying prints show the best that I could do.

Briefly stated the anatomic features of the lesions were as follows: The corneous layer in the region surrounding each sebaceous gland was greatly thickened, forming a crateriform

Fig. 5.—Acne keratosa. Deep portion of corneous plug, showing degenerated cells resembling psorosperms.

mass, with more or less sloping edges. The thickening was most marked in the upper part of the follicle, and was thinner in the lower. The sebaceous cells themselves could only be distinguished in the deepest parts of the follicles; they were

Digitized by Google

atrophic and flattened, evidently from pressure. In none of the specimens could any hair structures be found.

In the smallest and earliest lesions the dilated follicle formed an irregularly oval sac, broad above and pointed in its deepest portion. In the larger and later lesions the sac was broad and crateriform. (Figs. 3 and 4.) And in every case the sac was occupied by the keratinized mass that is characteristic of the disease. There were some migratory cells in the connective tissue around the walls of the sebaceous glands, but in general the evidences of inflammatory action were but slightly marked.

The corneous plug itself was composed of a mass of imperfectly keratinized corneous cells. (Fig. 5.) Throughout its mass the protoplasm and nuclei could be stained, showing that the process of keratinization was incomplete. In the upper central part of each fully developed plug, however, was a small mass of cell material that seemed to have undergone a complete change, and in which no persistence of cell structure could be demonstrated. No necrotic hairs or their remains, as claimed by Tenneson and Leredde, were found in any of the plugs.

Differential Diagnosis.—The anatomic picture resembles that of ordinary acne and comedo in some respects; but it differs in the absence of the small-celled perivascular infiltration surrounding the follicular epithelium that marks the inflammatory nature of the acne lesions, and the comedo plugs are not composed entirely of imperfectly keratinized corneous cells. It is as characteristic in its way as is the clinical picture of the affection.

I might add that the larger oval and crescentic lesions that were exceptionally noted were found microscopically to be exactly similar to the smaller ones.

The cases, therefore, were true hyperkeratoses of the sebaceous glands, without any demonstrable pilar involvement. We are entirely in the dark as to its cause.

In both the cases that came under my observation the affection was confined to the backs of the hands and the face, a fact that inclines me to believe that a contagious element of some kind, spread by direct local transfer, was its cause.

144 West Forty-eighth Street.

Digitized by Google

PRURIGO (HEBRA) AS OBSERVED IN THE UNITED STATES.

WILLIAM THOMAS CORLETT, M.D.
CLEVELAND, OHIO.

The opinion is held by some that prurigo, as met with in Vienna, does not exist in this country. It is true that cases from time to time have been reported by Zeisler and others, who are familiar with the disease as it exists in Austria, and while there has been a *quassi* acceptance of these reports, yet they are looked on by many as unique. In England, previous to the International Dermatological Congress, which met in London in 1896, the prurigo of Hebra was unknown. At this congress cases were collected which it was thought corresponded in many ways to those observed in Vienna. These cases were examined by Kaposi and others, who confirmed the diagnosis of prurigo (Hebra), which established the fact that the disease was encountered in England, and to some of the American dermatologists present demonstrated that the prurigo as observed in the United States might likewise correspond to that observed in Vienna. The following cases may be of interest as typical examples of prurigo, as described by Hebra, which have come under my observation in Cleveland, and which correspond with cases seen in Austria, Germany and England:

CASE 1.—G. Z., male, 6 years of age, was first seen at the dispensary of Lakeside Hospital July 22, 1900. The mother stated that the child was born in Cleveland, although she and her husband were natives of Germany. There were four other children in the family older than the patient. The family history was good. No previous illnesses, excepting varicella and

Digitized by Google

pertussis when two or three years of age. The mother stated that the child was born at term, was well developed and enjoyed good health until the present disease began, which occurred during the first year of life. It was noticed that the baby was more "itchy" than had been the case with the other children, and when less than a year old was noticed to indulge in vigorous scratching. As the child developed it was noticed that the oft-repeated scratchings gave rise to a papular eruption. This continued and became gradually more marked as the child grew older.

Examination.—When the case came under observation the child was normally developed and intelligent. It was somewhat pale; the lungs and heart were normal, temperature was 98.5, respiration 30 and pulse 90; the urine was normal. The eruption was most marked on the extensor surfaces of the thighs, on the legs, arms and forearms, and to a less extent on the trunk. The butttocks were likewise involved, and during the cold weather the mother stated that these regions gave more annoyance than during the summer. The lesions consisted of whitish papules, some of which had excoriated apices, while others were topped with desiccated blood crusts. Other lesions, again, were pale red. On slight friction the papules became more prominent and extremely itchy. In other places excoriations, which were evidently the result of scratching, were observed. A few small pustules were present, although this was not a conspicuous feature, and was doubtless the result of inoculation of pus organisms in the process of scratching. Over the regions most involved the skin was slightly thickened and of a darker hue than was met with elsewhere, and a few small cicatrices were observed. The skin furrows over the knees were markedly thickened. This was observed to a less extent on the tips of the elbows. The skin appeared to be unusually dry, although the mother stated that she had not observed that the perspiration was greater or less than that observed in her other children. On reviewing the case, the lower extremities were more severely involved than the upper. Further, there was a marked contrast between the parts involved and the skin of the femoral triangle and the popliteal space, as well as on the anterior surface of the elbow, which seemed to be unusually white and thin.

Treatment.—Tonics internally with cod-liver oil, and local applications to relieve the itching, were given. Some improvement was noticed during the summer, and the patient passed out of sight. In January, 1901, the patient returned for treatment, with a condition which might easily be mistaken for eczema, although the same regions were involved, and on close inspection the same papular characteristics were observed. Under soothing applications, which consisted of carbolized boric acid ointment, which later was replaced by an ointment

Digitized by Google

containing carbolic acid and white precipitate, the case again made marked improvement, but at no time did it wholly subside. The case has been seen once or twice since; the irregular attendance is accounted for by the discouraging progress of the disease.

CASE 2.—R. R., female, aged 3 years, native of the United States, of English parentage, was seen for the first time Nov. 5, 1897. The patient has two brothers older and two younger than herself, in none of whom could a history of any cutaneous disease be found. Patient has always had good health, excepting that she has had varicella, rubeola and diphtheria. The mother stated that at the age of one and a half years the child complained of a very itchy skin, with the formation of small papules, which become excoriated with scratching and which never fully subsided. It was always better in the spring and summer months, but seemed aggravated by cold weather. The legs were the parts mainly involved. The extensor surfaces of the thighs and over the calves of the legs seemed to be especially selected, although the back and the extensor surface of the arms were likewise involved.

Examination.—When first seen the lesions consisted of pinhead-sized papules, some excoriated puncta, together with denuded areas, evidently the result of scratching, situated on a moderately thickened and slightly pigmented skin. In the popliteal space and the region of the groin the skin remained normal. On scratching, whitish papules which resembled urticaria appeared. These, the mother stated, had always been present to a greater or a less degree. This case was seen at very irregular intervals.

Treatment.—Local applications containing carbolic acid, salicylic acid and tar gave temporary relief, but at no time has the disease wholly disappeared. The opportunity of studying this case has been ample, and in my opinion the diagnosis of prurigo (Hebra) is warranted. The patient has appeared several times a year since, and no great change can be noticed excepting that the skin is somewhat thickened over the parts affected and is of a darker color. Year by year new cicatrices are added. Several methods of treatment have from time to time been resorted to. Internally, cod-liver oil, arsenic and iron, with the hope of increasing the general nutrition, has been followed, but without much apparent benefit. Local applications seem to give temporary relief, although at the same time the skin seems to become habituated to any local application if continued for a few months. On the whole, fatty substances have given more relief than aqueous solutions. As the normal secretions of the parts affected seemed to be diminished, liquid vaselin and carbolic acid ointment were selected and have given marked relief. Tar, resorcin and mercury have likewise been efficacious, although none of these measures seem

Digitized by Google

to possess more than a temporary palliative effect. The disease is much worse in winter, although it does not wholly subside during the summer months.

CASE 3.—W. F. W., male, aged 9 years, was seen for the first time Oct. 8, 1902. The disease came at the age of 5 years, and has always been worse in the spring and winter. It was situated more or less over the whole body, although the extensor surfaces of the thighs and legs and the skin of the buttocks were more markedly affected.

Examination.—The lesions consist of whitish or pinkish papules, which become more prominent when scratched, together with small excoriated areas. The arms, and to a less extent the forearms, were from time to time affected in the same way. The skin in the areas involved has become slightly pigmented and perceptibly thickened. There seems to be a lessened activity of both the oil and sweat glands in the parts affected. While the skin appeared to the writer to be unusually harsh and dry, the patient stated that he sweats excessively in the axillæ and about the neck and face.

Treatment.—Tonics were given, together with cod-liver oil, internally, and carbolic acid, resorcin and vaselin were applied locally.

In conclusion, I believe the disease is more common than is generally believed. The disease is often masked by excoriations from scratching, which, together with the pustules, give rise to a dermatitis readily mistaken for eczema. The disease should not be confounded with the prurigo hiemalis of Duhring, which is a very common affection in the Great Lake region in winter. In both diseases, however, there seems to be a diminution in the sebaceous and sudoriferous secretions. Both conditions are of uncertain duration, and may last a lifetime. In both, internal medication seems to have no effect, while in my experience liquid vaselin, to which may be added carbolic acid, is the most universally beneficial application used in the treatment of both forms of the disease.

DISCUSSION.

DR. EDMUND L. COCKS, New York City—I remember a case shown in London in 1896, and I was very much chagrined that our eastern colleagues had something we could not produce in America. I have a patient whom from the early age of one month had urticaria. The lesions were characteristic, would come and go in spite of any treatment. The child, now

Digitized by Google

9 years of age, is still under my observation and the urticarial lesions have developed into the characteristic lesions of prurigo. He was presented two years ago to the Manhattan Dermatological Society and two of the members who had studied in Vienna agreed in the diagnosis. It is a typical case, I am sure. The flexors of the arms and the popliteal spaces have been free from the first. He has never been nearer Austria than New York; his parents are of Irish descent. During the winter the pruriginous lesions are fully developed, admitting of no mistake as to their character, but in summer the lesions do not come out to the same extent unless he scratches; then, of course, we have the papules covered with small blood clots. Constitutional treatment has benefited him considerably and the pruritis has been relieved by a naphthol liniment.

Dr. A. Ravogli, Cincinnati—I was surprised to hear the statement made in London in 1896 that in the United States prurigo was not known at all or was exceedingly rare, when every year, between my private practice, hospital practice and clinical practice, I was seeing 10 to 15 cases of prurigo of different degrees of severity. I have cases of prurigo which were called by Hebra prurigo mitis as well as prurigo ferox. I find that pruriginous eczema, which is so difficult to cure, is maintained in children between 2 and 3 years of age, by the presence of prurigo, and the eczema is nothing else than the aggravation of the prurigo on account of the continuous scratching and the condition of the skin.

Dr. H. W. Stelwagon, Philadelphia—Philadelphia does not seem to furnish any cases of prurigo. I think a large number of us have been students in Vienna, and if there was one discase about which, on my return, I thought I knew something and was able to make a diagnosis, it was prurigo. I have been looking, however, for the last twenty years for an American case of this disease, and I can truly say I have failed to find one in my native city. There are cases of chronic eczema which may have a resemblance to extremely mild cases of prurigo, but certainly not the ones shown daily in Vienna, where the clinical picture is unique, something that can not be readily confounded with other diseases.

Dr. Ludwig Weiss, New York City—In my service at the German Polyclinic in New York we usually have several cases of prurigo; they are not extremely rare. They are better in summer, when the skin is soft and moist, than in winter, when the skin is dry; the itching is always more pronounced in winter. In making a diagnosis I always try to conform with the diagnostic symptoms which Hebra pronounced papules under the skin, slightly protruding, perceptible more by touch than sight, itching, scratching off the summits, followed by a slight bleeding from the papules, and some coagulated blood as scab adherent to the top of the lesions. We have seen this in

Digitized by Google

every case where we have diagnosed prurigo, and have been extremely careful to exclude papular eczema. There may be some similarity to eczema, but we have never seen such pronounced inguinal dermatitis attending it as in prurigo. In the Manhattan Dermatological Society we have seen such cases repeatedly. In old cases of prurigo we can, as Hebra used to say, in consequence of the resulting induration and pigmentation, almost read the history of the patients by their skins. As to treatment: Being a disease which itches a great deal, we have seen iodin produce good results, but I like the old treatment, the so-called tar baths, better. Brush oil of cade on the skin, then put the patient in the bath for one hour. He then washes himself off with green soap, and after drying talcum powder is applied. The next day Vleminckx' solution is applied, after which the patient bathes. The lime contained in the lotion will precipitate out and be visible on the top of each scratched lesion as a white powder. This treatment is used for a few days, until the skin peels, then talcum powder with menthol is dusted on. Under such treatment the symptoms are mostly arrested.

Dr. L. Duncan Bulkley, New York City—I recognize the prurigo of Hebra, having known it very well in Vienna, as Dr. Stelwagon said; but in this country we find relatively few of these cases. I think there is a medium line, perhaps, between what Dr. Stelwagon and Dr. Weiss have said as to its frequency. It certainly does occur in New York. We are seeing cases at the New York Dermatological Society every winter, where a dozen of us agree as to the diagnosis. Within two or three months a boy of 11 or 12 years was exhibited who has had it since infancy. He presented as perfect a picture of the disease as I used to see under the elder Hebra in Vienna, and every one of us absolutely agreed as to its being a case of prurigo Hebræ. He had enormous glands in his groin, and the flexors were entirely spared, behind the knees and at the elbows. On the other hand, I have had many cases shown me in the New York Skin and Cancer Hospital which some of my assistants have insisted were prurigo, but which were papular urticaria or other conditions. That prurigo of Hebra exists as an entity in New York I think every one of the dermatologic society members will verify. Although it is relatively rare, I may see in New York several cases each year.

Dr. William T. Corlett—The lymphatic glands, in my experience, are not particularly involved. I do sometimes find secondary infection with a general adenopathy. More commonly there is a slight enlargement of the lymphatic glands in the regions thus involved.

Digitized by Google

THE CUTANEOUS MANIFESTATIONS IN DIABETES INSIPIDUS.

REPORTS OF THREE CASES.

ALEMBERT W. BRAYTON, M.S., M.D.

Professor of Clinical Dermatology, Syphilology and Clinical Medicine in the Medical College of Indiana; Vice-President of the College; Ex-President of the Indiana State Medical Society; Editor of the Indiana Medical Journal, etc.

INDIANAPOLIS.

Diabetes insipidus is a chronic disease characterized by the passage of large quantities of normal urine of low specific gravity. It should be distinguished from the polyuria of hysteria and chronic interstitial nephritis, and also from the diuresis in connection with meningitis and tumors at the base of the brain.

Since Willis, in 1674, distinguished between the saccharine and the non-saccharine form of diabetes, it has been known that a low specific gravity and the absence of sugar readily separates diabetes insipidus from diabetes mellitus. The hysterical form of polyuria sometimes closely simulates diabetes insipidus, but its transitory nature, taken with its other protean but characteristic symptoms, renders the diagnosis comparatively simple.

Diabetes insipidus is a rare affection of unknown nature, and with no constant anatomic symptoms. As to its rarity, Dr. Osler states that but three cases occurred in twelve years out of a total of 329,000 patients treated in the Johns Hopkins Hospital and dispensary up to 1901, the date of the last edition of his work on "Practice of Medicine." Dr. Futcher of Baltimore, however,

Digitized by Google

reported seven cases in the medical wards of Johns Hopkins, or one in each 50,000 patients, in a paper on this disease read before the May meeting of the Association of American Physicians at Washington the present year.

The occurrence of the disease in youth is shown by the fact that in the 85 cases collected from the literature by Strauss, 36 cases were between 10 and 25 years of age.

As to causation, the consensus of opinion is that the disease results from a vasomotor disturbance of the renal vessels, due to local irritation resulting from various causes. In the secondary or symptomatic form, these vasomotor irritants may be aortic aneurism, abdominal tumors or tubercular peritonitis. Diabetes of either form is especially apt to occur where there is disease of the medulla, as was first illustrated experimentally by Bernard's famous discovery that certain injuries of the floor of the fourth ventricle in rabbits produced an abundant, pale and sugary urine. Probably the majority of the cases originate in lesions of the base of the brain, notably the lesions due to syphilis, as is shown in the fact that four of the Johns Hopkins cases had suffered from syphilis, and that the seven cases seen by Dr. Tyson in consultation were ameliorated by iodid of potash. Cerebral syphilis is not infrequently attended by polyuria and polydipsia.

Dr. A. Jacobi, discussing Dr. Futcher's paper, thought most cases of the insipid form occur in young children seen in family practice; the diabetes followed cholera, anemia or whooping cough. He had seen cases in boys of 7 to 14, from falls on the occiput; these may have been due to tumors resulting from the fall. Some of Dr. Jacobi's cases were no doubt secondary or symptomatic, rather than primary or "idiopathic," as we say of those chronic cases having no discoverable nervous origin. Fright, injury, sunstroke, debauchery and malnutrition may precede diabetes insipidus.

Digitized by Google

Heredity plays a part, as is shown by Weil's cases. Of 91 members in four generations, 23 had persistent polyuria without any deterioration in health. Trousseau stated that the parents of children with diabetes insipidus frequently had glycosuria or albuminuria.

Diabetes insipidus presents some striking analogies with diabetes mellitus in both etiology and symptomatology, and still more by the fact that the one disease sometimes merges into the other. We know that in the diagnosis of diabetes mellitus we must keep in mind the symptomatic condition known as glycosuria, which is a more or less temporary phenomenon, occurring under the most varied conditions.

There is always sugar in the blood. Under many conditions, as an excess of glucose in the food, or functional disease of the liver, the blood becomes overloaded, sugar is excreted by the kidneys, and we have transient glycosuria, a very different condition from true diabetes mellitus, and which need not necessarily interfere with after good health or with life insurance.

There is a similar distinction between diabetes insipidus and polyuria. The ingestion of large amounts of beer or water; diseases of the medulla or cerebellum, chronic hydrocephalus and hysteria may all increase the flow of urine, but this increase is symptomatic and transitory, and is not the chronic, rare disease here considered.

Diabetes insipidus is a much milder disease than diabetes mellitus. The notable symptoms of diabetes mellitus, such as muscular weakness, rapid emaciation in the young, uncontrollable thirst, excessive hunger and loss of sexual power are not observed in the insipid form.

Nor is the non-saccharine diabetes followed by the notable complications which lead us to seek for sugar in the urine. Boils and carbuncles suggest diabetes mellitus, and the disease is frequently the background for pruritus and chronic eczema. Diabetic gangrene of the extremities is a common occurrence in the course of this disease. Balanitis in the male, eczema of the scrotum, trouble-

Digitized by Google

some and intractable pruritus pudendi of the female, due to the decomposition of saccharine urine, are among the cutaneous incidents of diabetes mellitus. On the contrary, the skin manifestations of diabetes insipidus are of minor importance, and yet may be the cause for which the patient seeks relief.

Such was the case with the second patient noted in this report. He came to me because of a general but mild pruritus. Questioned as to his urine, I found that he was drinking water inordinately at night and passing several quarts of water between retiring and rising. This was of specific gravity 1003 to 1005. He does not perspire enough to wilt his linen in hot weather, or when subjected to extreme muscular effort. The same is true of the third case who, from boyhood, has had an excessive thirst, has passed much urine, and has always an abnormally dry skin. And my first case, affected from his 50th to his 90th year, did not sensibly perspire and had more or less general pruritus.

The pneumonia and lung gangrene of saccharine diabetes; the nervous symptoms, such as coma, neuritis and symptoms of locomotor ataxia, have not been recorded in the complications of diabetes insipidus.

Indeed, when we compare the effects of the two diseases, the disparity of symptoms and complications is great, and all in favor of diabetes insipidus. Both present mysterious problems, the solution of which has not been discovered postmortem, though the histopathology and chemistry have been studied industriously and faithfully. It is not, at this time, possible to go into the theoretical discussion of the nature of diabetes of either form. Each is a pathologic entity, related in large part to affections of the nervous system. Both are very chronic diseases; one is very common and very fatal; the other is rare, and not infrequently overlooked both by the patient and the clinician.

In diabetes insipidus the dryness of the skin, the absence of sensible perspiration and the pruritus may lead

Digitized by Google

the patient to the dermatologist; the thirst, the large quantity of urine passed, the inconvenience of water drinking and the frequent demands to empty the bladder may lead the patient to consult his family physician. He may pass from 20 to 40 pints of urine daily of a specific gravity of 1000 to 1005, but containing the normal amount and variety of soluble ingredients.

The patient may be well nourished and healthy and with ordinary appetite, or he may even have an enormous appetite, as is the frequent condition in diabetes mellitus. Such was the case of one of Trousseau's patients who inspired such terror in the keeper of one of those Parisian eating houses, where as much bread was allowed without extra charge as each patron wanted, that he gave this victim of diabetes insipidus money to prevent him coming back to dine. The tolerance for alcohol has in some cases been as marked as in cases of diabetes mellitus.

When a patient comes to us complaining of dry mouth and scanty saliva, with a harsh and irritable skin, with a generalized pruritus intensified at night, and also complains of night thirst, we may find on examination of his urine that it is of low specific gravity and great quantity, and that he is not suffering from diabetes mellitus, but from the much rarer and more innocent, but not less chronic disease, diabetes insipidus.

The future course of such a patient will depend largely on the nature of his primary trouble. If organic disease is the cause, whether of the nervous system or of the circulatory or abdominal organs, sooner or later we may expect to find the patient's health giving way, with increasing emaciation and loss of strength, but if the case is of the idiopathic type, we may assure him that it is comparatively inconsequential, for this affection has been known to continue half a century, and death to result from intercurrent disease or even from senile exhaustion.

Digitized by Google

Such was the history of one of my three cases—an old physician whom I had under observation for fifteen years, and who died after his 90th birthday. He often assured me that the same conditions had maintained in his case since he left the practice of medicine over forty years before—ingestion of abnormal quantities of water, the passage of abundant urine of low specific gravity, a dry, harsh skin and mouth, with more or less of pruritus and discomfort, and all these symptoms increased at night as compared with the day. And yet he worked a half day in his garden for over forty years, and remained a teacher in the employ of the state until his 87th year, passing into a most beautiful and painless senescence, and to the last with so even a balance of functions that when he passed away I could find no organ or system to accuse of failure more than another; and for once, the much-abused phrase, "senile exhaustion," which we give as a death return in cases of diagnostic disability, was written in the confidence that no better term could be devised or employed.

My second case is that of a man of 50 past, who for two years has suffered from diabetes insipidus with great thirst intensified at night; and at night the pruritus from which he suffers is also intensified. Otherwise he is apparently well. He gives no history of syphilis; his life has been exemplary; his labor severe and exacting. But following the success of Dr. Tyson with iodid of potassium in his seven cases, I shall offer him the chances of this treatment.

Our authors assure us that the treatment by drugs is, on the whole, unsatisfactory. Opium, codein and ergot have been recommended; also the preparations of valerian, the latter, on the whole, having the preference of the therapists. We are advised not to forbid the patient to assuage his imperative thirst, even if that were possible. The skin should be well cared for by baths and frictions, and the general health and vigor promoted by nourishing food, outdoor life and the avoidance of worry.

Digitized by Google

The third case of diabetes insipidus under my observation I have known as a patient for some fifteen years. As a boy of 12 he was afflicted with alopecia areata of the scalp, including also the eyelashes and eyebrows. These attacks were recurrent for some eight or ten years, but have ceased, and his hair is now normal. He has been a great drinker of water, and has passed more water than the normal, as he says "ever since he can remember." He now fills an ordinary chamber vessel every night, passing more proportionally in the night than during the working hours. His skin is dry; he does not perspire under the hottest Cuban sun; his mouth and throat are dry. This is in part due to the excessive use of Cuban cigarettes and cigars. He has a pruritus intensified at night, as is the usual case with this affection from whatever cause produced. His urine is never above 1005; the solid ingredients are normal for his weight, diet and exercise. His habits are sedentary; his business is clerical. I find no other disease or aberrancy. Like the other two cases, the heart is rapid—always about 90 beats to the minute. His appetite is somewhat excessive; his digestion fairly good, except when exhausted by unusual office labor and the depression of a southern climate.

In no one of these cases has there been apprehension, despondency, abnormal introspection or impairment of sexual capacity. They collectively illustrate the benignancy of a pathologic condition rare in occurrence, of unknown nature, and without discoverable organic lesions, or constant morbid anatomy, but undoubtedly connected with changes in the central nerve axis, the sympathetic nervous ganglion, or of the afferent or efferent nerves—most probably a vasomotor ataxia.

The condition may be far more frequent than the scanty statistics indicate, as the symptoms presented, namely, thirst, polyuria and dryness of the skin with pruritus, may not be sufficient to lead the sufferers to seek medical advice; or when they do seek such advice

Digitized by Google

for the resulting manifestations the consultant may, if negligent in examining the urine as an essential step in his routine of diagnosis, overlook the cause and so fail to find the background of diabetes insipidus.

The reports of these three cases may be of value in relating some case of pruritus to the overexcreting function of the kidneys, even if the consultant is unable to determine the cause of this extreme exercise of their normal function.

330 Newton Claypool Building.

Digitized by Google

COVER-GLASS CULTURES AND THEIR POSSIBILITIES IN STUDYING EPIDERMIC FUNGI.

J. FRANK WALLIS, M.D.
Instructor in Dermatology, Philadelphia Polyclinic; Dermatologist to the Southern Dispensary; Dermatologist and Radiotherapeutist to the Henry Phipps Institute.
PHILADELPHIA.

The popular methods for studying the macroscopic and microscopic appearances of the epidermic fungi have been limited to the tube and plate cultures and their modifications on various culture media, and the hanging

Fig. 1.—Moist chamber for cover-glass cultures.

drop of bouillon ably demonstrates the structural formation of the growth.

By the plate culture Sabouraud, Colcott, Fox and others have suggested a classification of the tinea by their clinical appearances and their behavior on solid media. Although they have distinguished certain of the parasitic growths, yet their differentiation from some of the common molds which form cultures not unlike the

Digitized by Google

for the resulting manifestations the consultan·
negligent in examining the urine as an essent
his routine of diagnosis, overlook the cause
to find the background of diabetes insipidus

The reports of these three cases may be
relating some case of pruritus to the overexc
tion of the kidneys, even if the consultant
determine the cause of this extreme exercis
mal function.

330 Newton Claypool Building.

.strating the proc-

the hanging drop
the development
the latter, and
various stages by

ful arrangement of
the growth of the
and the character of

Digitized by Google

.e
is
pre-
ject.

.s Fig. 2, but at later stage.

. specially prepared moist cham-
f a shallow glass dish furnished
er of glass, one-half inch in height,
wo distinct compartments and afford-
er which is fitted a thin glass dish
eight. In the inner compartment are
hes holding the prepared cover glasses
sture is produced by keeping lime water

Digitized by Google

growth of the trichophyton, can only be corroborated by the microscope.

Smears from cultures and cover-glass impressions only suggest stages of a growth and forms of fructification, without a complete history of vegetation.

The method which I have entitled cover-glass cultures consists in culturing the parasite on a cover-glass, using any nutrient media desired, placed in a moist chamber and incubated at the room temperature.

Fig. 2.—Hair from small spored fungus, demonstrating the process of budding.

The advantage of this method over the hanging drop consists in the facility for observing the development long after the possibilities afforded by the latter, and by providing a method of registering various stages by staining and mounting.

These specimens exhibit the beautiful arrangement of the formation of mycelia from spores, the growth of the colony above and below the media and the character of

Digitized by Google

the fruit-bearing bodies or conidia, without disturbing the picture as it occurs in life.

The scheme consists in placing a drop or two of culture medium on a cover glass which has been passed through a flame. If solid medium is used, it must be liquefied by gently heating and then dropped on the cover glass with a platinum loop. The hair or scale is then embedded while the medium is soft. I generally prepare from four to eight cover glasses for each subject.

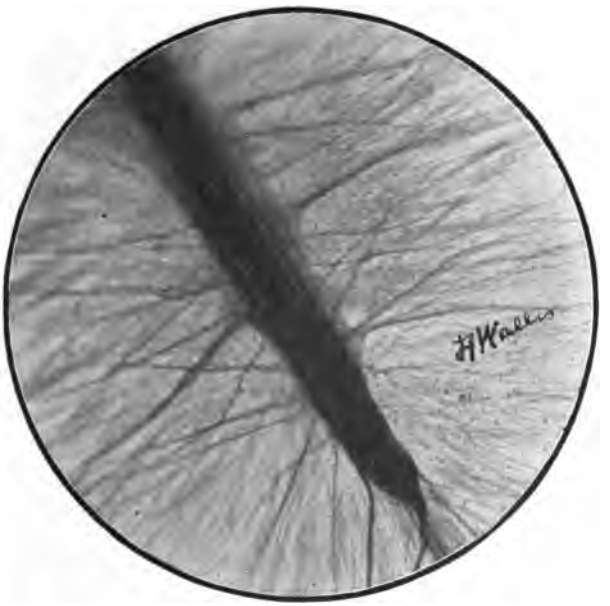

Fig. 3.—Same hair as Fig. 2, but at later stage.

These are cultured in specially prepared moist chambers, which consist of a shallow glass dish furnished with a circular barrier of glass, one-half inch in height, separating it into two distinct compartments and affording a shoulder over which is fitted a thin glass dish three inches in height. In the inner compartment are placed Petri dishes holding the prepared cover glasses (Fig. 1). Moisture is produced by keeping lime water

Digitized by Google

in the bottom vessel outside the hooded barrier. This excludes the air and prevents evaporation of the medium. The dishes must be replenished with water frequently. Lime water is preferred, as it precludes the possibility of contamination. This is further prevented by packing a rope of cotton in the water around the cover, a precaution invaluable if the water should become vaporized. This has not infrequently happened in my experience.

Fig. 4.—Hair from small-spored fungus, five days' growth, under high power.

I have sometimes found it necessary to prevent drying of the medium by placing the cover glasses on moist circles of blotting paper in each Petri dish.

Room temperature is sufficient for the growth of the epidermic fungi and less favorable for contaminations that flourish above that point. The average period of incubation is three days, but the microscopic study may commence after the first twenty-four hours.

A cover glass is held to a slide by a drop of water and

Digitized by Google

the commencement of the growth observed. If sufficient progress of the culture is evident, it may be photographed before staining and mounting. Daily inspection should thus be made, and if further development occurs, a record of the same may thus be preserved.

This process permits the observer to study the growth of the living culture through all stages, from the formation of mycelium in and above the medium to the full development of a perfect colony, thus exhibiting the

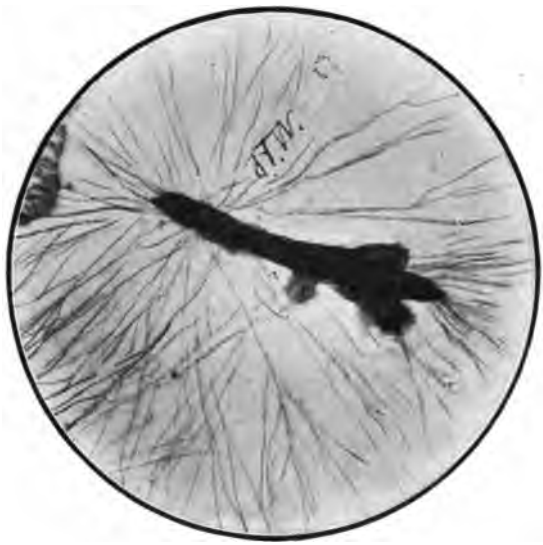

Fig. 5.— A cultured hair from the small-spored fungus.

form and character of the fruit bearers and the manner of reproduction.

The removal of the culture by the platinum loop, known as the "smear," will not convey to the mind of the observer the process that he has wantonly destroyed. This difficulty Dr. Unna endeavored to overcome by a process which enabled him to study the growth of the living fungi, and which he published in 1888 in a paper entitled "Cultivation of Epidermic Fungi."

The plot consists in sealing a perforation in a slide with a cover glass smeared with vaselin. This cell is

Digitized by Google

filled with some nutrient medium, a mixture of peptone, gelatin and peptone agar being preferred. This he placed in a glass plate kept cool with ice. When solid, the cover glass was removed and half the jelly taken away by means of a platinum wire, forming a half moon. The slide was then placed in a perpendicular position, the free border thus formed then inoculated, permitting the aerial portion to grow upward in the empty

Fig. 6.—A hair of class 2, after five days' growth.

half of the hole. About twenty of these slides were thus prepared and held upright in a glass vessel with grooved corks; the bottom of the vessel was covered with blotting paper saturated with a solution of sublimate. The method of Unna has the advantage that the growth can be viewed from the side, but it can not be preserved by staining and mounting, nor can the first stages of the development of a colony be studied.

The value of cover-glass cultures will be more fully

Digitized by Google

appreciated if we study the progress of living cultures, prepared slides and microphotographs. My work in this field has been purely experimental as yet, and I have made no attempts to classify the epidermic fungi; but I hope by the early publication of this paper to interest others and by their assistance to eventually establish a class for these parasites and discover the relation they bear to the common molds.

These results can be accomplished by combining the clinical picture and the microscopic findings with the

Fig. 7.—Cultured hair; multiple kerion class.

cover-glass and plate cultures. In studying the trichophytons the three classes, according to the doctrine of Sabouraud, should be observed.

The microphotographs represent a few of the variations in the growth of the microsporon and the megalosporon, and the two forms of the common molds which not infrequently contaminate our cultures.

Figures 2 and 3 illustrate the development of the fungus from a hair which clinically and microscopically belonged to the first of the three classes of Sabouraud. Figure 2 represents a budding occurring on the shaft

Digitized by Google

Fig. 8.—Hair illustrating an unusual form of kerion.



Fig. 9.—Another hair, illustrating kerion.

Digitized by Google

and the root after the first twenty-four hours' growth. Figure 3 exhibits a sprouting of the bud later, showing a number of sprouts tapering from the hair to the margin of the culture, there expanding into numerous filaments; also a dense network of straight mycelial threads are seen radiating from the hair to the margin.

Figure 4 shows a hair after five days' incubation, taken from class 1. Figure 5 represents a cultured

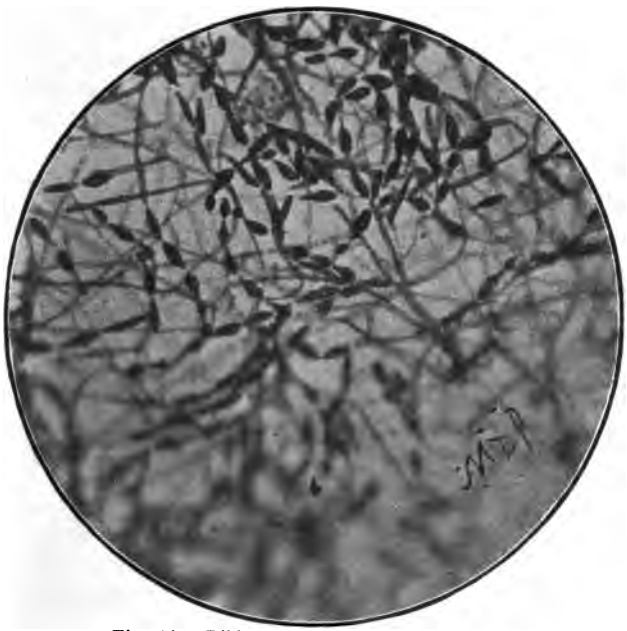

Fig. 10.—Ribbons of conidia after culture.

hair, also from the small-spored variety, after forty-eight hours' growth, with straight mycelium. Figure 6 shows a hair after five days' growth and corresponding to class 2.

Figures 7, 8 and 9 belong to class 3, and illustrate an unusual form of kerion, the lesions consisting of numerous small abscesses invading the greater portion of the scalp. In some instances they were not unlike favus, and a few were clinically diagnosed as such. The patches

Digitized by Google

are conspicuous by the complete loss of hair and an apparent depressed scar. All cases have recovered in less than a year, with a complete restoration of the hair. Out of seven cases observed, five were girls; the eldest were 16 and 17 years of age. The history and description of these cases will be the subject of a paper which will be published later.

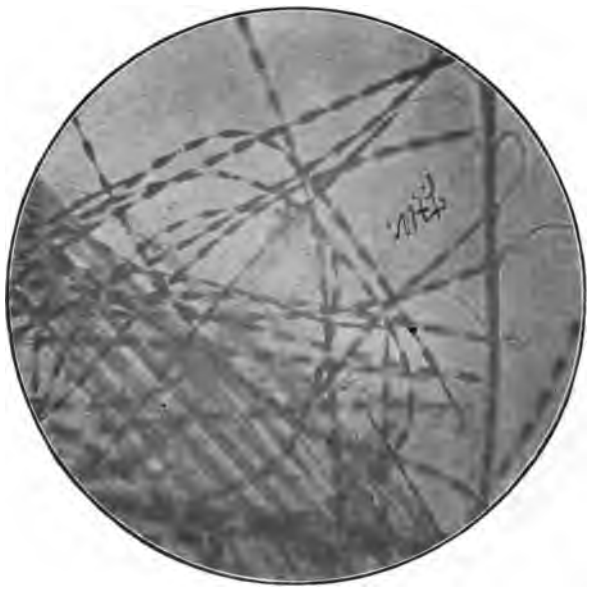

Fig. 11.—Ribbons of conidia in an uncultured hair.

Figures 10 and 11 illustrate ribbons of conidia or chlamydospores, frequently seen in cover-glass culture. Figure 9 is a microphotograph of a culture, and is the same process found in an uncultured hair after digestion in a solution of caroid and stained.

Figures 12 and 13 represent two molds. Figure 11 is a living unstained culture of pencillium photographed from above, and Figure 12 a variety of aspergillus. All specimens are from stained preparations, except Figure 12.

Digitized by Google

DISCUSSION.

Dr. Jay F. Schamberg, Philadelphia—I have seen some of the cover-glass preparations made by Dr. Wallis in this ingenious manner; the method appears to facilitate the study of the various pathogenic fungi, particularly those that develop in hairs. The photomicrographs illustrate the manner in which the mycelial threads grow out through the hair shafts into the surrounding culture medium.

Dr. W. S. Gottheil, New York City—I had occasion to study contagious fungoid scalp disease when I was consultant to a large orphan asylum in New York some time ago. The

Fig. 12.—Unstained cover-glass culture of aspergillus.

trouble had been prevalent for some time before my attention was called to it; and 460 cases were found among the 900 inmates. Some idea of the importance of an outbreak of this usually trivial disease under these conditions is shown by the fact that it nearly led to the permanent closure of the institution; that it took eighteen months to eradicate; and that it cost $30,000 for the hire of and fitting up of buildings, physicians, nurses, etc. We did a good deal of culture work, and finally came to the conclusion that parasites indistinguishable from the trichophyton could be obtained from the scalps of all the children, even those who were apparently unaffected.

Digitized by Google

Whether the fungus in these latter cases was attenuated or not I do not know, but we finally abandoned the culture test as entirely unreliable.

Dr. L. Duncan Bulkley, New York City—It is interesting to see, after many years, the same plan gone back to which many of us used before culture methods were known. Many years ago, twenty or thirty, I used the only way we knew of then, growing the culture on a plate and regulating the temperature of the room by the heater, and I have watched the growth of the parasite exactly as in the pictures presented by

Fig. 13.—Stained specimen of aspergillus.

Dr. Wallis. I think this brings up a very practical matter and is a desirable statement. When a man doing scientific work shows the general practitioner who is not up on bacteriology in general how he may begin in a certain way with an ordinary slide and cover-glass and learn about vegetable parasites, this Section is doing what it is intended it should do, namely, helping the general practitioner to understand these things.

Dr. J. F. Wallis—I am interested in hearing that others have been before me in this work, especially Dr. Bulkley. I thought I was entirely original in this line of work until I

Digitized by Google

read Dr. Unna's paper, published in 1888, and I still believe my process differs from others, as it enables one to preserve the various stages of the growth as well as to study the living colony. Dr. Gottheil's experience in finding cultures from normal hairs proves that growths from other methods are not reliable. It was this difficulty that suggested cover-glass cultures which enables one to observe the spores within the diseased hair develop into mycelial threads and this, I think, without doubt demonstrates the cause of the disease. To make the experiment more perfect I think it prudent to cleanse the diseased area of the scalp with cotton and alcohol, and this is an excellent scheme to collect the hair stubs, as they can be readily found on the cotton when they can not be seen on the scalp or epilated with forceps. This I also depend on as a test, and in my experience it is diagnostic. I depend on this test as a means of studying the progress of treatment.

Digitized by Google

CONTINUOUS ACRODERMATITIS.

AN INSTANCE WHERE IT WAS CONTROLLED BY THE X-RAY.

DOUGLASS W. MONTGOMERY, M.D.

Professor of Diseases of the Skin, Medical Department of the University of California.

SAN FRANCISCO.

Very few writers now believe eczema to be one disease. It is a vast agglomerate of diseases, out of which clinical types are being slowly segregated. In pursuance of this theory, Hallopeau in 1897 proposed[1] to remove a group of cases out of the general class of eczema, and to call the group "the continued acrodermatites." Cases constituting this group are characterized by their location on the extremities of the members, more particularly on the fingers and toes, by their incessant recurrence in the affected locality, by their not extending for a long time to any other region of the body, and by their obstinate resistance to treatment.

Three forms of this malady are described—a vesicular form, a pustular form, and a form where there are both vesicles and pustules, constituting a vesiculopustular form.

The case under consideration would fall in the vesicular group. The disease as described occurs in the adult or in the aged, and is independent of any other affection. The patients are not neurotic, and the disease

1. Société Française de Dermatologie, 1890, 1892 and 1897. Also in Schwimmer's Jubileeumschrift and the Revue Générale de Chirurgie et de Therapeutique, 1898. He also gives an extended description of this group in the Traité Pratique de Dermatologie par H. Hallopeau et L. E. Leredde.

Digitized by Google

may have its origin in some previous eruption or in a traumatism.

Usually the disease is confined for a long time to one locality. For example, to one of the fingers, frequently to one of the phalanges, then little by little it spreads to the other fingers and to the rest of the hand. The vesicles burst and readily heal and new ones appear. The subjacent skin is red and tumefied. When the scales fall, the epidermis is found thin, smooth and glossy, or the skin may be thickened and its natural furrows exaggerated. The nail frequently suffers in its nutrition; it loses its polish and becomes fluted; it may be transversely flattened, and have little punctiform depressions in it. Subjectively the patient complains of a burning feeling. The course of the malady is continuous, for as one crop of vesicles dries up, another appears, either in the area previously affected or at its periphery.

The affection is distinguished by rebelliousness to treatment. Hallopeau says that hitherto the only remedy found to be of avail is applications of a solution of nitrate of silver (1 to 8).

Patient.—A lawyer, aged 38, consulted me, Feb. 10, 1900, on account of a vesicular eczema of the fingers, which he said he had had for three or four years.

History.—There was a history of eczema on the maternal side. Furthermore, his maternal grandmother had Dupuytren's contraction of both palms, and two of her sons had Dupuytren's contraction of one hand. Two of the patient's sisters had neuritis of the forearms.

The patient was a tall, rather stout, well-built man, who said his general health was excellent. On questioning him more closely, he said that he had had watery passages for several months, and that the least purgative would stir up the bowels. He had never suffered from rheumatism, but he had had slight chills that he attributed to malaria, and he lived in a malarious district. He also told me that at times the movements of the bowels appeared to be undigested, and he always had a heavily coated tongue. These were the only symptoms of digestive disturbance present.

Examination.—The affection consisted of some redness, and a great number of tiny sago grain-like vesicles, with very little thickening of the skin. The disease was steadily present,

Digitized by Google

but it varied in its intensity, and during an exacerbation there was some burning. The affection was confined to the fingers, and there was neither eruption nor history of eruption on any other part of the body.

Previous Treatment.—Before consulting me, the patient had tried many remedies, both independently and on the advice of physicians, and all fruitlessly. Of all the remedies tried, the best was Hutchinson's lotion prescribed as follows:

℞.	Liq. plumbi subacetat....	℥ss	15
	Liq. carb. detergentis.....	℥iiss	75

M. Sig.: A teaspoonful in a pint of water, to be used as a lotion twice a day.

This, however, did not cure the disease, and a great number of topical applications were employed, but the patient always returned to the use of Hutchinson's lotion. Finally this lotion began to irritate, and the disease extended to the back of the hands as spreading circles. There would be an attack of redness with watery vesicles about every four weeks. Lassar's paste, made as follows, was then tried:

℞.	Acidi salicyl.	gr. xx	1	35
	Zinc ox.			
	Amyli, āā	℥ss	15	
	Glycerini	℥i	30	

M. Sig.: Apply as a paste.

Applied during the first part of an attack, this would irritate, but during the decline it would act very well.

Although the troubles in the alimentary tract were slight, yet eczema is so often dependent on alimentary disturbances that the patient was given a vigorous treatment in this direction also, but with no apparent effect on the disease.

X-Ray Treatment.—June 10, 1902, the patient called on me, saying that up till six weeks before the hands had been in fairly good condition, but that since that time there had been no cessation of the eruptions. He had heard much about *x*-ray curing diseases of the skin and urged me to try it in his case. He received nine exposures, extending from June 19 to July 7. On July 12 he called, suffering from a severe erythema of the back of the right hand, and a less intense one of the back of the left. It subsided under appropriate treatment, and he remained for a long time thereafter free from any trouble. Dec. 19, 1903, he again called on me. He was delighted with the treatment, and had had very little trouble in the intervening time. Once a few vesicles had cropped out; the attack was treated with the *x*-ray and quickly subsided. He consulted me on account of a slight outbreak consisting of a circle or rather a ring of induration and some vesiculation, on the ulnar side of the right index finger. There were also small patches of vesiculation with a little thickening on the ulnar side of the terminal phalanx of both middle fingers.

Digitized by Google

The patient said that it was only recently that the back of the hands had become perfectly normal, as after the $\varkappa$-ray dermatitis they had had a crackled appearance on close inspection, but no vesiculation. The hair had not returned on the back of the hands with any strength at all, except as a very light down with a few strong hairs scattered in it. Nitrate of silver solution as advised by Hallopeau was not employed, as I did not know at that time of this treatment.

As regards diagnosis, this case was not pompholyx, because the vesicles rested on an inflammatory base, there never was any bullæ, the affection did not appear on the palms or soles, the attack came on at all seasons, and the patient was in excellent health. Furthermore, there was no extensive sweating. The limited area of the affected locality and the absence of bullæ would exclude both pemphigus and dermatitis herpetiformis

The question always arises if it be of any value to increase our already vast nomenclature by segregating out a class of cases that looks so like eczema. The answer to this is that any reasonable splitting up of the eczema group is permissible, and becomes very desirable when it cuts out a bunch of cases amenable to some special line of treatment.

DISCUSSION.

Dr. C. E. Skinner, New Haven, Conn.—Will Dr. Montgomery please give us the details of his technic as regards the degree of penetration of the ray, the apparatus, etc.?

Dr. H. C. Baum, Syracuse, N. Y.—I can cordially indorse what the speaker has said. In four cases treated by the $\varkappa$-ray the disease has always returned after some months, but with any other local application the disease has not been arrested.

Dr. William Allen Pusey, Chicago—Leaving out of consideration the question as to whether acrodermatitis of the French is a form of eczema of the hands which is entitled to be regarded as a distinct clinical entity, I can confirm Dr. Montgomery's report of benefit in various cases of eczema of the hands which have been treated by very mild $\varkappa$-ray exposures. I have seen a good many of these cases of very chronic intractable type that have yielded to the $\varkappa$-rays.

Dr. C. W. Allen, New York City—I have found the $\varkappa$-ray very efficient in chronic eczema, some of which I treated for years before the $\varkappa$-ray, and now with the aid of the ray these

Digitized by Google

patients remain well. Chronic eczema of the hands, especially of the palms, is often markedly influenced.

DR. A. RAVOGLI, Cincinnati—I find also in my experience that in some cases of eczema, especially of a nervous character, it is difficult to bring about a recovery, but with an exposure of three to five minutes once or twice a week to the ϖ-rays they yield very readily. I think this is the only way to treat this peculiar kind of eczema.

DR. D. W. MONTGOMERY—The ordinary Crookes tube was used, placed about five inches from the hand. The coil was the source of the electricity, and the sittings were of ten minutes' duration. It was a medium tube. As far as segregating these particular cases out of a group of eczemas is concerned, I think it is of value. They are particularly obstinate cases, one can do very little for them with ordinary medication, and they are unlike ordinary eczema of the hand. It is of value to be able to recognize them, so that the correct prognosis may be given, and also possibly because other observers may be able to try the value of the ϖ-ray in this particular group. There are other types, the pustular type, for instance. I have never run across the pustular type, but Crocker has described it and he thinks it should be given a separate place in the nomenclature. I do not know whether these cases are really to be put in the same class with the dermatitis repens of Crocker; some have thought they should. I do not know how the dermatitis repens of Crocker would answer to the ϖ-ray.

Digitized by Google

THE DIAGNOSIS OF SCARLET FEVER AND SCARLATINOID AFFECTIONS.

JAY F. SCHAMBERG, A.B., M.D.

Professor of Dermatology and Eruptive Infectious Diseases, Philadelphia Polyclinic and College for Graduates in Medicine; Assistant Diagnostician and Consultant Philadelphia Bureau of Health.

PHILADELPHIA.

Of all the acute eruptive fevers, scarlatina, in obscure cases, offers the greatest difficulties in diagnosis. In well-pronounced and typical cases the nature of the disease is quite clear. When all the symptoms are well developed an unmistakable syndrome is presented. Who could fail to diagnose a disease characterized by sudden vomiting, high fever, prostration, diffuse punctiform rash, circumoral pallor, red and swollen throat, enlarged glands and strawberry tongue, followed by desquamation, otitis media and albuminuria? But the picture is frequently incomplete.

Those who have had experience with scarlet fever have observed that in very mild cases all the symptoms are commonly poorly marked. When the eruption is intense the throat is usually severely attacked, the tongue is characteristic and the fever is high. When, on the other hand, the general symptoms are very mild, the rash is, as a rule, faint and poorly developed.

It is under the latter circumstances that the diagnosis becomes difficult, for the complex of symptoms on which the foundation of the diagnosis rests is too weak to support it.

How often do we see cases in which the rash is faint, the constitutional symptoms mild, and the throat and

Digitized by Google

tongue uncharacteristic. The evidence appears very slender on which to base the diagnosis of disease which necessitates six or eight weeks of isolation and sundry other inconveniences. Under these circumstances the physician will do best to postpone the pronouncement of a diagnosis until the further course of the disease is watched. In some cases it will remain impossible even in the light of subsequent events to be sure of the scarlatinous nature of the disease. This is a humiliating admission, but the interests of truth demand that the limitations of our knowledge be frankly confessed.

I believe that in no other acute diseases are so many errors of diagnosis made as in scarlet fever. On the one hand, many cases of extremely mild scarlet fever are overlooked, and on the other, rashes from other causes resembling that of scarlet fever are not infrequently diagnosed as the latter disease.

It should be remembered that there is no one symptom of scarlatina which is pathognomonic of the disease.

The rash, the most conspicuous symptom, and the one which has given the affection its name, is not in itself characteristic, inasmuch as a practically identical exanthem may occur in other conditions. Nor does its absence entirely exclude the diagnosis of scarlet fever. Indeed, we may have a scarlatina without eruption (*scarlatina sine eruptione*), without fever (*scarlatina sine febbre*), or without sore throat (*scarlatina sine angina*).

In the formulation of a diagnosis each of the composite symptoms of the disease has a relative value. It may prove of interest to discuss the importance to be attached to some of the manifestations of scarlet fever.

ETIOLOGIC EVIDENCE.

The diagnosis in cases of scarlet fever with obscure symptoms is often clarified by the discovery of the disease in a person to whom the patient has been exposed. In institutions for children the existence of an epidemic

Digitized by Google

often clears up an individual diagnosis which would be quite impossible to make under ordinary circumstances. Close inquiry and examination will sometimes discover a desquamating and unrecognized case of scarlet fever to be the origin of an institution epidemic.

The diagnosis of scarlet fever in doubtful cases is

Fig. 1.—Epidermal casts from a fatal case of scarlet fever.

sometimes confirmed by the disease being transmitted by the suspected patient to another person.

I recall a recent case which emphasizes the importance of such information. A colored child was admitted to the Polyclinic Hospital suffering from a severe burn. About forty-eight hours after admission the

Digitized by Google

temperature rose to 105 F., and a scarlatiniform rash appeared on the body. Nothing characteristic was observed in the throat or on the tongue. The symptoms might well have been attributed to an intoxication due to the burn. Nevertheless, the child was isolated and a special nurse assigned to look after it. In about four days this nurse fell ill and passed through a well-pronounced attack of scarlet fever.

DIAGNOSTIC VALUE OF THE SO-CALLED STRAWBERRY TONGUE.

In the very beginning the tongue in scarlet fever is heavily coated with a whitish fur, through which scattered red papillæ are frequently visible. In about forty-eight hours the coating peels off, and there is seen a red tongue studded with enlarged papillæ. This condition of the tongue is certainly a symptom of considerable diagnostic importance, and its presence or absence in doubtful cases should be determined and considered in formulating the diagnosis. But several sources of error must be kept in view. In mild cases of scarlet fever in which the rash and general symptoms leave doubt as to the nature of the disease, the tongue often fails to present its characteristic appearance. I can not agree with McCollom of Boston, who says that the enlargement of the papillæ is present in every case of scarlet fever, if carefully looked for. I have certainly seen a number of children in scarlet fever wards whose tongues have been quite normal in appearance. Most of these children had mild attacks.

On the other hand, the tongue in well persons shows a variable amount of prominence of the lingual papillæ. I have examined the tongues of a large number of people with a view of determining this point. Anyone who repeats this experience may satisfy himself that the tongue under normal conditions exhibits wide variations in the size and prominence of the papillæ. Moreover, there are certain chronic forms of superficial glossitis in which the papillæ are quite large.

Digitized by Google

It must be remembered, too, that the most typical strawberry tongue may in rare cases occur in affections other than scarlet fever. In a few severe cases of scarlatiniform erythema, occurring during the course of smallpox, I noted very distinct strawberry tongues.

However, these exceptions do not invalidate the force of the statement that the presence of pronounced enlargement of the lingual papillæ in cases suspected of being scarlet fever, is strong confirmatory evidence. The negative value of the absence of the characteristic tongue is of less importance.

THE DIAGNOSTIC VALUE OF DESQUAMATION.

The statement is sometimes made that the occurrence of desquamation after a scarlatiniform eruption proves the scarlatinal nature of the preceding exanthem. Those who have observed cases of scarlatiniform erythema of the desquamative type recognize the fact that exfoliation of the epidermis is not a phenomenon peculiar to scarlet fever.

It is a mistake to regard every diffuse rash that desquamates as scarlet fever. The eruption of scarlet fever is in all probability of toxic origin; there are other toxins which appear to be capable of exciting rashes which resemble that of scarlatina. Scaling is the terminal stage of certain pathologic alterations in the skin and the changes in the skin in scarlatiniform erythema are much the same as those occurring in scarlet fever.

The scaling in certain cases of desquamative scarlatiniform erythema is much more extensive than occurs ordinarily in scarlet fever. The occurrence of well-marked lamellar desquamation has more significance, therefore, in differentiating scarlet fever from other affections than from these exfoliating erythemata.

It may be true that the amount of scaling in a rash of given intensity is more pronounced in scarlet fever than in most rashes which simulate it; but exception must be made of desquamative scarlatiniform erythema,

Digitized by Google

which not infrequently causes an exfoliation of the skin in large areas, leading on the palms and soles, to the throwing off of the epidermis *en masse*. This occurs very rarely in scarlet fever.

Too much importance has been attached to the mere occurrence of desquamation in scarlet fever; the time of the onset of scaling, its mode of progression and its persistence are of more diagnostic importance.

Desquamation in scarlet fever is usually observed first on the face. This is often seen from the fourth to the sixth day. About the sixth day the same process is noted on the neck and upper portion of the chest. The hands ordinarily begin to desquamate from the twelfth to the fourteenth day. On the feet scaling may not commence until the third week.

Scarlatinoid eruptions, in my experience, begin to scale more quickly, particularly on the hands and feet. I have seen a well-marked scarlatiniform eruption occurring in smallpox lead to exfoliation of large pieces of the palmar and plantar epidermis on the sixth day. I believe also that scarlet fever scaling persists longer than scaling after scarlatinoid rashes. I should not insist on the correctness of this observation, however, as scarlet fever patients are scrutinized more closely and for a longer period than the non-scarlatinal cases; minute desquamation would thus be detected for a long time in scarlet fever and overlooked perhaps in other conditions.

A form of scaling which is commonly seen in scarlet fever, is that which begins just beneath the free border of the finger nails, extending thence down the fingers and exposing to view the new pink epidermis beneath. This appearance is so frequently present as to be suggestive of the disease.

DIFFERENTIAL DIAGNOSIS.

Among the affections which are to be distinguished from scarlet fever, the most important are those grouped

Digitized by Google

under the designation of *erythema scarlatiniforme* or *scarlatinoides.*

This affection, if it may be called such, is characterized by an eruption which may be quite indistinguishable from that of true scarlet fever. It may be diffused over the entire cutaneous surface, and may be punctiform. It is often sudden in its onset, and may be attended with malaise and moderate rise of temperature (100 to 102 F.). Occasionally the initial pyrexia is higher, but under such circumstances it soon declines. The throat may be reddened, but there is no swelling of the tonsils and usually no complaint of sore throat.

The eruption has about the same duration as that of scarlet fever, although it is often briefer. It is followed by a desquamation, which is ordinarily branny, but which may take place in large flakes.

Desquamative scarlatiniform erythema, termed by some writers *acute exfoliative dermatitis,* differs from the above type in degree rather than in kind.

It is characterized by the appearance of an extensive, often punctiform erythema, which rapidly covers the entire body, and is accompanied by more or less febrile disturbance. In the course of three or four days the skin begins to desquamate profusely, being thrown off in large lamellæ or sheets. Epidermal casts of the palms and soles, looking not unlike gloves or slippers, may be exfoliated. The nails may be lost, and in severe cases the hair also. Before the skin has returned to its normal condition a relapse may occur characterized by fever, erythema and a second desquamation. In some cases three or four such relapses may take place.

This type of the disease is peculiarly prone to recurrences, which may appear every six months or a year. Sometimes marked periodicity is exhibited, the recurrent attacks developing with almost calendar precision. Doubtless many of the cases of scarlet fever recorded in the literature of the subject, which are alleged to have

Digitized by Google

recurred five, six or more times, were in reality cases of scarlatiniform erythema of the desquamative type.

Fig. 2.—Epidermal casts of palms and soles from a case of dermatitis exfoliativa.

These eruptions are due to toxic or septic states, or to the action of drugs or sera. Simple scarlatiniform

Digitized by Google

erythema may occur during the course of various infectious processes, such as rheumatism, septicemia (puerperal or other forms), pyemia, malaria, typhoid fever, etc. An evanescent scarlatiniform rash may appear before the true exanthem of measles, varicella, smallpox and vaccinia.

All grades of scarlatiniform erythema may develop during the stage of decrustation of smallpox.

Diphtheria antitoxin and other sera may produce scarlatiniform rashes, which bear the strongest possible resemblance to scarlet fever.

The drugs which most commonly give rise to scarlatiniform eruptions are quinin, mercury, belladonna and salicylic acid.

Many other medicaments occasionally produce scarlatinoid rashes in susceptible subjects. The eruption resulting from the administration of quinin is the most frequent and the most likely to be confounded with scarlet fever. It may be followed by well-marked desquamation.

It is often a matter of great difficulty to differentiate scarlatiniform erythema from true scarlet fever. In the former the invasive symptoms are often extremely mild; the patient commonly does not complain of feeling ill; the temperature elevation is slight, perhaps 101 or 102 F. The throat may be reddened, but the tonsils and uvula are not swollen, and exudate is not present on the tonsils. The reddened papillated tongue is, as a rule, absent. The eruption may begin on any portion of the body; it may be patchy or irregular, or it may be diffuse, with or without punctation. The glands at the angles of the jaws are not apt to exhibit any pronounced enlargement; albuminuria is rare and otitis media does not occur.

It is thus seen that scarlatiniform erythema may be readily distinguished from a well-pronounced attack of scarlet fever; but the fact must not be overlooked that there are many mild cases of scarlet fever in which the

Digitized by Google

fever is slight, the eruption poorly marked and the other symptoms correspondingly uncharacteristic.

The significant feature in scarlatiniform erythema, particularly when the rash is well pronounced, is that the intensity of the eruption is out of all proportion to the amount of constitutional disturbance. There is not present the prostration and high fever which would accompany a rash of similar severity in scarlet fever. Furthermore, there is never seen in scarlatiniform erythema a severe sore throat.

Another point of great diagnostic importance is the history as to previous attacks; the tendency to recurrence is a well-recognized feature of scarlatiniform erythema.

It may be remarked, in conclusion, that a proper sense of proportion must be cultivated in formulating the diagnosis of an obscurely developed disease. The various manifestations constituting the composite symptomatology of scarlet fever have each a relative value and their presence or absence must be given due weight in the conclusions that are drawn.

DISCUSSION.

Dr. William T. Corlett, Cleveland—In my experience the strawberry tongue, which is quite characteristic at a certain stage of scarlatina, often develops so late that it is of little value as a diagnostic point. The tongue is often very much coated, and sometimes it has been two days before the coating has been sufficiently removed to make the picture of strawberry tongue complete, and in the meantime the rash has made its appearance. I agree with the essayist as to the difficulty in making a differential diagnosis between false scarlet fever and the true disease, and also in the recognition of many of the less frequent types of scarlet fever.

Digitized by Google

A COMPARISON OF PHOTOTHERAPY, RADIOTHERAPY AND HIGH-FREQUENCY THERAPY IN SKIN DISEASES.

C. W. ALLEN, M.D.

NEW YORK CITY.

Unlike the lawyer who, in the preparation of his brief, has his precedents behind him, the physician who attempts to write on treatment by light and rays and the newer electrical currents of the day has most of his precedents ahead of him. What to-morrow can bring forth no man may know. What the near past has revealed to us is sufficient to cause us to pause in wonderment and admiration. Were not my task sufficiently arduous in attempting to compare methods between which there often seems to be so little comparison, I would gladly dwell on the marvelous things which each method has accomplished in its own peculiar sphere. What the Röntgen ray is capable of in a therapeutic way takes it out of the realm of doubtful test. It can no longer be said to be an unknown quantity. Since, too, the position of the ray in the spectrum has been pretty well determined, its original designation, modestly given, should be dropped. The quantity of its position and power is no longer unknown. Let us consider it as the Röntgen ray.

Each of the three modes of treatment mentioned in the title has its own peculiar field of utility. Each has its more or less distinct limitations, and each is susceptible of enhancing the value of the other when judiciously combined, or employed in succession. The statement so

Digitized by Google

often made that in light treatment we are dealing with a known quantity, while with the ray we have an unknown quantity of uncertain action, is not so forcible an argument as it was a short while ago. With the advances in ways of measuring the dose, the dangers of undesired deep effects and sloughing from Röntgen rays have been practically done away with.

It may be said that in each separate application of the light treatment a "burn" results. By this term we mean the pronounced reaction without which little therapeutic result is secured. With the ray serious skin lesions can be destroyed without the slightest redness from the ray ever showing on the skin. In destroying neoplastic growths by means of the high-frequency spark a reaction occurs, too, if prompt and pronounced results are anticipated. It is, perhaps, as much entitled to the designation "burn" as is the ray effect of similar degree, though naturally much more circumscribed as a rule. In a general way, it may be said that arc-light therapy is limited to a few skin diseases, and that for certain countries where lupus is not common the limitations are very restricted. If my opinion should be based on my personal experience alone, I should unhesitatingly say that the ray would accomplish for lupus all that the light would, and this, too, more expeditiously.

It must be remembered that nowhere outside of Copenhagen, and perhaps London and a few other places, is the method carried out in all its details in a way to warrant anyone drawing comparisons. Nor must the results obtained from small modifications of the original apparatus be taken as a basis of judgment.

The ray is capable of intensifying the actinic reaction, and the high-frequency current hastens the *restitutio ad integrum* when the ray has produced too severe reaction.

On mucous membranes the ray has a decided advantage over the light.

Digitized by Google

COMPARISON OF THE TWO METHODS.

In making a study of the relative merits of radiotherapy and phototherapy it seems at the present time necessary to consider only a few diseases as they are influenced by the Röntgen ray and by the actinic rays, as applied by Finsen and his followers.

First, we must appreciate the wider range of usefulness of the Röntgen ray, which is not restricted wholly to surface influence, as seems to be the case with the ultraviolet light. To be sure, the results have so far not been brilliant in many internal or deep-seated affections, but that the *x*-ray produces a pronounced action on deeper tissues can not be doubted.

In the treatment of lupus much stands in the way of definite conclusion at the present time concerning the relative merits of *x*-ray and actinic light. There is the personal equation, with individual preference, greater experience and greater skill with the one than with the other. Phototherapy has been perhaps more profoundly studied, and more cases have been treated to a point of cure.

That the Röntgen ray has a great influence on lupus tissue there can be no doubt. Many have been cured. The proportion of failures, so far, has been greater than in the other method. We must remember, however, that the greatest success has been achieved by the originator in Copenhagen. If we compare lupus treated by the two methods the world over, the difference in end-results is not so marked.

The chemical light penetrates deeply, homogeneously, and pains less; herein lies its advantages over older methods, granting that end-results are equal. In point of time, this method has the advantage over the older when we calculate the period over which the others, exclusive of ablation, must extend.

A careful computation of statistics points to phototherapy as the method offering the largest percentage of actual cures.

Digitized by Google

The advantages of the x-ray as compared with the actinic method in the treatment of lupus are that (1) we can treat larger areas; (2) it is much more effective in ulcerating lesions; (3) we can treat lesions of the mucous membranes; (4) the treatment is much shorter in duration.

The x-ray is more uncertain; the dosage is not so well established or controlled; the limitations are not so well mapped out, and harm can more readily be done.

Reports, although numerous, represent too large a proportion of cases which have "improved." Naturally, we can consider only those discharged or reported by competent observers as clinically cured. In this country, at least, where lupus is rare, and presumably in others as well, statistics must be based on the competency of the observer from the diagnostic side. Reports have been made of lupus treated by these methods which were not lupus at all, but syphilis or something else.

There is one feature of radiotherapy to make it of decided advantage, and that is entire absence of pain or discomfort, and the much-restricted number of applications required.

Among other advantages of the Finsen method are that it is not very dangerous to the operator, while the x-ray has been known to produce serious results. While the actinic is the more tedious treatment, it has the advantage that it can be carried out by trained or semi-skilled persons—nurses, etc. This is not so practical with the x-ray, which should be under the direct supervision of the physician.

In epithelioma, curettage should be employed coincidentally with either of these methods.

The actinic ray reaction is apt to come on, if at all, in from four to five hours, and the resulting slight dermatitis, resembling that produced by the sun's rays, is usually readily controlled by some simple application.

The dermatitis following the x-ray comes on only after some days, or even weeks, and the extent and ulti-

Digitized by Google

mate results are very uncertain. The reaction, when severe, is not controlled by ordinary methods of treatment.

The actinic treatment is less likely to produce burn than the x-rays.

The resulting cicatrix after phototherapy is softer, whiter, and generally better, as a rule, though most excellent scars often follow radiotherapy.

The effect of the chemical rays is very irritating on the conjunctiva and the retina, while the x-rays exert very little effect.

The use of amber-colored and red-colored glasses and the use of dark red shades at the windows will lessen the irritation in case of inflamed eyes. Blue glasses, however dark, are found unsuccessful.

Leredde and Pautrier[1] make a comparison of the results obtained by phototherapy in lupus vulgaris and lupus erythematosus with those following other methods of treatment. They conclude that phototherapy is the one method which gives the best results in tuberculous lupus, giving deepest action, although radiotherapy may in the future be found just as useful. While a cure can not always be promised, the number of failures is small. In lupus erythematosus this method of treatment is superior to all others, although the results are much less constant than in tuberculous lupus. It is necessary to produce complete sclerosis, and the phototherapy should be continued until a cicatrix is formed. The indications and contraindications for the employment of this method of treatment are as follows: It is indicated in every case of tuberculous lupus which has resisted other methods of treatment. The results are uncertain in cases with much thickening of the tissues and in those in which a deep sclerosis has been produced by other treatment. In vegetating lupus the volume of the tissues should first be reduced by scarification or caustics. In elephantiasic lupus this method of treatment generally

1. Annales de Dermat. et de Syph., 1902, No. 8.

Digitized by Google

fails. It is contraindicated in recent lupus, which can be cured by ablation with union by first intention; and in lupus of the trunk and extremities, which can be cured more rapidly by other methods. In tuberculosis of the extremities it is likewise inapplicable because the hyperkeratosis and acanthosis prevent the penetration of the chemical rays. In lupus erythematosus it is contraindicated in the superficial wandering forms curable by other methods. It can be applied only in those cases in which the disease reappears in the same places, and in which other methods have failed. In the fixed forms, with or without a tendency to atrophic regression, it may be employed after the failure of other remedies. Every case ought to be treated energetically from the beginning, since the longer it lasts the deeper and more rebellious it becomes. In those cases which have resisted phototherapy, properly carried out, radiotherapy or radioactinic therapy may be tried.

In skin diseases in general the field of usefulness for *x*-rays is much broader than for Finsen's method. Here the lesions must be few and localized, while the ray can be so applied as to take in extensive surfaces, or the entire body, as in mycosis fungoides.

LUPUS.

In two cases of lupus with marked ulceration treated by Morris,[2] Finsen's method was found useless, but in both the ulcers healed rapidly under *x*-rays. When the mucous membranes are involved the *x*-ray gives good results. That of the nose is attacked with difficulty by the ultraviolet rays, but very easily with the *x*-rays. Many cases of lupus under treatment by either method improve up to a certain point, but stop short of a complete cure, so that whichever is used it must be supplemented by some of the older methods.

Scholtz, who has had a very extensive experience, covering a number of years, with the *x*-rays in all varieties

2. Practitioner, April, 1903.

Digitized by Google

of lupus, in his report of 55 cases claims to have brought about a complete cure in the majority in a very few months, with very satisfactory cosmetic effects. This seems to compare very favorably with the actinic method, which requires a much longer time, with much more inconvenience to the patient as regards the comparative length and frequency of exposures.

Freund says much the same length of time is required in the two methods; the resulting scar is equally good. He advises raying large surfaces and applying actinotherapy to remaining foci.

Heidingsfeld[3] speaks of three cases in which the ray had failed, but under the London Hospital or Sequeira lamp the nodules disappeared.

Harrison and Wills[4] found that, while two out of three lupus erythematosus patients improved under actinotherapy, they made more rapid progress under the x-rays.

Sequeira, of the London Hospital, believes from a trial of both methods that the actinic gave better results. Out of 154 cases treated by the latter, 42 were successful.

Leredde and Pautrier report on 40 cases. Of these, 37 remained under treatment sufficiently long for conclusions to be drawn; 8 were cured, 7 nearly cured, in 10 definite areas were cured, and final cure was seemingly sure from actinotherapy.

At first it was believed that the beneficial action of the chemical light in lupus was mainly due to the direct destruction of the tubercle bacilli by this light, and that the light reaction was only of minor consideration.

But careful investigation seems to show that the destruction of the tubercle bacilli is mainly due to the reactive inflammation of the tissues, the increased blood flow, or to the eventual chemical changes taking place, and not to the direct action of the light.

---

3. Cincinnati Lancet-Clinic, 1908, vol. lxxxix.
4. Bristol Medico-Chirurgical Journal, 1908, vol. xxi.

Digitized by Google

Nagelschmidt believes that the destruction or weakening of the tubercle bacilli through the direct action of light is the first result, and that only after this is accomplished the light reaction becomes an issue by facilitating absorption and assisting in the regeneration of the tissues.

For the most successful results it is necessary that the patch should be dry, and the lens be pressed hard against it.

If, by the use of the *x*-rays or with the aid of applications of various medicines, an ulcerating lupus can be dried up, then treatment can be continued with the actinic light.

From November, 1895, to January, 1902 - (seven years), 804 cases were treated in the Finsen Institute; 412 were cured, of which number 124 showed no recurrence in from two to six years, and of which 288 had been free from recurrence for a period of less than two years. Of the remainder, 192 were nearly cured and 117 remained under treatment. In 67 the treatment was interrupted by death, illness or other cause, leaving 737 for study. Of these the result was favorable in 695, unfavorable in 42, or 6 per cent., against 94 per cent. of good results. At the St. Louis Hospital in Paris Gastou-Baudouin and Chatin[5] report 30 cases, with 7 failures, 12 partial cures and 11 complete cures. Leredde and Pautrier[6] give 43 cases, 8 of which were cured, 7 almost cured, with 28 still under treatment. In a recent visit to Paris I had the privilege of seeing the work being done by Gastou and Leredde, among others. At the Broca Hospital I found my friend Professor Brocq operating by the well-known methods of ante-Finsen days on a number of lupus patients in whom the light had been successful up to a certain point, but beyond which it seemed incapable of producing further benefit.

5. Annales de Dermat. et de Syph., April, 1902.
6. Phototherapie, Paris, 1903.

Digitized by Google

Such instances illustrate the point on which I have previously dwelt in former publications, that these methods are not to be relied on exclusively, but must often be fortified by other measures.

Malcolm Morris reports on 65 cases, 11 of which were cured, no relapse taking place in from six months to two years. In 15 cases slight remnants have remained or relapses have occurred; 15 are still under treatment. All patients remaining sufficiently long under treatment were improved.

Forchhammer found that out of 456 patients treated, 130 showed no recurrence during an observation of from one to five years. These are undoubtedly included in the larger statistics of Finsen.

Harrison and Wills report on 42 cases being treated by the Lortet-Genoud lamp. Almost all were improving at the time of report.

In the London Hospital 398 patients have been treated, with 149 discharged as cured, up to 1903.

At the St. Louis Hospital in Paris, up to May, 1903, when I visited the laboratory of Professor Gastou, 250 patients had been treated, and about 100 were reported as cured.

In lupus erythematosus the *x*-ray gives at least as good results as phototherapy. Compared with high frequency and radium therapy, too few data are available, but excellent reports have been made on the high frequency.

As between phototherapy and radiotherapy, on the one hand, and older methods (application of iodin, pyrogallol, caustic potash, strong carbolic acid, chlorid of zinc, scarification, galvanocautery), on the other, the newer methods have the decided advantage.

ALOPECIA AREATA.

Here the time element must not be ignored in forming final conclusions. The well-known tendency for many patients to make spontaneous recovery should not confuse the observation.

Digitized by Google

When a recent case responds promptly to chemical light we may credit the method with the result.

The conditions of control have been complied with in a number of instances, including Finsen's own cases (49, with 30 cures). Sabouraud believes, and we must lean to his way of thinking, that the irritation produces the equivalent of that we aim at in our older methods. In my own practice I have experienced little difficulty in the non-universal cases in securing renewed hair growth within comparatively short time-limits with pure carbolic applications at long intervals (three or four treatments in six or eight weeks). This is surely much simpler, more time-saving and inexpensive.

Localized chronic plaques which resist this and similar measures will sometimes give way under chemical light or *x*-raying. Comparing the latter, it would seem that more patients have so far recovered under radiotherapy.

EPITHELIOMA.

Here the *x*-ray is unquestionably superior, though the arc lamp will cure lesions of the cancroid and rodent-ulcer type.

When we compare the number of patients treated for lupus by actinotherapy with those treated for epithelioma, the reports so far available seem insignificant as compared with those reported on from radiotherapy.

Among the reported results are Forchhammer's 24 cases from the Finsen Institute, with 11 cures; Sequeira's 3 successful cases; Burgdorff's 8 cases, with 3 reported cured and 4 improved. My personal experience with exclusive actinotherapy in cancer has been slight. In several instances actinic rays have been tried for a time, but given up in favor of the *x*-ray, whose effects seemed more prompt and satisfactory.

Malcolm Morris reports 27 cases of rodent ulcer in which the *x*-rays were also employed. In 12 there were favorable results, but it is difficult to assign to actinotherapy its exact share in the cures.

Sjögren had 10 cases of rodent ulcer, with 5 cures.

Digitized by Google

In carcinoma Finsen's statistics show 17 patients, with 8 good and 2 fair results.

SYCOSIS.

While ultra-violet rays have been tried with some success, as in long-standing sycosis of the upper lip (Leredde, 2 cases), the method falls far short of the brilliant results following radiotherapy.

HIGH FREQUENCY CURRENTS.

As a result of a close clinical study of over 250 skin affections treated in my office by high-frequency currents, the following conclusions can be drawn: (1) I am convinced that in a comparatively large number of dermatologic affections the local action of high-frequency currents aids in their cure. (2) In a limited number of patients in whom nutrition is at fault, D'Arsonvalization or autocondensation helps to bring about a prompter removal of local lesions. (3) In parasitic affections, while it has an influence, I have not been able to convince myself that the results are prompter or better than in older methods. (4) That the broadest field of usefulness is in the markedly pruriginous affections, and in those intimately connected with the nervous system and associated with pain. (5) An important, and, as I believe, a growing sphere, is that filled by the high-frequency spark in the almost painless destruction of the small neoplasms, including nevi, moles, warts, tumors and malignant growths, as well as in lupus and lupus erythematosus. (6) Compared with the Röntgen ray, skin affections as a whole are less benefited by these currents; but the two methods often enhance each other's influence.

Basing general conclusions on nearly 450 personal cases, beside the 250 mentioned as having been subjected to high-frequency currents, I think the following statement may be made:

CONCLUSIONS.

1. In the vast majority of cutaneous affections the Röntgen ray is of greater utility than either the actinic or high-frequency methods.

Digitized by Google

2. In lupus the Finsen method, though tedious and disagreeable, is efficacious. The combined ray and high-frequency spark may prove to be equally good.

3. The actinic method is less beneficial in cancer than the Röntgen ray.

4. The high-frequency method is exact, no more disagreeable than the actinic, and for small lesions of epithelioma, lupus, lupus erythematosus and many skin diseases gives quicker and better results.

5. All three can be advantageously combined for the different stages and phases of a large class of affections.

30 East Thirty-third Street.

DISCUSSION.

Dr. W. T. Corlett, Cleveland—A little over a year ago I visited some of the dermatologic centers of Europe, starting with Copenhagen, where, through the courtesy of Professor Finsen, I had the opportunity of studying the light treatment and of becoming familiar with the Medicinske Lysinstitut. I remained there eight days, which enabled me to observe some of the results of his treatment. Some of my conclusions on leaving Copenhagen were that in lupus erythematosus the Finsen light was superior to the Roentgen ray, and gave better results in a greater number of cases; in fact, I thought it the best method I had seen. The second disease, which was especially well treated, was vascular nevus. In two cases of this disease observed, one was practically cured, and the other, which was still under treatment, about half of the area having been gone over showed better results than I had seen by any other method. Through Germany to Vienna I saw the Finsen light used in almost all the hospitals, and very badly used in most of them, especially where nurses were subsidized to apply the treatment. Finsen is very particular that the light is accurately focused on the area to be operated on. One of the most interesting experiences in this connection was Lang's clinic in Vienna, where three methods were employed in treating lupus vulgaris: first, came a group of cases under treatment with the Roentgen ray, another group treated with the Finsen light, and the third class of cases under the older surgical procedures. Every Friday the progress made in these cases was compared. No definite conclusions had been arrived at as to the advantage of one or the other form of treatment. In Paris one hears of many improvements in the Finsen light, but the results I saw were not good, and the so-called improvements in the appliances were, in my opinion, inferior to those used in Copenhagen. In London, where, next to Copen-

Digitized by Google

hagen, the light is best given, I saw many of these modifications of the Finsen light apparatus relegated to the garret, where they were dust-covered and unused. Briefly, the impression gained after months of careful study and comparison was that the most efficacious rays were those found in the the Finsen light as originally given out, and that the instruments made in Copenhagen, although inferior in mechanical construction, are the best procurable at present. Moreover, I believe of the two methods the Roentgen ray has the larger field of usefulness. As regards mucosus fungoides and its treatment, in Vienna I saw one-half of the body exposed to the Roentgen ray, with complete subsidence of the disease on one side, the unexposed side being unaffected. I have used the *x*-ray in one case of mucosus fungoides now under treatment at Lakeside Hospital, with apparently good results, so far as the individual lesions are concerned.

I would like to ask Dr. Allen if he has actually found the high-frequency current beneficial in *x*-ray burns. How long, in the case referred to, was the *x*-ray burn in healing? Some of us, I know, have had experience with *x*-ray burns that have lasted almost indefinitely. We have all seen cases of syphilis treated with the Roentgen ray, and other most ridiculous mistakes are constantly being made.

I have used the high-frequency current for about two years in lupus erythematosus, at first with some improvement in the cases thus treated, but, as I previously stated, the disease goes away of its own accord, at least in all of the cases thus treated the disease has promptly returned. In alopecia areata I have used it as a counter irritant. In acne I have used it in the same way, as a stimulant, and some cases seem to get well, but any other stimulant might act equally well. In pruritus it has failed to allay the itching.

Dr. W. S. Gottheil, New York City—I would emphasize the absolute harmlessness of the Finsen method; I have never seen it do any damage to the patient or to the operator, and I have employed it extensively. There is no doubt at all that the concentrated light of an effective arc not only penetrates the tissues, but can be made to traverse the entire body. I published the results of my experiments in the *Medical Record* last year. I must protest, however, against the results published by operators using small and inefficient light sources. Power (amperage) is required for penetration and therapeutic effect. Arcs running on less than 40 amperes are useless; I employ 50 to 60, and Finsen and his collaborators now use 100 ampere arcs. No satisfactory results can be gotten on arcs of 10 or 15 amperes, and the machines using incandescent bulbs, no matter of what candle power or in what combination, have next to no actinic power at all, and are merely diaphoretic agents. Actinotherapy has a place in cutaneous

Digitized by Google

therapy, but results or non-results claimed to be obtained by measures that are manifestly useless should not be credited to the actinotherapeutic method.

Dr. M. B. Hartzell, Philadelphia—We formerly heard a good deal about the necessity of accuracy of dosage, but in the use of this remedy, as in others, it is not so much the size of the dose as the effect produced. We all know how much remedies differ in effect on various individuals, so with this; in one individual you obtain a decided effect after a few exposures, in another almost no effect after a great many exposures. While it is necessary to be careful that we do no harm we must employ the remedy for a certain effect, not to give a certain dosage. There is no doubt that in this remedy, as in all others, accuracy in dosage is desirable. The remedy is being employed in every sort of disease; every kind of disease is being reported as cured; for example, I may refer to alopecia areata. We all know how promptly the hair will sometimes fall out after the employment of this remedy, and it seems curious that we should employ the same remedy to promote the growth of the hair. I have doubts as to whether this remedy should be tried in a case of alopecia. Ordinary alopecia, we all know, is capricious and the hair may return after a few months spontaneously, but if the Röntgen ray has been tried it gets the credit for something with which it had nothing to do. As to the use of the Finsen light in this country, where lupus is a rare affection, its employment is restricted. It requires a tremendous length of time, and the area treated at each sitting is comparatively small. As to the final result there is very little difference between the x-ray and the Finsen light; you can obtain as satisfactory results from a therapeutic and cosmetic point of view with the former as with the latter.

Dr. M. H. Baum, Syracuse, N. Y.—In regard to the possible frequent error in diagnosis, where syphilitic lesions have been considered to be of the nature of lupus; in one instance a patient called on me just before taking a train for New York, having a large ulcerated lesion over the right brow. The impossibility of doing justice to the case in the limited time given, led me to refer her to a colleague in New York, and I am quite sure he made an error in diagnosis, considering it lupus. He applied actinic therapy, thirteen treatments, during which time the disease progressed. On her return a careful investigation disclosed the fact that she was a specific patient, and had elsewhere on the body other lesions of syphilis. The ordinary constitutional treatment cleared up this trouble. An opposite experience was a case of very extensive ulceration involving the lower occipital region and both sides of the neck, that applied to Dr. Weigel of Rochester for treatment. A diagnosis had been made of tubercular ulcer, and while he

Digitized by Google

did not concur in the diagnosis he used the x-ray, with the result of healing these ulcers quite promptly. In this case the re-growth of hair was illustrated. The patient's hair below the occipital region was entirely removed, and no follicles could be seen. I have seen the patient within a few days, and the most luxuriant hair on her head grows from the patch made bald by the x-ray. The case was seen afterward by Dr. Hyde and others, who agreed that it was specific, and while these lesions healed under the x-rays, new ones would break out. She finally recovered under strong antiluetic treatment. The germicidal value of high-frequency currents was shown in a case of bubo which had been opened by my assistant. Cultures were made from the secretion, showing a tremendous variety of pus germs, particularly the staphylococci. It was teeming with them. The interior of the bubonic tissue was treated directly with the high-frequency electrode. After the second treatment another culture was made, which was negative, and in a few days this tremendous ulceration healed entirely, and at no other time was it possible to get a culture of any sort. No other germicide was used. I have treated one case of pruritus of the scrotum which was of 20 years' duration, where the scrotal tissues were leathery and thickened; I never saw a case so extreme. This patient has had no other application than the high-frequency current, and there is entire regeneration of the tissue and recovery. There is no more pruritus nor distress and the tissues are normal.

Dr. Jay F. Schamberg, Philadelphia—We have been using actinic rays of light in the treatment of cutaneous diseases at the Philadelphia Polyclinic for about a year and a half. The lamp in use is the London Hospital lamp. A number of cases of lupus vulgaris and lupus erythematosus have been faithfully and perseveringly treated. Some have received as many as two hundred treatments. The results in lupus vulgaris have on the whole been disappointing. While improvement was noted in some cases it was not pronounced enough to warrant the time, trouble and expense involved. I am firmly of the opinion that these various modified lamps, of which the London Hospital lamp may be considered a type, do not produce sufficient penetration to cure deep-seated and long-standing lupus lesions. A pronounced superficial reaction amounting to actual blistering may be secured by exposures of an hour or an hour and a half, but we have repeatedly treated lupus nodules in this manner without effecting their disappearance. With the x-rays in lupus vulgaris brilliant results are often obtained. But all cases of lupus vulgaris do not react equally well to the rays. Indeed, some cases appear to be but little influenced by them. In the present state of our knowledge it would appear that the best treatment for lupus vulgaris is the Finsen light, applied, however, with a powerful lamp. The

Digitized by Google

x-rays, I believe, are to be preferred in lupus of the mucous membranes, in lupus accompanied by ulceration and in papillomatous cases. In one case of lupus erythematosus with pronounced vascular dilatation great improvement has followed the use of actinic light with the London Hospital lamp.

Dr. C. E. Skinner, New Haven, Conn.—In reference to the remark which was made a few moments ago that the *x*-rays should never be recommended as a remedy for falling hair, I would like to say that although, as a rule, the application of the *x*-ray will cause the hair to fall out, and if it is repeatedly killed in this way that it will after a while fail to come back, yet it is not such a very uncommon thing for those who use the *x*-ray extensively as a therapeutic agent to see the growth of hair very noticeably accelerated on parts which have been exposed. In a case in which the neck was being radiated for enlarged cervical lymphatics, after treatment for several months there appeared on the side of the neck radiated a growth of hair an inch and one-half long where normally there had been nothing but very rudimentary hair structures. This case will soon be reported. I do not feel competent to state whether or not the *x*-rays should be recommended as a remedy for alopecia, but the stimulation of the growth of the hair which has been so often reported and which undeniably obtains in so many cases, should be given due consideration before the measure is unqualifiedly condemned as a remedy for this condition.

Dr. A. E. Currier, Detroit—Regarding the recurrence of hair after its destruction by the *x*-ray, I have a patient suffering from mycosis fungoides and after raying the whole body he said his daughters made the statement that his hair was getting thicker and becoming darker in color, and such was the fact. There were a number of lesions on the forehead and I took no pains to protect the scalp. Another case was one of lupus, and the first case from which I got quite a severe burn in the use of the ray. A large patch of alopecia resulted, but the hair has returned, which I think is usually the case after the use of the *x*-ray. In my experience the use of the ray on the mucous membrane has not been very favorable. In a case of lupus, where the ray was applied to a lesion on the conjunctiva, no effect was produced. The eyeball became affected and was removed. In spite of this and a number of curettements, the lupus lesion still remains in the orbit, while a number of patches of the diseases have entirely disappeared from other parts of the face. I would ask Dr. Allen to give us his technic of the high-frequency current.

Dr. H. R. Varney, Detroit—In order to get prompt results in most skin affections under the light treatment it is impor-

Digitized by Google

tant that we curette the area or perhaps apply arsenical paste to remove masses, and then push the light treatment, whatever it may be, as rapidly as possible without necrosis of the new tissue. We have all seen cases where the lesion treated after becoming accustomed to the ray has come to a standstill, so I would emphasize the importance of pushing as rapidly as possible any light treatment. As to *x*-ray dermatitis, the cases I have seen where there has been necrosis have been in alcoholics. There seems to be very little cell resistance in alcoholic patients, and the most destructive burns I have seen have been in this class of cases. As to medication for dermatitis, I have found none that would relieve the condition, but, on the contrary, would aggravate the existing dermatitis. My course in dermatitis, wherever developed, is to see the patient every other day and give a short treatment with the ray, not stopping my treatment altogether, but give a mild two, three or four-minute treatment with the ray, and I can check the dermatitis that way better than with any local treatment and allowing the patient to go away and perhaps fall into the hands of some other physician, with the burn. This I make as an important point. In my early experience I would allow a patient to stop all treatment with a burn of the first or second degree, but now I believe it is possible to check those conditions by mild treatment with the tube further away and shorter duration. My experience with the high-frequency current is of little interest, as I have used it but a short time.

Dr. L. Duncan Bulkley, New York City—Referring to a point made by the last speaker, I have seen great benefit in mild *x*-ray dermatitis from its continued, and even rather frequent use, every few days, in a very mild degree. I do not know why I first suggested it, but on seeing the dermatitis, partly to keep up the effect and partly hoping that all would go well, I said, let us try two or three minutes at a greater distance of the tube. I did not see any indication for stopping it entirely. The gentleman also remarked that he did not find anything else to control it. I find that a 25 per cent. watery solution of ichthyol painted over an *x*-ray burn makes it more comfortable, and I think helps heal it more quickly. I also use an ichthyol ointment. I know personally of the brilliant results from the light treatment of lupus in Copenhagen, but the same results are not often obtained elsewhere, partly because many attempt to make the treatment with too short and severe an application, and thus get the external effects before the light has penetrated into the deeper tissues, and the lupus develops again because it has not been radically destroyed. In regard to the use of high-frequency currents, I think that we are just beginning to know what they will do. I do not know whether many of you have tried the high-frequency currents, with a carbon point, on vascular nevi. I have had two very

Digitized by Google

striking cases. One was in a young girl who was several months in the hospital, and the results of the treatment of a port-wine discoloration which affected a large share of the face were certainly remarkable. The other case is still under treatment. Certain portions beneath the eye which we have treated are to-day normal and at ordinary talking distance you would not notice any redness. I burn the surface a little with the carbon point, so that there is almost a vesicle formed; the destruction goes just deep enough to alter the tissue and yet leave practically no scar. Time and again it is done, very superficially at first, subsequently going a little deeper. I am thoroughly satisfied with the portions which I have treated. In pruritus the high-frequency current is very valuable in relieving an itching dermatitis. I do not know how many of you have used the high frequency for warts, especially of the scalp, where they are sometimes very annoying. The carbon point, with high frequency, is applied to the wart until it is blistered, and there is a little hemorrhage, and the wart then dries up, and when the crust has fallen, in a few days, the surface is level. Two or three applications may be necessary.

Dr. C. W. Allen—Dr. Corlett's question brings us to the subject discussed by Dr. Hartzell, whether the high-frequency current is of any benefit in *x*-ray dermatitis. In a general way, it is. Not only in the superficial second-degree burn, but also in the ulcer which has resisted other measures for a long time, and I base this view largely on the treatment of one particular case. It was a deep-seated lesion supposed to be a cancer of the liver, sent to me by Dr. Waldo, who asked me to treat it for him. I accepted the diagnosis; it looked to me like cancer of the liver, and I began to treat the woman. After treating her for some time she suddenly developed a very pronounced necrotic burn. When I left for Europe last March I gave her a note to a colleague, asking him to excise the ulcer. She had a pendulous abdomen, the tumor had gone down so, and the ascites had disappeared so that there was room for excision. On my return from Europe I found she had not presented herself to this gentleman, and not hearing from her I mourned her as dead; I thought she was entitled to die from her carcinoma and dismissed her from my mind. A short time ago, on entering my waiting-room, there she sat, looking very much better than when I last saw her, and she said she was much better; said she had done nothing since, but had stayed at home and consulted no one. The burn had healed about the margins, presenting the picture with which you are so familiar, an ulcer in the center covered with a persistently recurring membrane, and showing absolutely no tendency to heal further in spite of various applications, powders, pastes, lotions, etc. (as a rule salves did not do well). I said to my assistant one day, "You start in with the *x*-ray or with the high-frequency cur-

Digitized by Google

rent." Fortunately, he adopted the high-frequency method. I believe that the case was really never cancer at all, but syphilis and she developed a sudden bad burn because of the syphilis. If these tissues will react in that way in alcoholics they will probably do so in syphilitics, and I think in both classes of cases we have to be careful. Under the high-frequency current the ulcer began to pucker and heal up and now it is nearly healed. So I can say in my experience with both classes of cases, the second degree of burn and the third degree of burn, that the high frequency does well.

Digitized by Google

X-RAY THERAPY IN SKIN DISEASES.

G. E. PFAHLER, M.D.

Assistant Physician and Skiagrapher to the Medico-Chirurgical Hospital, Lecturer on Medical Terminology and Symptomatology, and Demonstrator of Physical Diagnosis in the Medico-Chirurgical College.

PHILADELPHIA.

As a basis for this paper, I have selected a few cases which seem to be instructive and illustrative in the treatment of nevus, lupus involving the nares and the interior surface of the lips, morphea, and acne, with hypertrichosis, and epithelioma of the lip.

CASE 1.—Miss B., aged 15, has had a birthmark on the left side of the nose, near the inner canthus of the left eye. During the year preceding treatment it seemed to be increasing in size. It was not elevated and was about the size of a dime.

Treatment.—*X*-ray treatment was begun Jan. 28, 1903. A soft tube was used for a period of ten minutes, at a distance of eight inches, with five amperes of current. Eight such exposures were given during a period of six weeks. At the end of that time a distinct dermatitis was produced, but not to the extent of vesiculation. This was followed by desquamation and disappearance of the lesion. There has been no recurrence after a year.

CASE 2.—Miss M., aged 39, was referred to me by Dr. B. F. Hawley of Philadelphia. She has had a very extensive birthmark, covering almost the entire face, the right side of the chest and the right hand. There had been some increase in the extent of the area involved since birth. Here and there on the forehead and left cheek there are a few small patches of nearly normal skin. On the right anterior portion of the face the affected area is uniformly elevated and thickened. The remainder is not elevated above the level of the surface of the skin. The color was port-wine.

The congestion is increased by cold and by emotional excitement. Under such circumstances it became a distinct purple. Over a great part of the area separate venules could be seen which are closely interwoven.

Digitized by Google

Treatment.—On account of the uncertainty of the outcome and the extensive area involved, treatment was begun only on the hand, March 12, 1903. The same technic was used as in the previous case. Thirty-six exposures were given to the hand during a period of three months. The first effect noticed was a change of color from a port-wine to a deep red. This later faded to a pink, and now is not noticeably different from the surrounding skin except when exposed to cold or during emotional excitement. Another early effect noticed after twelve treatments was the tardy return of blood when it was pressed out of the affected area. The nails became brittle, but these

Fig. 1.

Fig. 2.

Fig. 1.—Case 3. Lupus vulgaris. Before treatment.
Fig. 2.—Case 3. After thirty treatments in eight months.

have recovered to a great extent. There has been no treatment of the hand for a year.

Treatment of the face, on account of the extensive area involved, has not at any time been forced. I treated the face three times a week for two months, then twice a week for a month, and once a week for eight months. She has had sixty treatments in all on the face, during a period of fourteen months. As a result, the color has been changed from a port-wine to a pink, and when the patient is quiet the areas are scarcely noticeable. The thickening of the skin on the right cheek is much less marked, and when the blood is pressed from the affected area it returns less quickly.

Digitized by Google

Jutassy[1] reports good results after producing a dermatitis to the extent of ulceration. Pusey[2] reports permanent improvement after producing an acute dermatitis.

From this method of treatment of nevi, I believe we can expect very marked improvement, but not absolute cure, except when the treatment is carried to the extent of producing ulceration, which is not always advisable.

The improvement will consist of some atrophy and a change of color approaching that of normal skin. This improvement will occur more quickly if a distinct reaction is produced. The boldness with which we may produce a reaction will depend on the location and the extent of the area involved.

CASE 3.—Dr. L. M., aged 40. Referred by Dr. John V. Shoemaker. He has had lupus vulgaris five years, involving the chin, the lips and both sides of the nose, also the inner surface of the lips and the interior of the nose. He had been treated by various measures, principally caustics. It improved at times, but never disappeared.

Treatment.—*X*-ray treatment was begun Oct. 1, 1903. At this time the disease was active on the lips, with a few nodules on the chin, and distinct disease on either side of the nose and on the interior of the nose. The inner surface of the upper lip was also affected. Photograph No. 1 gives a fairly good idea of the extent of the external involvement. Thirteen treatments were given in eight weeks. A soft tube was used on each side of the nose for about eight minutes, at a distance of ten inches, using about four amperes of current.

Results.—At the end of eight weeks decided improvement was noted, and induration only remained at the inner canthus of the left eye and at the right ala of the nose. Since this time he has been treated nearly once a week, with the result that the lupus seems to have disappeared both from the surface and from the interior of the nose, except a small tubercle at the alæ of the nose.

During the course of treatment a bone-like projection appeared at the inner canthus of the left eye and was thought to be an exostosis. This disappeared completely under treatment.

In addition to the disappearance of the active lesions, the scar tissue, which was quite thick and stiff, has nearly disap-

1. Jutassy: Pest. med. Chir. Presse, 1900, xxxvi, p. 73.
2. Pusey: The Roentgen Rays in Therapeutics and Diagnosis. 1903.

Digitized by Google

peared. Thirty treatments in all have been given during eight months. (Fig. 2.)

The treatment was several times carried to the point of a mild dermatitis, such as is shown by an erythema.

The points of special interest in this case were: 1. The disappearance of the lesions within the nose and beneath the lips. 2. The development of what appeared to be an exostosis at the inner canthus of the left eye, which disappeared under treatment. 3. This spicule of bone de-

Fig. 3.

Fig. 4.

Fig. 3.—Case 4. Epithelioma of the lip.
Fig. 4.—Case 4. After operation and α-ray treatment.

veloped during the course of treatment, but in the protection of the eye this portion had been covered.

CASE 4.—Mr. G. R., aged 41. Eleven years ago he had what he called a fever blister on the lower lip, which lasted two months. Two years ago a similar sore developed on the lower lip, which has progressively increased in size. It had been treated with caustics by a layman.

Treatment.—*X*-ray treatment was begun April 25, 1903. At this time he had an epithelioma on the lower lip about the size of a walnut, which had ulcerated. The submaxillary

Digitized by Google

glands on both sides were enlarged and hard. He had lost weight and was somewhat cachectic. (Fig. 3.)

The x-rays were applied to the growth and to the submaxillary glands. He was given ten treatments during the first month, lasting ten minutes each, with the tube ten inches distant, a two-inch vacuum, and about five amperes of current.

At the end of the first month the growth seemed to be smaller, and the glands were smaller. During the second and third months ten treatments were given. At the end of the third month the growth had shown some decrease in size, and there seemed to be a tendency to heal at the edges. During the fourth and fifth months he received twelve treatments. The submaxillary glands had disappeared, but the growth had not changed. He was showing signs of sepsis (chills, fever and sweats), with increase in emaciation and prostration. He was strongly urged to have the remainder removed by operation. At the end of the sixth month he consented, and Dr. Ernest Laplace removed the growth, leaving the wound open to heal by granulation under the influence of the rays. The rays were applied the next day after the operation, and twelve treatments were given within a month. At the end of this time the wound was healed, and no signs of cancer were present. It has remained well since, which is seven months. (Fig. 4.)

This case was considered inoperable on account of the glandular involvement in both submaxillary regions. These enlarged glands disappeared under the influence of the x-ray.

I believe that had either the x-ray or the surgical measures been depended on alone the case would have been a failure, and I think that in all cases of epithelioma of the lip, surgery and the x-ray should be combined.

CASE 5.—Miss J. M., aged 25, a case of morphea. An uncle had some new growth on the neck; otherwise the family history is negative. Without any previous symptoms the patient discovered that an area of the skin about a half inch in diameter was a little darker in color and slightly raised above the surface of the surrounding skin at the side of the chest. There was no pain and no itching. Very little attention was paid to it for about two years, when it began to ulcerate. She then visited the skin dispensary of the University Hospital, where she was seen and photographed by Dr. M. B. Hartzell.

Later she came to the skin dispensary of the Medico-Chirurgical Hospital, where she was seen by Dr. E. S. Gans and referred for operation to Dr. W. L. Rodman. Dr. Rodman did not think an operation advisable, and referred her to the x-ray department for treatment.

Digitized by Google

Treatment.—*X*-ray treatment was begun Nov. 14, 1902. The disease had then existed four years, and the affected area was three and one-half inches in length and one and one-half inches in width. The center was an ulcer which showed no tendency to heal. This was an inch and a half in length and a half inch in width. Surrounding this ulcerated area was an area of scar-like tissue. She had a sensation of soreness at this point, but no other pain. There was a sero-purulent discharge present, and at times bleeding. She was treated three times a week, ten minutes at each exposure, with a vacuum corresponding to a 2 to 3-inch air gap, at a distance of six to

Fig. 5.

Fig. 6.

Fig. 5.—Case 5. Morphea. Before treatment.
Fig. 6.—Case 5. After eighteen months and eighty treatments.

twelve inches. After the fourth treatment there was less discharge. After twenty-five treatments and two months' time, the ulcer had healed, but an indurated scar one and one-half inches in length and a half inch in width remained in the center. After forty-five treatments and eight months' time the scar in the center was still hard. In other portions the skin seemed to be normal.

The patient left the city at this point and the treatment was interrupted for three and a half months. She returned Sept. 30, 1903. At this time the central scar was still present. In addition there was a small tubercle about one-eighth of an inch in diameter noticed lying posterior to and entirely outside of

Digitized by Google

the previously affected area. In the previous treatments the surrounding skin was protected, and this tubercle developed beneath this protection. Treatment was again instituted, but the patient was very irregular in attendance, and only eleven treatments were given in five months.

At the beginning of March, 1904, the tubercle had increased in size and a smaller one developed anteriorly. Dr. M. B. Hartzell very kindly excised the larger tubercle and examined it. He says: "The sections showed comparatively little departure from the normal. The chief changes consisted in a flattening out of the papillary layer of the corium, and a diminution in size and number of the blood vessels. There was absolutely no indication of epithelial overgrowth."

Following this, treatment was given more actively. Thirty-five treatments were given in two months. At the present time, one month after treatment, nothing remains but a scar one inch in length and a fourth of an inch in width. The wound of the excised tubercle healed promptly and the tubercle lying anteriorly to the old lesion disappeared.

This case was shown a number of times before the Dermatological Society of Philadelphia, where the diagnosis of morphea was made. It was suggested, too, that a carcinomatous change might be taking place. This was cleared up by Dr. Hartzell's examination. The patient had for a number of years refused to allow a portion to be excised.

Results.—The results obtained by treatment in this case have been fairly good, but far from brilliant. It has required eighteen months and eighty treatments to change a patch of morphea three inches in length and one and a half inches in width to a scar one inch in length and one-fourth inch in width. While the results have not been all that I had hoped for, they are better than were obtained by any other measures.

After the excellent work of Campbell,[3] Jutassy,[4] Pusey,[5] Stelwagon,[6] Engman,[7] and others, I shall not take up your time in reporting cases of acne, and will mention but one case on account of the heavy growth of down.

CASE 6.—Miss M. G. was referred to me by Dr. E. S. Gans. She had had acne twenty years. She was treated by all ordinary methods. After twenty-two treatments and three months' time the lesions had all disappeared, leaving the skin

3. Campbell: THE JOURNAL A. M. A., Aug. 9, 1902.
4. Jutassy: Fortschritte a. d. Geb. d. Roentgenstr., vol. iii, No. 3, p. 119.
5. Pusey: Journal of Cutaneous Diseases, New York, August, 1903.
6. Stelwagon: Journal of Cutaneous Diseases. New York August, 1903.
7. Enman: Interstate Medical Journal, April, 1904.

Digitized by Google

smooth and soft. The down which was present at the beginning of the treatment was less noticeable, but was still objectionable. The patient insisted on continuation of the treatment for the removal of the down. Thirty additional treatments were given in seven months. During this time it had been removed three times, and recurred twice. I shall treat her once a month for a few times to prevent recurrence.

Ordinarily, I would not advise the *x*-ray for the removal of down. I believe, however, that it can be done successfully, but will require repeated removals.

CONCLUSIONS REGARDING ACNE.

As to the treatment of acne with the *x*-ray, I think we can draw the following conclusions:

1. It meets the indications more satisfactorily than anything else.

2. Relapse is not frequent as in older methods, and is slight.

3. No burns of any serious degree are necessary during the treatment.

4. If the treatment is not forced to the extent of a burn, there is probably no danger of atrophy of the skin.

5. No reaction should be produced beyond a mild erythema, and this degree should be reached slowly.

6. It is not necessary to produce an erythema, but if the treatment is carried to this degree the results will be hastened.

7. The hair, eyes and eyebrows must be carefully protected.

8. A tube with a vacuum which will back up a two-and-one-half inch air gap, at a distance of ten to twelve inches, with a current of two to five amperes for five to ten minutes on the area treated, will probably give the best results.

9. In the average case, about three months' time and twenty to thirty treatments will be required to produce a cure.

DISCUSSION.

DR. M. B. HARTZELL, Philadelphia—I saw the case before it had been treated. While the case is reported as morphea there may be some doubt about the diagnosis. It may be that

Digitized by Google

this was one of the morphea-like flat epitheliomata which occasionally are observed. An examination of the small lesion left on the outside of the patch would seem to confirm the diagnosis of morphea; if this lesion is a part of the disease the diagnosis is fully established by microscopic examination. The case is extremely interesting both from the point of view of diagnosis and the excellent results following treatment by the *x*-ray.

Dr. J. C. Price, Scranton, Pa.—I think that the time of exposure, distance of tube from the patient and amount of current used is very important in our reports of cases, because of the various kinds of apparatus that are used for the production of *x*-ray. One man will give an exposure of ten minutes, one an exposure of five minutes, and without saying anything about the probable strength of current that goes through his tube or the vacuum of his tube. If you put a ten-ampere current through a primary of a coil and have a low vacuum tube you can burn a patient very quickly. If the men who are doing this work intelligently send out detailed reports, the many physicians who buy a static machine without having any idea of the physics of the apparatus, will be less apt to use the *x*-ray indiscrminately. If they have some data of that kind to go on, they may take enough interest to look the matter up and find out what they are doing. I think the *x*-ray has a wide field in the treatment of skin diseases, but it is surely going to get a black eye unless it is used intelligently. I see they are putting on the market an anometer that will measure the current from a static machine or secondary of a coil. If this is successful it will be of advantage in that we can then give exact doses. Anyone familiar with the physics of coils and static machines knows that no two coils will produce exactly the same secondary discharge with the same amount of current going through the primary, and that no static machine will produce the same amount of current from day to day, but varies widely with the varying conditions, so any instrument that will accurately measure the current going through the tubes will simplify matters greatly. We have some men who advise a static machine in preference to a coil for these treatments; it seems to me that when we come down to an exact dosage a coil is more reliable than a static machine. I wish to report a case of sarcoma treated by the *x*-ray: It was operated on by a surgeon in September, and referred to me for recurrence in January. The tumor had been sent to New York to be examined in a pathologic laboratory and it was reported to be a small round-celled sarcoma with some pigmentation. There was recurrence as large as a hickory nut. I intended to ray the growth a few times and then have it removed, but the patient's family objected to further surgery and I kept on with the ray. I can now report, fifteen months

Digitized by Google

after she was referred to me, that it has absolutely cleared up. Patient is 16 years old and is now in good health.

Dr. A. W. Brayton, Indianapolis—I have no x-ray installation myself; I am kept busy, however, repairing the injuries made by the x-ray machines in my vicinity. If I were to seek cheap electrical apparatus, I know of nothing I could buy cheaper of physicians than automobiles and x-ray machines. Seriously, however, I have had two cases within three months of diffuse symmetrical scleroderma; one is passing into the atrophic stage, another is in the condition of elastic edema. Neither of the women can dress themselves; one is 28, the other 35. I do not know whether it would be worth while to refer these two distressing cases of symmetrical scleroderma to an x-ray therapist for treatment. I know many of them, according to Crocker and Stelwagon, get well spontaneously. There is also a case of xeroderma pigmentosa 12 years of age that I have had under observation from the time of her birth. Her sister, 28 years of age, died from the disease. She developed a sarcomatous tumor of the hand, which grew to the size of her head. If this little girl, who is now in the stage of tumor formation, can be helped by the x-ray, I would like to know of it. I also have a case of Darier's disease under observation which is far more extensive and distressing than the one reported by Dr. Lieberthal. If in these rare diseases the x-ray is of known curative power, I would be pleased to know it. I have also a case of blastomycetic dermatitis under observation which has had 65 applications of the x-ray without apparent benefit. I have readily cured four other cases by the cautery and by erasure. I think the x-ray has a very limited sphere in dermatology.

Dr. C. W. Allen, New York City—In regard to the first cases I have had no personal experience, but I have had remarkably good results in the case of a young lady who has had lifelong ichthyosis, which is similar in character. In regard to xeroderma pigmentosa, I have had a patient under treatment for nearly three years. He has lost one eye; the cancer involving the globe, primarily the cornea, and his physician thought it better to enucleate the globe. Now the condition involves the opposite globe, and just for the present his family physician has put him in the hospital to try something new on the cancer of the opposite globe. The individual skin lesions will disappear. I have cured the man of at least fifteen cancers of the face, but others keep coming, although the ray in a measure keeps them down.

Dr. Brayton—They will drop off of themselves, or you can take them off with your fingers or a spoon, as large as a walnut. How do you know that the x-ray has anything to do with this clearing off that is common in xeroderma pigmentosa?

Digitized by Google

Dr. Allen—My personal impression is that the ray does something that the nature of the affection would not account for in the disappearance of the cancerous lesions. My assistant, Dr. Stern, is treating a subject of Darier's disease in his uptown dispensary, and he tells me he is getting very marked results and that his patient is gettting well.

Dr. L. Duncan Bulkley, New York City—I reported a case of Darier's disease affected very favorably by the *x*-ray. The patient had been in the hospital for six months and was bedridden for several months. The disease on the feet was completely cleared up, though it remained about the margin of the hair and on the wrists, which places were not thus treated.

Digitized by Google

THE CONSIDERATION OF LATE HEREDITARY SYPHILIS.

R. R. CAMPBELL, M.D.

Professor of Skin and Venereal Diseases, Chicago Policlinic; Associate Dermatologist, Staff of Cook County Hospital; Attending Dermatologist to Passavant Memorial Hospital.

CHICAGO.

On several occasions young girls from 5 to 18 years of age have been shown at meetings of the Chicago Dermatological Society, who presented undoubted lesions of tertiary syphilis, without a history of extragenital infection or previous eruptions of syphilis, and in whom none of the triad symptoms of hereditary syphilis was present. In the discussion of these cases it was apparent that a difference of opinion existed as to whether these were cases of extragenital infection or cases of long periods of latency in hereditary syphilis. The question which arose was: Can hereditary syphilis manifest itself for the first time some years after birth by the presence of such late lesions as occur in the acquired form, and with a total absence of triad symptoms?

That long periods of latency is one of the chief charasteristics of acquired syphilis there can be no doubt, as we all have seen cases in which from ten to twenty years have elapsed from the time the disease was acquired to the time the tertiary symptoms appeared.

If long periods of latency may occur in the acquired form of syphilis, why may they not occur in hereditary syphilis? Syphilis is the same whether acquired by the individual himself directly, or transmitted to him by his parents at the time of conception. Such being the case,

Digitized by Google

then we might expect to find long periods of latency in hereditary syphilis, and, if long periods of latency do not occur, then this form of the disease differs from ordinary or acquired syphilis.

While it often may be extremely difficult to establish the fact that children born of syphilitic parents and exhibiting late lesions may not have had other lesions early in life, still such cases are not infrequently met with. They must, however, be very carefully scrutinized, in order to avoid error. The ease with which one may be deceived in this matter is illustrated by the following cases: I have under observation at the present time several children who presented symptoms of hereditary or congenital syphilis at the time of birth, but who are entirely free from evidence of the disease at the present time. Were these children to be observed at the age of 20 years, and lesions of syphilis be found present, these children never having been informed by their parents or physician that they were born with the disease, would naturally give a negative history, and their cases readily be misconstrued or accepted as cases of acquired syphilis.

In establishing a diagnosis of hereditary syphilis, there are three points, known as the triad of syphilis, which have long been looked upon as of the greatest value. These are, namely, Hutchinson's teeth, interstitial keratitis, and a particular form of deafness. Let us consider these points in order:

TEETH.

Great stress has been laid on the diagnostic value of the Hutchinsonian teeth, but they in themselves are late manifestations of inherited taint, and can be accepted in no other sense. They are not present in the first or temporary teeth, but in the second or permanent teeth, which do not appear until the fifth or sixth year, and are not always indicative of syphilis when present, as J. C. White[1] has reported a case of a boy who presented the central incisors notched from side to side,

1. Archives of Dermatology, April, 1878.

Digitized by Google

with the lateral incisors wanting, in whom the suspicion of syphilis was absolutely excluded. The other teeth were normal. The deformity followed a sudden and severe attack of cervical adenopathy. Again, the characteristic teeth are present in only a minority of those who are the subjects of inherited syphilis, and it is unquestionably true that teeth of perfect development may not infrequently be seen in the mouths of those who have suffered severely from inherited taint.

INTERSTITIAL KERATITIS.

This is perhaps the most frequent of Hutchinson's symptoms, and occurs usually between the ages of 6 and 15 years; but, unlike the Hutchinson teeth, it may appear as early as the second or third year of life. Fournier claims this symptom may be due to malnutrition, as well as to inherited syphilis, and no differentiation between these two etiologic factors can be made in the effects on the cornea.

LABYRINTHIAN OR CENTRAL DEAFNESS.

This syphilitic deafness, depending, possibly, on lesions of the auditory nerves, is most frequently met with in children about the age of puberty, or in adults, and manifests its presence by the following symptoms: It is, as a rule, unilateral in the beginning; but after a shorter or longer period, varying from a few weeks to some months, the other ear becomes affected, deafness appears suddenly, and advances rapidly; it is not accompanied by pain, or any discharge, although occasionally an otitis media purulenta may be present. The patient complains of noises, dizziness, and sometimes even attacks of vertigo occur. The deafness is usually progressive, and after some weeks may become absolute. It is not improved by anti-syphilitic treatment.

While the above-mentioned points are of great diagnostic value in hereditary syphilis, there are others which, although perhaps not so common, are nevertheless of much significance when present.

Digitized by Google

Among these may be mentioned acute ulcerative destruction of the palate in young persons. This in itself is almost conclusive proof of an inherited taint.

Edmond Fournier[2] and some other French writers lay great stress on the findings in the fundus of the eye as an aid in the diagnosis of hereditary syphilis. In one case he describes atrophic chorio-retinal plaques in both eyes.

In another case the remains of an old papillitis was seen. Vascular changes, and alterations of pigment, which the oculist, Antonelli, stated could only be the stigmata of hereditary syphilis, were observed in one eye, and in the other there was a rudimentary optic neuritis, a diffuse retinitis of several months' standing, manifesting itself by several foci of exudations in the central region, by a suffusion which was quite extensive, and by multiple separations of the retina in the temporal and upper sections of the eye fundus.

Late hereditary syphilis may affect the skin, appearing as gummata, singly or in groups, of solid nodules, which are dark red in color, and are most frequently seen on the face or forelegs. These nodules may later break down and ulcerate. On the face they most frequently attack the nose, and when on the legs the anterior surface. The ulcers are sharply defined and clearly cut, with abrupt, uneven edges, and present the usual characteristic appearances of the ulcerating gummata of acquired syphilis. Unlike early acquired syphilis, we never have any scaly or small papular eruptions.

Notwithstanding all of these points, it must be admitted that there are patients in whom, in spite of the modern development of diagnosis, the recognition of inherited taint is still a matter of great difficulty, if not an impossibility. We must, however, be prepared to encounter now and then manifestations of inherited syphilis in those who do not show a single corroborative feature. Hyde[3] remarks that not every child with Hutch-

2. Annales de Derm. et Syph., 1904, p. 152.
3. Med. News, Dec. 14, 1897, p. 727.

Digitized by Google

insonian teeth, with cranial bosses, with natiform skulls, or suffering from a rebellious affection, is the victim of inherited syphilis, and that even the painstaking labors of A. Parrot have not sufficed to obliterate the distinction between syphilis and rickets.

Cases of latent hereditary syphilis are not very numerous in the literature:

Jordan[4] reports the following two cases:

CASE 1.—Patient, army officer, 22 years old. Applied April 23, 1902, for treatment for disease of the knee joint. He denied all knowledge of venereal disease. About the end of April, 1901, patient first complained of pain in both knee joints on climbing stairs. This without apparent cause. In June pain disappeared from the right knee joint, while the pain in the left became more intense. Early in July the army surgeon noticed a swelling of the knee joint and induced the officer to ask for a furlough.

Treatment.—No improvement was noted after treatment with baths and compressed applications, consequently the patient entered a surgical clinic in September, 1901. Effusion in the left knee joint was treated with iodin, compression and hot air. The swelling decreased in amount, but did not entirely disappear. Palpation of the joint was painful and an incision was made above the patella, under the supposition that the case was one of tuberculosis. Drainage of the joint with iodoform gauze. Examination of the urine was negative as to gonococci. The wound healed and the patient was discharged in November, wearing a plaster-of-paris dressing or cast. The end of March following the swelling in the joint, which had never entirely ceased, became increased.

Examination.—April 1, 1902, when first seen by Jordan, the left knee joint was markedly swollen and tender, and there was slight swelling in the right knee. Both joints were freely movable. A thorough examination of the young man did not reveal any signs of a past tuberculosis or lues.

Treatment instituted consisted of complete rest in bed, baths and compression bandages.

Diagnosis.—A week later, notwithstanding this treatment, the swelling increased in the right knee joint, and closer observation gave the impression that the cause of this swelling was syphilis. Jordan made his diagnosis by exclusion. Hydrops could not be accounted for by its usual etiologic factor. Trauma was excluded. Acute articular rheumatism was absent. No signs of gonorrhea were present and also no tuberculosis. The negative results of the incision, combined with all the preceding features, brought him to the conclusion that this was a case

4. Münch. med. Woch., 1903. 50, p. 1324.

Digitized by Google

of lues. The slow bilateral effusion in the knees, the slight pain, the insignificant functional disturbance, the changing of the symptoms and the failure of all treatment were all facts in favor of syphilis. As acquired syphilis was excluded with certainty, it could only be a case of late hereditary syphilis. The favorable result following specific treatment justified this diagnosis.

Family History.—The family history of the patient disclosed the following facts: The patient's father was a physician and became infected with syphilis on the hand while attending an accouchement in 1872. He married in 1877. His wife, who was still alive, stated that on several occasions he had had eruptions on the face, and took iodid of potassium.

Maternal history: First pregnancy in 1878. Premature birth. Child died a few hours after birth. Second pregnancy, 1879. Miscarried at five months. Child dead. Third pregnancy, 1880. A normal, healthy boy. (Jordan's patient.) No affections. Fourth pregnancy, 1883. Aborted at two months. Patient's mother, in 1886, had a stroke of apoplexy, but completely recovered. In 1887 she had an ulcer of the soft palate, which rapidly healed under antisyphilitic treatment. The patient's father spent nine months in an asylum in 1882 for some brain trouble. Marked improvement. In 1883 committed suicide.

The diagnosis in the patient's case was latent hereditary syphilis. The treatment was sodium and potassium iodid, with the result of complete recovery. In November the patient resumed his duties as an army officer.

This case is considered a typical one of latent hereditary syphilis, with a single localization.

The second case was one of bilateral exudative gonitis, combined with keratitis parenchymatosa, in which complete recovery followed antisyphilitic treatment. The history of this case is as follows:

CASE 2.—Patient, a boy, 5 years of age, came to the clinic in July, 1895, suffering from a bilateral inflammation of the knee joints; the knees were swollen, and the ends of the bones considerably thickened. There was also a keratitis parenchymatosa. Dec. 15, 1895, after a course of treatment, the patient was discharged. In January, 1901, trouble appeared in the eyes. In the spring of 1903 the patient, who was now 12 years old, was again examined and found healthy. On the left cornea some cloudiness, due to scar, was found. This lessened the field of vision considerably. The joints were found to be normal. With the exception of the scar on the cornea, no evidence of syphilis could be detected.

Family History.—Father had an ulcer on the penis in 1881. Married in 1886, or five years later, and infected his wife in

Digitized by Google

about a month. Symptoms in mother were roseola, condyloma of labia, and mucous patches in throat. By Oct. 28, 1886, all symptoms disappeared under treatment. In 1887 gave birth to child, which died two days after birth. In 1888 another miscarriage at six months; fetus dead. In 1889 again miscarried at six months; fetus dead. In 1890, the fifth labor was normal, and a boy, the herein-mentioned patient, was born. The next, or sixth, labor was normal, and the child, which at this time was 9 years old, was anemic and suffered from headaches. The seventh pregnancy: Premature birth, stillborn child. In 1895 eighth pregnancy, normal delivery at term; child at this time 7 years old and healthy. The ninth pregnancy was again premature; fetus dead. The last pregnancy occurred in 1898; labor normal and child healthy.

This case substantiates Fournier's observation that in a syphilitic marriage the birth of a healthy child does not warrant that the children which may follow will be healthy; but, rather, that a syphilitic child follows a healthy one. In this case the period of latency was five years.

Hünicken[5] (Brunic) reports a case of syphilis hereditaria tarda:

History.—The mother of the patient, who had always been healthy, was infected by her husband in the second month of her pregnancy. The corroborative symptoms of the mother's syphilitic infection were condyloma of the great labia and anus; roseola; angina; and periostitic headache.

Treatment.—The symptoms all disappeared after six months of antisyphilitic treatment (inunctions). It was expected the mother would miscarry. On the contrary, however, labor occurred at term, and a healthy boy was born. He remained healthy, with no evidence of syphilis; learned to walk when 2 years old; was vaccinated at age of 3 years. At 9 years old he complained of pain in the knee on walking. This was followed by swelling of both knee joints. Diagnosed simple synovitis. Was treated with ice, compression and rest for three weeks, with no improvement. At this time both tibiæ were discovered to be highly sensitive to the touch. The diagnosis was changed to latent hereditary syphilis, and the trouble, after four weeks' treatment by inunctions and potassium iodid, entirely disappeared.

Barthelemy[6] reports the following case:

History.—A man contracted syphilis and was treated by Ricord for eighteen months, at the end of which time he mar-

5. Deutsche med. Woch., 1896, vol. xxii, p. 46.
6. Annales de Derm. et Syph., 1899, 3d ser., vol. x, p. 262.

Digitized by Google

ried. For twenty-five years following he had no manifestations of syphilis. His wife bore him five children, all at term, except the last, when labor occurred at eight months. The first child was treated by Millard for submaxillary ulcerative lesions, which were diagnosed scrofulo-tubercular lesions. When Barthelemy saw this patient he took these lesions to be local bacillary lesions. She had become a woman, 25 years of age, and had given birth to a healthy child one year previously. The second child, a son, when 23 years old, was treated for two years for acquired syphilis.

Her third child, at this time a girl of 20 years, is the subject of this case. She has never had any stigma of syphilis, either on her body, teeth, eyes or ears. A month previously a bulla, the size of a fifty-cent piece, was noticed. This was thought to have been caused by a burn or stinging of an insect. Burning and itching were severe, and became more intense and deeper from day to day, until a large granulous wound was present, which showed all the characteristics of a tertiary ulcero-circinated syphilid, and a nummular gumma of the skin, which diagnosis Fournier confirmed, without reserve. The gumma was located on the knee, and appeared twenty years after birth.

E. Gaucher, Lacaperre and H. Bernard[7] report a case of latent hereditary syphilis with dental dystrophia:

History.—A female, 19 years old, was brought to the Hospital Saint Antoine, March 14, 1900, in a state of semi-coma. Examination revealed a right hemiplegia, with aphasia. Patient had given birth to a child a month previously.

The diagnosis made at the time was puerperal infection and metritis; bilateral phlebitis of the thighs; pulmonary embolism, which accounted for the pain in the thorax. To explain the hemiplegia and aphasia, it was supposed to have been caused by a fibrinous coagulation in the heart, which is slightly dilated. Patient positively denies any venereal infection, and of her father's history nothing could be learned. The patient's child died a few days after birth, showing no trace whatsoever of syphilis.

Treatment.—The appearance of the teeth attracted attention and suggested the possibility of syphilis, which suggestion was followed out, and the patient placed on daily inunctions, and four grams of kali iodid internally. Marked improvement followed immediately, and the patient was discharged from the hospital May 24, 1900.

One year later (April 21, 1901), patient returned to the hospital for consultation. There were present tertiary cutaneous gummata on the legs. The diagnosis was latent hereditary syphilis. Dental dystrophia revealed the presence of hereditary

7. Annales de Derm. et Syph., 1901, 4th ser., vol. II, pp. 437-46.

Digitized by Google

syphilis at 20 years of age. No previous accident would suggest the existence of syphilis, but a few months later the appearance of gummata on the legs and the effects of treatment confirmed the diagnosis.

Lannelongue[8] mentions a case of a young man, 34 years old, who had a typical gummatous ulcer on one of his legs, the nature of which had not been suspected until the patient consulted Lannelogue, who diagnosed latent syphilis of hereditary origin. He mentions also three more cases of latent hereditary syphilis, in young girls, who were about to be married, and who never knew that they were thus afflicted.

CASE 1.—Young girl, from a syphilitic father. Suffered with a gumma of the leg.

CASE 2.—Young girl, 23 years old, for past four years affected with a phagedenic serpiginous ulcer of the leg.

CASE 3.—Young girl, 20 years old, affected with gumma of the soft palate.

H. G. Anthony[9] reports a case:

History.—Twenty years ago a man acquired syphilis. He married while the roseola was present, and immediately infected his wife. A child was born three years after the marriage. Eleven years ago, when the child was 6 years old, he examined the family. The father and mother showed unmistakable evidence of the disease, but the child was free from symptoms of hereditary syphilis. Since this examination the mother, knowing that she herself had had syphilis, has always been very solicitous regarding the welfare of her daughter, and watched for skin eruptions or other possible symptoms of the disease, and up to this time she had never observed anything of a suspicious nature.

In October, 1903, she brought her daughter to Anthony again. She was 17 years old, and was found to have a circinate, ulcerating, tubercular syphilid, situated on the anterior surface of the chest. There was nothing in the history of the case which would in any way suggest a possible extragenital infection, and genital infection could be excluded as thoroughly as it ever can be.

Born of a syphilitic mother, who was known to be syphilitic at the time of conception, there is every reason to suppose that this is a case of hereditary syphilis,

8. Bulletin de l'Acad. de Méd., Paris, 1903, 3d ser., vol. xlix, p. 532.
9. Illinois Medical Journal, November, 1903, p. 368.

Digitized by Google

in which no appreciable evidence of the disease was present up to the seventeenth year of life.

L. Duncan Bulkley[10] reports the following interesting case:

Examination.—Mrs. H., aged 24; fairly well developed. When first seen there were the active elements of a tubercular eruption on the forehead, right ear, arms, knee and back. On the left arm there were two patches, of a dull-red color, about an inch and a half in diameter, composed of curved lines, or rows of tubercles, which have advanced, leaving scar tissue behind, which later surrounded the elbow. The right arm was similarly affected. On the shoulders was an eruption, dark red, or copper-colored, with some crusting in places, composed of irregular patches of tubercles, and cicatricial tissue by the side of the more recent disease. The eruption extended down the back six or eight inches. Near the left knee there was a patch of the same form of lesion, and a few scattered tubercles on the upper lip. All portions of the eruption presented the same features, composed of tubercles of a dark-red or coppery color, elevated from one to two lines above the surface, either touching each other or separated by an erythematous redness. The cicatrices are all alike; supple, mostly white. The more recent ones stained and slightly depressed. In the middle of the forehead there was a depression in the bone, pyramidal in shape, the apex resting at the bridge of the nose and being about two inches wide at the base.

History.—Of the origin of this she could give no exact account. It had taken place slowly, beginning, she thought, at about 16 years of age. There had never been any externally discharging ulceration there. When 5 years old she had a deep sore near the ankle, which lasted four or five months, and which left a scar. Two years afterward, when she was 7 years of age, the present eruption first made its appearance, and has continued since, a period of fourteen years. She had been under medical treatment off and on, but never with any great success.

Family History.—Her family history was not clear. She thought her father was healthy. A sister, 30 years of age, she said, had the same eruption; and her sister's children were also affected. She herself had been married seven years, and had had four children, two of which are dead.

This patient remained for a time under antisyphilitic treatment, and improved nicely, but disappeared before sufficient time had elapsed to accomplish a cure, so the ultimate results of treatment can not be stated.

---

10. Archives of Dermatology, January, 1878, p. 70.

Digitized by Google

The two cases reported by Willis S. Anderson[11] contain several points of interest. The histories are as follows:

CASE 1.—M. B., a girl, aged 16.

Family History.—Mother, apparently healthy, with no history of syphilis. Father not seen. Mother has had nine pregnancies. The first and second children were boys, who are alive and healthy; the third and fourth were premature, at eight months; bodies decomposed. The fifth was the present patient. The sixth, seventh and eighth are alive and healthy. The ninth died of pneumonia when nine months old.

Personal History.—The patient's general health has been fair. Eighteen months previously she had pain in her legs for a number of weeks. Has had enlarged glands in the neck for years. About two months before coming to the clinic, she noticed a pea-like swelling at the mucocutaneous junction on the left side of the septal cartilage of the nose which she thought was a cold sore. This increased in size, spreading to the upper lip and into the nose, especially attacking the septum. There were no pain or constitutional symptoms.

Examination.—The examination of the nose showed that there was an extensive ulceration of the whole cartilaginous septum, including the columna, and of the uper lip. The ulcerated area was covered with thick crusts, and there was a foul, irritating discharge from the nose. The whole of the septal cartilage was nearly ready to slough out.

Treatment.—The next time the patient was seen, the entire cartilaginous septum, including the columna, was removed. The parts were kept clean, and potassium iodid given internally. The condition improved and the ulceration ceased.

CASE 2.—M. O., a girl, aged 14.

Family History.—No history of parental syphilis could be obtained. Mother always healthy; had had four children. Three alive and well. One died, aged seven months, of pneumonia. No miscarriages. Father is in excellent health, and denies ever having had syphilis.

Personal History.—Patient, when one year old, fell and struck on her nose, but no permanent injury resulted. Her general health has always been good and nasal breathing free. Six months before coming under observation she commenced to have obstruction to breathing through the right side of her nose. No cause could be discovered, unless possibly it was the result of boxing with her brother. The obstruction gradually increased, but was unaccompanied by pain or constitutional symptoms. She was brought for treatment, because of the obstruction, commencing deformity of the nose and enlargement

11. New York Med. Jour., July 26, 1902.

Digitized by Google

of the lymphatic glands just below the angle of the jaw on the right side.

Examination.—Examination revealed a red, globular tumor, of about the size of a pea, attached to the right side of the septal cartilage, well forward. Just behind the anterior growth could be seen another globular tumor filling the nasal passage. There was bulging of the nose exteriorly, corresponding to the right ethmoid cells. As the nasopharynx was filled with the growth, it was evident that the tumor filled the whole nasal passage. There was marked swelling of the glands of the right side of the neck. The tumor in the nose was fairly firm in consistence; not painful, and did not bleed readily when touched. The glandular mass in the neck was not accompanied by any pain or tenderness. No ulceration was observed in the nose, and there was only a moderate acrid discharge. The growth in the nasopharynx had an angry appearance, and was covered with thick, tenacious mucus. The general health of the patient was little impaired. Her symptoms could all be accounted for by the nasal obstruction and the pressure of the growth.

Treatment.—The diagnosis of late hereditary syphilis was made by exclusion, and the patient placed on kali iodid internally and mercurial inunctions, with the result that the growth gradually melted away and the enlarged glands disappeared.

At the present time I have under my care the following case:

History.—A girl, 16 years old, is one of seven children, all healthy and robust. Patient's menstruation first appeared when she was a little over 15 years of age. About this time patient suffered intensely from pains in the legs and nocturnal headaches. On the right foreleg were noticed elevated red spots, as the patient describes them, varying in size from that of a split pea to almost, if not quite, the size of a twenty-five-cent piece. Within a month the left foreleg presented a similar condition to that on the right leg. When the patient first came under my observation, she presented typical ulcerating gummata on both legs, without any other evidence of hereditary taint, and an absolutely negative history as to any skin eruption or sickness of any character in the earlier years of her life.

Family History.—The mother of the patient is a subject of ichthyosis,, and states that she had had two miscarriages, occurring without apparent cause; the first at between five and six months, and the second at between six and seven months. On the right hip of the mother examination reveals a scar which resembles that following a syphilitic ulceration, although she denies all syphilitic history. The patient's father refused to be examined or interviewed.

Digitized by Google

Treatment.—Under antisyphilitic treatment our patient made a prompt recovery.

Fournier[12] says that latent hereditary syphilis may manifest itself at any age, from young adult up to old age (less frequently in old age), at 51, even at 60 years, and older.

We have grown away from the teachings of Kaposi, Barenspring, Lang, and others, who state that cases of latent hereditary syphilis are not authentic. They say that if this disease be congenital or hereditary, there must have been infantile manifestations. We accept as facts the teachings of Fournier, Neuman, Sigmund, Hebra, and others, that these cases are authentic, and do occur.

414 Marquette Building.

DISCUSSION.

Dr. A. W. Brayton, Indianapolis—Those of us who are getting along into the second half century and have been practicing and teaching general medicine for twenty-five years can authenticate the statements made by Dr. Campbell in regard to the late manifestations of hereditary syphilis. I have never found a case of locomotor ataxia, and but few of general paresis, that I did not find a history of syphilis, and just as a parasyphilis may develop under varied conditions of acquired syphilis so we may look for late lesions in hereditary syphilis.

Dr. L. Duncan Bulkley, New York City—I have seen hereditary syphilis up to 20 or 30 years of age, and many cases even where there has been practically no clear antecedent syphilitic history. I do not, however, believe that a case of late hereditary syphilis never shows anything before. I have never convinced myself that there can be an infection and nothing take place until thirty years afterward, but I think that in many cases the earlier manifestations have simply been overlooked. I do not believe that anyone can look at a case of hereditary syphilis superficially and make a correct diagnosis. It is only by study, and by a careful consideration of a case, and exclusion of other conditions, that we can arrive at a diagnosis. Many of these cases that are often regarded as subjects of hereditary syphilis, I believe to be cases of constitutional syphilis, acquired during or after birth, which occurs much oftener than we imagine. Only a short time ago a child of two years was brought to my office with a large hard chancre on the prepuce. The father and mother were

12. Bulletin de l'Acad. de Méd., Paris, 1903, 3d ser., vol. xlix, p. 532.

Digitized by Google

certainly pure and free from any taint of syphilis, yet at two years of age the child had a chancre of the penis, not from circumcision. It was finally traced to the nurse, who had turned out to be a very loose character, and had just been discharged because she was found to be pregnant. She had given it to the child through lesions of the mouth. In the case of that child, if it had not been seen and diagnosed by some one who knew, but had recovered and had late lesions of syphilis, it could be readily supposed to be a case of hereditary syphilis, while it was really a case of early infection. Do not forget that those cases where you can not get a history may have had an infection early in life.

Dr. C. W. Allen, New York City—Ranging myself with the older practitioners I would say that I have been teaching syphilis for a number of years, and I have had it happen many, many times, that in analyzing a case I have said to the students: here is a case where we can make out nothing but late hereditary syphilis without any history of preceding infection. I realize with Dr. Bulkley, that acquired syphilis may often escape observation. I have seen acquired syphilis in the very young where the parents have been healthy. I am convinced that without a preceding history, without knowledge of any syphilitic lesions having manifested themselves, an individual may arrive at the age of twenty or more years, up to thirty, and possibly far beyond that, and then show unmistakable lesions of syphilis.

Dr. Mortimer A. Moses, New York City—Concerning the sign of hereditary syphilis described first, I think, by Silex of Berlin—the furrows at the angle of the mouth—is this sign of absolute corroborative value or is it seen in any other condition than hereditary syphilis?

Dr. H. C. Baum, Syracuse, N. Y.—I concur absolutely in all the findings of the paper. I had one case, a young woman 23 years of age, who had never employed a physician, but was delivered by a midwife. She came to the late Dr. U. H. Brown of Syracuse on account of a destructive gumma of the nose. He made a diagnosis of gumma, and his plan of treatment was indignantly rejected by the patient and by her husband, who had always been well, and by her mother, who accompanied her, and who was very much offended at any such suggestion; she herself having always been well, and never having had any other pregnancy than that of the patient. I was brought in and confirmed the physician's diagnosis, and yet treatment was refused. A year later she reappeared, with tremendous destruction, and applied for treatment. She responded nicely to treatment, and looking up the case afterward it was found that the father had died in a soldiers' home at Bath. I wrote there and was told the cause of death was syphilis.

Digitized by Google

Dr. R. R. Campbell—With respect to acquired infantile syphilis, it is gratifying to note that this form of the disease is far less common than is usually believed. Fournier has a record of but 45 patients of this class coming under his observation, though he adds that he believes, as many more have been seen by him, regarding which no notes were taken. In so far as I have been able to learn, the highest number of this class of cases reported by authorities other than Fournier, has been twenty-five. Replying to Dr. Moses, in my opinion the red furrows at the angle of the mouth can not be accepted as a symptom of any particular value in hereditary syphilis, for the reason that I have found it too often in the acquired form of the disease to grant it particular importance as an indication of the hereditary origin of the disease.

Digitized by Google

XANTHOMA.

JOHN V. SHOEMAKER, M.D., LL.D.

Professor of Skin and Venereal Diseases in the Medico-Chirurgical Hospital.

PHILADELPHIA.

History.—A lad, 18 years of age, afflicted with peculiar, characteristic and unusual lesions on the hands, knees, posterior aspect of the thighs below the buttocks and on the eyelids, was brought by his father to the dermatologic clinic of the Medico-Chirurgical Hospital, was shown to the class on several occasions and made the subject of a clinical lecture.

Physical Examination.—Small in stature, general lack of development. Greatest weight, 79; present weight, 67. Thin, with almost no subcutaneous fat. General appearance that of a boy of twelve. Face marked with lines, giving the appearance of old age. Skin pale, showing a general anemic condition; complexion yellowish, subicteroid. Tongue flabby and pallid.

Chest narrow, scapulæ prominent; marked depression above and below clavicle.

Circulation poor; pulse weak. Heart's action increased, apex beat displaced, diffuse; functional cardiac murmur.

Liver enlarged, extending from fifth interspace to an inch below umbilicus.

Spleen enlarged; could be easily palpated.

Urine: An analysis of the urine gave the following results: Sp. gr. 1014; acid reaction; no albumin; no sugar; no sediment; hyaline cylindroids; blood cells, uric acid and urates in abundance.

Blood.—An examination of the blood by Dr. L. Napoleon Boston revealed: Red corpuscles, 3,990,000; white corpuscles, 20,000; hemoglobin, 60 to 67 per cent. Dr. Boston also contributes the following notes concerning the blood: The red cells were pale. There was marked variation in the size of the red cells, many of them being greatly oversize, while others were scarcely one-half the normal diameter. The viscosity of the blood was diminished. The red cells stained feebly, as a rule; cells nearly colorless were often seen. The central pale spot in

Digitized by Google

the red cells was much enlarged, and at times this pallor extended to near the margin of the cell. The hemoglobin had been extracted from areas in the protoplasm, and these pale areas overlying such degeneration resembled somewhat the effect produced by the malarial parasite. No pigment was seen in the red cells. The differential leucocyte count was as follows:

	Per cent.
Polymorphonuclear cells	66.0
Large lymphocytes	4.5
Small lymphocytes	15.4
Eosinophiles	6.0
Myelocytes	3.0
Large mononuclear	4.5
Transitional cells	0.6
	100.0

Description of Lesions.—The palmar and dorsal surfaces of both hands were covered with small growths, which had been in existence for about six months. They first came on the hands. The affected regions did not ache spontaneously, but were painful on pressure. The boy could not grasp objects firmly by reason of the tenderness of the palms. The earliest lesions occurred on the palms, especially in the flexures of the metacarpophalangeal and phalangeal joints. They were symmetrically arranged, and a description of one hand will do for both. An artist, with deliberate intent and skill, could not more accurately copy the picture from palm to palm. The palmar aspect of the thumbs and fingers were studded with discrete tubercles, most prominent in the flexures of the joints. At the base of the thumbs were numerous tubercles which presented a linear arrangement. Lesions were similarly distributed, corresponding to the principal lines of the palms. They were also perceptible between the fingers. The disease was likewise conspicuous over the knuckles, although the lesions in these situations were less numerous and distinct than on the palms. An equal symmetry was observed in the location of the growths on the backs of the hands. Lesions were observed between the fingers, and in the flexures of the elbows they were confluent. The distribution was symmetrical on both arms. Large lesions were scattered, though more sparsely, over the back. Some of the largest tubercles, about the size of a pea, were situated below the gluteal fold. Lesions existed behind each ear and on the scalp. The upper and lower lids of both eyes were covered with numerous small lesions. They were present on the dorsal and plantar surfaces of both feet and between the toes. Walking was impeded and kneeling was painful.

In various situations the lesions were both nodular, or discrete, and confluent. Small nodules were seen on the penis. A patch existed on the mucous membrane of the mouth, corresponding to the attachment of the upper lip to the alveolar

Digitized by Google

process. There was a spot of the same kind on the lower lip and others at the angles of the mouth, and one on the uvula. Several were situated within the nostril. Those located on the mucous membrane were rather more conspicuous than those on the skin, owing to the contrast between their yellow color and the red of the mucous membrane.

Many of the lesions were slightly elevated; others were

Fig. 1.—Palm of a typical case of xanthoma.

plane with the surface. They were of a yellowish color and resembled fragments of chamois leather embedded in or attached to the skin. As the father expressed it, they are particularly numerous where the skin is "slack," or where it is habitually brought in contact with objects.

Diagnosis.—Although this case represented a rare affection, yet its features were so distinctive that there could be little

Digitized by Google

difficulty in forming a diagnosis. The yellowish color might possibly be suggestive of pus, but the contents of the tubercles were neither fluid nor fluctuating; the lesions were rather soft, but nevertheless of firm consistency. There was no resemblance to acne or any other inflammatory disease of the skin. There was more analogy to milium, which is sometimes of a yellow color, appears principally on the upper eyelid and other parts of the face, and may remain stationary for years. Milium, however, contains sebaceous matter, which may be forced out by pressure after the surface has been pricked. This was not possible with the tubercles of the case now reported.

CLASSIFICATION.

The permanence of the lesions indicates that the disease should be classified among the new growths or tumors of the skin. The structure and the distinctive hue of the lesions are evidence that it could be no other than the affection which is named for its color—xanthoma, from ξανθός, yellow. Ordinarily, there is little scope for error, although multiple dermoid cysts have been mistaken for xanthoma, from which they could only be differentiated by microscopic examination. Urticaria pigmentosa, which occurs during infancy or early childhood, has sometimes been confused with xanthoma, a fact which is suggested by the very name which some writers have bestowed on that rare variety of nettlerash, viz., xanthelasmoidea. The possibility of error is all the more marked when we reflect that pigmented wheals may persist as permanent new formations of the skin and subcutaneous connective tissue, and that their color may be yellow. Wheals, however, are of firmer consistence than the tubercles of xanthoma. Itching is a much more prominent feature in urticaria than in xanthoma.

SYMPTOMS.

Xanthoma is divided into two varieties, according as the lesions are plane or raised—xanthoma planum and xanthoma tuberosum. The spots of xanthoma planum are smooth, sometimes slightly elevated and of a yellowish hue, which has been aptly compared to that of chamois leather. On account of the buff or yellowish

Digitized by Google

color, the disease has also been known as xanthelasma. The abnormal pigmentation has suggested another title for the malady, vitiligoidea. A multiplicity of names or titles for the same disease is undesirable, as it is liable to lead to confusion.

The lesions of xanthoma may be round or elongated. In the case now under consideration, many exhibited a linear arrangement. They may be as small as a pin's

Fig. 2.—Lesions of xanthoma.

head or as large as a pea, and, indeed, in some instances have acquired much larger dimensions. Duhot has recorded a case in which some of the tumors were as large as a walnut. W. Moser encountered a case of a boy in whom multiple mushroom-like growths existed from the size of a pea to that of a hen's egg or larger; they were not tender or painful.

Digitized by Google

Xanthomatous skin does not seem to be thickened when pinched up between the fingers. After attaining a certain size the lesions generally cease to grow. The eyelid is a favorite location. Cases in which the disease is limited to the eyelid are much more common than those in which the lesions are more widely distributed, and which have been called xanthoma multiplex. In young persons most of these cases are congenital; in adults they are associated with jaundice or diabetes. The lesions have been seen on the cornea, in the mouth, esophagus, trachea, spleen, lining membrane of the bile ducts, liver, heart, aorta, and in the abdominal muscles. Tendons and serous membranes have also been implicated. Adjacent spots may coalesce. Xanthoma of the cornea is extremely rare. Gaucher and Herscher described a case[1] in which the cornea was involved, and stated that they had only been able to find one other case previously reported. The patient was three and one-half years of age, and was probably syphilitic. There was double interstitial keratitis. The keratitis was prior to the ocular xanthoma, the nutrition of the cornea had been reduced.

Fig. 3.—Typical lesions of xanthoma.

1. Journal des Maladies Cutanées et Syphilitiques, 1900, p. 48.

Digitized by Google

and it had become a spot of least resistance. On the right cornea was a yellowish deposit of irregular shape and plane edges. There were characteristic tubercles of xanthoma on the cheeks. The nodules of xanthoma tuberosum are, as a rule, about the size and color of those of the plane variety, and round in shape, though they have been seen as large as a small apple. The large growths are due to an aggregation of tubercles, and are more irregular in form. In both varieties of xanthoma the color may vary from a light to a dark shade of yellow.

Xanthoma is more frequent in women than in men. The most usual site of commencement is on the inner canthus of the eyelid, and more particularly of the left eyelid. It begins as a macule. The coalescence of several patches sometimes forms a semicircle around one or both eyes. Subsequently other parts may be attacked. The disease is generally tardy in its progress. Large growths overhanging the eye have been known to interfere with vision. Korach and Hertzka have reported cases in which the evolution occurred within a few weeks, involving the greater part of the body, accompanied by icterus and pruritus. Dr. George T. Jackson of New York observed a case in a boy of 5 which began when the patient was 3 months of age, and attacked all parts of the body except the hands, feet and scalp. Prof. McCall Anderson witnessed an apparently congenital case in a child 3 years of age. Xanthoma, especially of the tuberous variety, is rare in children. Richter had as a patient a 9-month-old girl afflicted with generalized xanthoma, marked especially by tumors. The mother thought that the disease had followed the bites of insects when the babe was 3 months of age.[2] Most cases occurring in early life are hereditary or congenital.

Some cases of xanthoma have been described which seemed to be of hereditary origin. Török knew of a family in which it had affected three generations. Hil-

2. Journal des Maladies Cutanées et Syphilitiques. 1903, p. 531.

Digitized by Google

ton Fagge mentions a mother and daughter who had xanthoma, and in whose family it had occurred for four generations. Hutchinson reports a case of xanthoma in two brothers and a paternal grandmother. Crocker had a case in a stout, country lad of 18, in which the lesions were symmetrically situated on the elbows and knees; an elder brother had the same disease on the elbows. Xanthoma is rather commonly associated with disease of the liver and jaundice. It has been known to develop during the course of diabetes or gout. Jonathan Hutchinson has described an interesting case. The patient had inherited gout, of which he had had several attacks, and of which physical evidence existed in enlarged bursæ and fusiform swellings in connection with numerous tendons. In consequence of a severe fright, jaundice supervened, after which xanthoma appeared on the eyelids. The patches were symmetrically arranged. Subsequently small streaks of the same disease appeared over the right olecranon process. The patient's father and maternal grandmother had had xanthoma of the eyelids. Under the title of xanthomatosis the case has been described of a woman, 35 years of age, who had slight mitral insufficiency, stationary for several years, rheumatism, hepatic colic with or without jaundice, but no gallstones. This patient had xanthoma planum of the eyelids and a small fibro-fatty tumor of the abdominal wall.

In the opinion of Besnier, xanthoma of diabetic origin manifests a tendency to spare the eyelids and locate itself in the mouth. This writer furthermore states that buccal xanthoma progresses rapidly, but may spontaneously disappear. Diabetic xanthoma runs a more rapid course than when the disease is due to other causes. A few cases are on record in which xanthoma preceded the glycosuria. Another case is mentioned in which sugar had entirely disappeared from the urine fifteen months before an eruption of xanthoma occurred. Sequiera had a case of diabetic type without glycosuria. The patient

Digitized by Google

was a man, 45 years of age, in whom the disease had existed for six months without any impairment of the general health. He had never had jaundice, but there was slight enlargement of the liver. According to Malcolm Morris, jaundice never accompanies the xanthoma of diabetics. Up to the year 1900 but 30 cases of diabetic xanthoma had been reported. Several have been published since that date. An interesting case was studied by Sherwell and Johnston.[3] The patient was a diabetic woman, 40 years of age, who had xanthoma on the arms, elbows, knees and buttocks. In fact, no part of the body was totally exempt. It was present also on the palms, soles and scalp. The eyelids, an ordinary site, were spared. The lesions were painful when touched. It was difficult to handle objects, walk or lie down in bed. She had a sensation as if foreign bodies, such as peas or balls, were embedded in the skin. Antidiabetic diet had a remarkable influence on the eruption, which rapidly disappeared. Coincidently she lost the feeling of foreign bodies in the skin. In the course of two or three weeks she was able to use her hands, walk and lie on her back. When the patient first came under their observation, the eruption, when seen from the other side of the room, looked very much like confluent smallpox in the suppurative stage. Dr. Abraham has had a case of xanthoma in a diabetic woman, 32 years of age. The eruption had been in existence for four months. She was subject to biliousness. The lesions were painful when pressed. Women are much less liable to diabetic xanthoma than men.

Xanthoma diabeticorum, or the diabetic type as it is also called, differs in some particulars from the other varieties of the disease. The onset is more rapid in diabetic cases and the eruption may speedily vanish, as in Sherwell and Johnston's case. The lesions are of somewhat different aspect. They present some signs of

3. Journal of Cutaneous and Genito-Urinary Diseases, Sept., 1900.

Digitized by Google

inflammation, and consist of yellowish points on hyperemic bases.

The lesions of xanthoma usually remain for a long period or during life. In a few instances they have spontaneously disappeared without leaving pigmentation or cicatrices.

In cases of xanthoma multiplex the lesions are generally both plane and nodular. The spots are more common on the eyelids and flexures; the tubercles most frequently occur on the knuckles, elbows, knees and buttocks. The disease is commoner on the limbs than on the trunk. Lesions on the knees may be the source of discomfort or pain.

PSEUDOXANTHOMA ELASTICUM.

Under this title Balzer described a form of eruption which bears some resemblance to that of xanthoma, being of a yellow color. Microscopically, however, it seems to be due to fatty degeneration of elastic tissue. A second case has been reported by Chauffard, and a third by E. Bodin. In these three cases the lesions were found on the front of the abdomen, base of the neck, axilla and groin; the knees, elbows and eyelids were free from disease. The evolution was slow; there was neither jaundice nor liver trouble, but there was tuberculosis in every case. The lesions were small masses of granular substance constituted by swollen and segmented elastic fibers, etc. Bodin regards this species as only provisionally attached to true xanthoma.[4]

PATHOLOGY.

Xanthoma is a connective-tissue new growth undergoing fatty transformation. The lesion consists of irregular, uncircumscribed aggregations of large cells which have a clearly defined outline and possibly a cell wall with small nuclei, sometimes several in a cell, and with cytoplasma, characterized by closely massed fat globules. The cells occupy the spaces between the bun-

4. Journal des Maladies Cutanées et Syphilitiques, 1901, p. 122.

Digitized by Google

dles of connective-tissue fibers belonging to the reticular layer of the corium, sometimes extending to the papillary layer. The epidermis shows slight atrophic changes. According to Touton, the fat is deposited in proliferated connective-tissue elements. In sections made by Prof. Joseph McFarland, there were scarcely any evidences of inflammation exhibited. Some writers, as Crocker, Chambard and others, believe that the disease originates in a chronic inflammation with proliferation of round cells. As these are not invariably present, however, Touton and others refuse to accept the inflammatory theory. All authorities agree that it is the fat in the cells that gives them their yellow color.

Pollitzer, following Unna, teaches that xanthoma of the eyelids is due to degeneration of muscular fiber embryonically displaced, and that it differs from xanthoma tuberosum and xanthoma diabeticorum in this respect. Clinically, I should regard the different forms of the disease as the result of a process identical in its nature, though differing in some histologic details perhaps, for, as in the case which I now report, we see plane and nodular lesions on the same person. Not infrequently the disease begins on the eyelids and spreads to other parts of the body.

ETIOLOGY.

In reviewing the course and associations of the disease, I have anticipated some of the chief points of etiology. I have spoken of the close connection which often exists between xanthoma and disease of the liver, gout and diabetes, and that it may be of congenital or hereditary origin. Xanthoma palpebrarum is more common in women than in men, contrary to what occurs in xanthoma of diabetics. It generally begins in middle life, and is most frequent in people of dark complexion.

TREATMENT.

When xanthoma is confined to the eyelids, or when the tubercles are not numerous, they may be removed by

Digitized by Google

excision. Great care must be taken in order to avoid the occurrence of ectropion or epiphora. Cauterizing and curettage have sometimes succeeded. Kaposi used soft soap. Morrow, in a case of nodules on the soles and knees, effected an improvement by means of a 25 per cent. salicylic acid plaster. Dr. James C. Maguire made use of monochloracetic acid, applying it to a small spot at a time and gradually going over the entire diseased area. A 5 to 10 per cent. solution of mercuric chlorid in collodion has been recommended. Electrolysis has been used by Hardaway, Wende, Pansier and Leviseur. Dr. Willmott Evans treated a case by means of the *x*-ray. The disease affected both elbows, and was of seven years' duration. He subjected one elbow to ten exposures of fifteen minutes each with a very satisfactory result, the elbow becoming practically clear.

Wilson and Besnier advised constitutional treatment. The former gave nitrohydrochloric acid, with an occasional blue pill, followed by arsenic. Besnier administered phosphorus first, succeeded by arsenic, and reported a rapid removal of the growths by this method.

The diet and other measures which are of service in diabetes have exerted an excellent influence on xanthoma, due to that disease. Arsenic has also been given with asserted benefit.

TREATMENT AND PROGRESS OF THE PRESENT CASE.

The patient was first seen on Oct. 16, 1903. On account of his unsatisfactory general condition he was then ordered:

℞.	Ferri lactatis .....gr. 1/4	016
	Strychninæ sulphatis .....gr. 1/100	00065
	Acidi arsenosi .....gr. 1/100	00065
	Salicini .....gr. ii	12

M. Ft. pil. No. i. Sig.: One such pill to be taken three times a day.

No local application was given, as the disease was so widely spread. On November 6 the boy's subjective condition was somewhat improved. On November 13 he reported that he felt better, and it was thought that he was a shade less pale. He was kept under observation, and on Jan. 22, 1904, was again brought before the class. At that date it was evident that he was losing ground. The anemia had increased. On March

Digitized by Google

23 he was thinner—a mere skeleton—and was having night sweats. An examination of the chest gave a negative result.

On April 23 the patient's abdomen was distended and very hard on the right side. He was very weak, had lost appetite, had abdominal pain, and sometimes vomiting. He was placed on:

℞. Acidi nitrohydrochlorici dil.....m. x |60
Tinct. gentianæ co. .....3i 3|75
M. Sig.: One such dose to be taken after each meal.
He was also ordered:
℞. Pil. strychninæ sulphatis.....1/60 |0011
M. Sig.: For one dose (before meals).

Xanthomatous deposit was probably taking place in the liver.

The boy had been watched most carefully by the clinical assistants. His father brought him to the dispensary at stated intervals. With the exception of some slight improvement at first, his condition gradually grew worse. At about the time of the last note one of the assistants visited the patient at his home—he lived in a distant part of the city—and found him in a feverish state, very much prostrated.

REMARKS.

This is a very interesting case, an excellent example of xanthoma multiplex. The exquisite symmetry with which the lesions were arranged, more particularly on the hands and arms, claimed attention, and is quite characteristic of the variety of the disease by which we were confronted. It was a case of xanthoma multiplex exhibiting patches, tubercles and nodules, both discrete and confluent. Although the eyelids are the commonest site of the eruption, and although they were typically involved in this case, yet it was not in this situation that the disease first made itself manifest.

The morbid process began at an early age in this patient. With the exception of the few congenital or hereditary cases, xanthoma develops, in most instances, after the age of 40. The lad was naturally of light complexion, which is also against the rule. The rather plentiful deposit of xanthomatous material on the mucous membrane is among the less usual manifestations. Although I have observed a number of cases of the disease,

Digitized by Google

yet this was the first occasion in which I had seen it attack the mucous membrane.

The poor physical development of the lad and his unpromising systemic condition are to be specially noted. As a general rule, the prognosis of xanthoma is good as to life. The genesis of his case seems to depend on the renal involvement with an inactivity of the liver and anemia, as evidenced by the examination of the urine and blood. The stunted growth would seem to be only an interesting coincidence.

The evolution was rather rapid considering the large amount of surface covered. In this respect it somewhat approximates the cases observed by Korach and Hertzka. Its progress was accompanied by much itching. This symptom is more particularly distinctive of diabetic xanthoma, but no sugar was found in the patient's urine.

The pain elicited by contact with the lesions was a marked feature of the case.

Cases exhibiting multiple lesions are rare. The striæ so well marked on the hands are not unusual in cases affecting the palm. The case recorded by Duhot also illustrated this arrangement. In Duhot's case the generalization was very complete, but, unlike that which I here report, the face, neck and genital organs were spared. The lesions consisted of tubercles and tumors; they were yellow and firm. The palms and phalanges were striated. Some tumors had spontaneously and entirely receded. In Duhot's case there was no diabetes, but hepatic antecedents were noted.

The coalescence of adjacent lesions was particularly observable in the case of my patient.

DISCUSSION.

Dr. A. W. Brayton, Indianapolis—Dr. Shoemaker has emphasized the extreme rarity of these generalized cases of xanthoma which justifies him in calling attention to them. I saw a case in Indianapolis several years ago, in a woman of 39. I think one-fourth of her body was covered to the same extent and with as great a variety of lesions as in this case. I reported that case briefly in the *Indiana Medical Journal,*

Digitized by Google

April, 1900. It is the second case I have had knowledge of in which the lesions were so extensive. The urine was examined in that case with negative results. The patient has passed from my observation, but I think that if she is still living she can not recover. The lesions had been developing for three years, surrounding the eyes, involving most of the face, the knees and elbows, and particularly massive on the hands and arms and below the knees. On the shins the tumors were from the size of a wheat grain to a lima bean. On the palms the growths appeared as if strips of chamois skin were set in the "lines of life." The whites of the eyes were yellow; the urine was yellow, but gave no signs of bile pigments. The liver appeared normal. There was pruritus. Crocker states that four-fifths of the generalized cases have been associated with jaundice. The disease is rare. Ten years ago less than twenty cases of the diffuse form were known.

Dr. William Allen Pusey, Chicago—A very exaggerated xanthoma was shown some time ago before the Chicago Dermatological Society and which has recently been under my observation. The interesting point was that the patient, a boy about 16 years of age, was suffering from polyuria without sugar. The lesions were of the type of the ordinary xanthoma and did not present the picture of diabetic xanthoma. So far as I know no other case of xanthoma associated with diabetes insipidus has been recorded.

Dr. David Lieberthal, Chicago—Cases with such extensive distribution are not frequent. I wish to call attention to the fact that in this case, which is naturally one of infantile xanthoma, the eyelids are affected. In 1882 a report was made before the London Pathological Society by Startin and Mackenzie, of the published cases of infantile xanthoma, eight in all, and in none were the eyelids found to be the seat of lesions. About ten months ago, through the courtesy of Dr. L. Greensfelder, I had the opportunity to demonstrate a case of infantile xanthoma before the Chicago Dermatological Society. This was not the case mentioned by Dr. Pusey. It was a boy of 10 years, physically well developed, but morally defective, a kleptomaniac. The lesions were extensive, not only in the skin and subcutaneous layer, but tumors were also found on the tendons of Achilles. Dr. Greensfelder operated on the case to ascertain to what extent the tendons were affected, and it was found that their sheaths were free, but that the tendons themselves were diffusely infiltrated by the xanthomatous process. How shall we explain the development of fat in various localities normally free from it? There seems no doubt that there is an underlying, a severe, and probably an internal cause, especially when we consider Dr. Shoemaker's case, which shows a veritable cachexia. I would like to ask Dr. Shoemaker if lesions were found in the internal organs, in-

Digitized by Google

asmuch as there was not only extensive affection of the skin, but also lesions of the mucous membrane of the mouth and throat.

Dr. Edmund L. Cocks, New York City—In the Skin and Cancer Hospital of New York there was a case in a young woman similar to this boy's case, only the nodules of the lips and nose were larger. That case was gone over very carefully, but we could not find anything wrong except the condition of the skin. Dr. Bulkley used the α-rays and the nodules diminished almost one-third, although the striæ have not diminished to any great extent. I feel sure from the reports I have had of her case that she will recover.

Dr. Jay F. Schamberg, Philadelphia—Dr. Shoemaker's patient appears to have on the cutaneous surface every gradation of the xanthomatous process. On the eyelids are typical lesions of common xanthoma planum; on the extremities are seen characteristic lesions of xanthoma tuberosum, and on the back is an inflammatory nodule closely resembling those seen in diabetic xanthoma. The extent of the eruption and the pronounced effect on the boy's general health would suggest that he is suffering from a general disease of which the cutaneous lesions are merely conspicuous external manifestations; indeed, the clinical picture is quite analogous to a malignant internal neoplasm with multiple cutaneous metastases. What has the physical examination of the abdominal viscera disclosed, particularly in reference to involvement of the liver and spleen? It is the careful study of severe cases of this character that will doubtless throw light on the lesions of xanthoma that are so commonly seen in persons enjoying apparent health.

Dr. Edmund L. Cocks, New York City—I have carefully examined the internal viscera and find the liver is very much enlarged; in fact, we have liver dullness extending below the umbilicus up to and even beyond the fifth interspace. The spleen is also enlarged. I think Dr. Shoemaker mentions the examination of the blood, which shows marked anemia.

Dr. D. W. Montgomery, San Francisco—The boy's protuberant abdomen would signify that some of the abdominal viscera are affected.

Dr. M. L. Heidingsfeld, Cincinnati—I wish to record a case which I saw in November, 1902, in Evansville, Ind., in consultation with Dr. Sidney Eichel of that city. The individual was a cachectic white boy, aged 16 years, weight 68 pounds, height 4 feet 6 inches. Three years previously a ruptured compensation from a mitral insufficiency resulted in general edema, which was relieved by treatment, and jaundice and enlarged liver, which have continued to persist. The liver at the time of consultation extended below the umbilicus and almost completely filled the right half of the abdomen. The

Digitized by Google

xanthomatous eruption began, shortly after compensation was ruptured, over the extensor aspects of the extremities, and was very generally distributed over the entire body in tuberous form, except around the knees and elbows, where the lesions were very closely aggregated together and took on the form of xanthoma planum. Urine until lately contained albumin, but at the time of examination was normal, excepting that it was reduced in amount; its specific gravity was 1,015. His sleep until lately was disturbed by frequent micturition. Appetite remained good, bowels regular, general distress slight. All organs except liver and heart apparently normal.

Dr. L. Duncan Bulkley, New York City—When did the first signs of this disease appear?

Dr. Shoemaker—I do not think he gives a clear history. Frank, how long have you had this?

The Patient—About ten months.

Dr. William L. Baum, Chicago—In hearing the result of the blood examination I think it would be well if some examination of the pancreas were made in this case, especially as to his digestion of fats. In view of the fact that in some cases of polyuria there is a relationship with xanthoma would point to investigation along the avenues of the pancreatic cells which might show some relationship with the central nervous system. This looks to me more like a secondary toxemic effect and it would be interesting to know what Dr. Shoemaker's record of the case might be at some future time.

Dr. Henry G. Anthony, Chicago—This case, although presenting unusual features, is not difficult to diagnose. The cases which present the greatest difficulty in diagnosis are those in which there is no elevation, the lesions consisting simply of yellow spots in the skin. This variety is recognized as a separate form by the *Pratique Dermatologique.* Dr. Pusey showed a case of this character before the Chicago Dermatological Society; the spots had been present on the forehead seven years. We had a discussion in regard to the diagnosis. I thought it was xanthoma; others thought it verruca planum.

Digitized by Google

PRACTICAL NOTES ON OINTMENTS, THEIR USE AND ABUSE.

L. DUNCAN BULKLEY, A.M., M.D.

Physician to the New York Skin and Cancer Hospital; Consulting Physician to the New York Hospital.

NEW YORK.

From time immemorial ointments have been employed in treating diseases of the skin, and the numerous references to them in the Bible show how highly they were esteemed. One reference, namely, "Dead flies cause the ointment of the apothecary to send forth a stinking flavor," refers to an important point to be considered, that is, the freshness or rancidity of ointments.

While it might seem a simple and easy matter to prescribe an ointment for a diseased condition, any one who has dealt much with diseases of the skin not only often recognizes the difficulties connected therewith, but sees continually the uselessness or harm of many that have been previously prescribed for patients by others. A practical study of the subject, therefore, may aid some in avoiding certain of the errors which continually occur in this line of therapeusis. The subject is a larger one than can properly be treated of in a single paper, and many important matters must be very briefly considered.

PATENT OINTMENTS.

In regard to the innumerable patent ointments which have appeared in succession for years as cures for many or "all diseases of the skin," and some of which of late years have been so ingeniously thrust on the profession, some may have value, if rightly used in suit-

Digitized by Google

able cases, but their very number and variety show their relative uselessness. They may serve to relieve the physician of the effort necessary to prescribe a suitably compounded ointment, but experience proves their value to be extremely limited; indeed, they are often found injurious. Their uncertain composition, which is found to vary considerably at different times, and the doubtful testimonies of their efficacy, generally from unknown and inexperienced persons, quite excludes them from our serious consideration.

The United States Dispensatory contains formulæ for over fifty ointments for various purposes, many of which are well known and are of value, as recommended, but some are too weak and many of them are far too strong for ordinary use, unless diluted. It is, therefore, hardly safe to always rely on the directions there given in regard to the use of ointments in diseases of the skin.

There are so many items to consider in connection with this subject that it will be well to take them up in regular order under the following heads: 1, bases for ointments; 2, ingredients; 3, methods of compounding; 4, strength; 5, mode of application and removal; 6, indications and contraindications for ointments. No attempt will be made to fully cover all these topics, but practical suggestions are offered as to matters which experience has shown to be of importance.

BASES FOR OINTMENTS.

The first requisite for a good ointment for the skin is that its base shall be non-irritating and of a proper consistency, and the tendency of many ointments to become rancid should never be forgotten by the physician. This will sometimes happen through the carelessness of the druggist, more often by that of patients in keeping them too long. Not infrequently an old ointment will prove irritating when one freshly and properly prepared, with the same ingredients, will prove serviceable.

Lard is a common base of very many of the ointments

Digitized by Google

of the dispensatory, and to prevent its rancidity it is commonly treated with about 2 per cent. of benzoin, or originally the tincture of benzoin was added. This latter may prove irritating to the skin, and sometimes the lard is imperfectly benzoinated and will not keep.

Wax and oils also often enter as ingredients, which may likewise tend to rancidity. The petroleum products, paraffin, vaselin, albolene, etc., are also used considerably as bases, but it must be remembered that vaselin is not acceptable to every skin. Not at all infrequently an ointment made up with it will prove irritating, when the same ingredients with another base will be satisfactory.

Vaselin and albolene are often of value when it is desired to have only a lubricant, or a soft ointment to penetrate, as in the hairy scalp, but as a protective ointment it does not answer, unless materially stiffened with powder, as in the Lassar paste, or with wax, paraffin or lanolin.

Lanolin is rarely suitable as a base alone. At one time it was thought that it would be valuable as promoting absorption, when this was desired, but experiments have shown that it is far inferior to vaselin in this direction. Glycerite of starch often serves excellently as an excipient in irritable conditions, and also for general inunction after bathing, in dry conditions of the skin, but the susceptibility of some skins to glycerin must always be borne in mind, for to some it proves an irritant. Mutton tallow melted and thoroughly incorporated with enough oil, makes an excellent inunction for dry, harsh skin. Goose grease has been highly praised as an excipient, especially for parasiticides in the vegetable parasitic diseases. The newer proprietary bases, vasogen and endermol, serve good purposes and appear to be bland and unirritating.

Perhaps the most serviceable base for most ointments is cold cream, or the unguentum aquæ rosæ of the Pharmacopeia, but care must be exercised that it is well

Digitized by Google

made, and that it is fresh, as it is liable to become rancid, and the water in it to evaporate. A little carbolic acid, 1 to 2 per cent., will preserve it for a considerable length of time.

A word in regard to diachylon ointment, so commonly associated with the name of Professor Hebra of Vienna. As directed now to be made, by melting together equal parts of lead plaster and olive oil, it is not as serviceable as that made after Hebra's original formula, for the oil is not decomposed in the process. Hebra advised that the ointment be made direct from the litharge, olive oil and water, the two latter in very much larger quantities, and the water double that of the oil. The water and oil are boiled, with constant stirring, and the litharge sifted in and the whole stirred until a good soft ointment is made.

INGREDIENTS OF OINTMENTS.

While many of the standard ointments, as those of zinc, mercury, sulphur, etc., are of more or less value, used alone, undoubtedly much gain can be had by a proper and judicious combining of various ingredients to suit individual cases; although sometimes prescriptions are seen exhibiting a marvelous polypharmacy, useless if not harmful. The addition of carbolic acid, 1 or 2 per cent., is a most valuable adjuvant to many ointments, and ichthyol, 6 to 12 per cent., is also of great value as an antipruritic, as is also oil of cade. Salicylic acid is also serviceable as a promoter of the growth of healthy epithelium, and may be added to various ointments in a strength of from 3 to 6 per cent.

Many illustrations could be given of the advantage of combinations of ingredients in ointments. Perhaps the most striking is in regard to what is often known as Wilkinson's ointment for scabies, which may be further improved by the addition of tar ointment and liquid storax. It must be remembered that the ingredients of ointments must often be changed to suit individual cases, and it is not always safe to take prescriptions, of

Digitized by Google

ever so high an authority, without considering well the ingredients and their suitability to the diseased condition and the particular skin under treatment.

COMPOUNDING OF OINTMENTS.

The Dispensatory is very clear in its general and special directions in regard to compounding ointments, but, unfortunately, these are not always strictly followed, and one occasionally meets with ointments very poorly prepared. It is well, therefore, for the physician to inspect them from time to time, to be sure that they are fresh and perfectly prepared. The most common error is in having gritty particles, which are often most irritating to the surface. I have seen an ointment of red oxid of mercury, ordered for use on the eyelids, in which there were hard, solid particles, suggesting red pepper, stirred into the base.

I have also frequently met with ointments in which there was much gritty substance, easily felt in rubbing them between the fingers. All mineral ingredients should be very thoroughly triturated in a mortar, with a few drops of oil, so as to make a fine paste, which is then thoroughly incorporated with the base. The more I see of practice the more I am convinced that a certain proportion of the want of success often occurring in connection with the treatment of diseases of the skin is owing to the faulty pharmaceutical prescriptions.

STRENGTH OF OINTMENTS.

Both in health and disease individual skins differ very greatly in their reaction to external irritants, and one should always be cautious in making a first application to a skin with which there has been no previous personal experience. Irritation and harm is continually done to eruptions by too strong ointments, and it is always well to begin with a mild application, increasing the strength as indications occur. Undoubtedly the reputation which oxid of zinc ointment has acquired, and also possibly some of the patented and advertised ointments, lies

Digitized by Google

in their bland, non-irritating character, which may be all that is required in any particular case.

One will make very little headway in treating most diseases of the skin who knows only oxid of zinc ointment, although with it alone he will probably do more good and less harm than with any other single ointment.

PROPERTIES OF OINTMENTS.

The strength and composition of ointments must naturally vary very greatly with the purpose for which they are employed, and this should always be kept distinctly in mind in the treatment of any cutaneous condition. Ointments may be required for several very different purposes, and, according to their composition, their action may be: lubricating, protective, soothing, astringent, absorbent, stimulating, or antiparasitic. All of them may prove healing according to the nature of the complaint and the condition of the skin. These actions may be briefly considered.

Lubricants.—In many instances only a lubricant is wanted, and no mineral or other ingredients are required other than perhaps 1 or 2 per cent. of carbolic acid. Vaselin or albolene answers often very well, but a very valuable combination for general use is made as follows:

℞.	Lanolin	℥i	30
	Boro-glycerin	℥ss	15
	Unguenti aquæ rosæ	℥iii	90
M.			

An ointment of mutton tallow and olive or cod-liver oil, which can be cheaply made at home, is very serviceable in ichthyosis and in conditions where large quantities are long to be used. Glycerite of starch is also very acceptable to many skins.

Protective.—The protective feature of an ointment is often a very important one, which will be spoken of more fully shortly, when considering the mode of application of ointments.

Soothing Properties.—In very many diseased condi-

Digitized by Google

tions of the skin the soothing character of an ointment is that which is most required, and here it is that the ingenuity of the physician is often most severely taxed. Especially is this true when the element of itching is prominent, and when one remedy after another in ointment form will fail to give relief. In many of these instances some other application, in the form of a lotion or powder, will be more suitable.

In attempting to give relief from itching great care will often be necessary to avoid remedies which overstimulate the skin, for continually it will be seen that stronger and stronger applications are used with only irritating effect when a mild, soothing ointment will accomplish better results, especially if rightly applied. Such ointments as the following will often give relief after much more powerful remedies have failed:

℞.	Acidi carbolici	gr. v	33
	Pulv. calamini prep.	℈i	1 33
	Zinci oxidi	ʒss	2
	Ung. aquæ rosæ	℥i	30
M.			
℞.	Ung. picis	ʒii	8
	Zinci oxidi	ʒss	2
	Ung. aquæ rosæ	ʒvi	24

In increasing the strength of ointments great care should be exercised and the effect carefully noted.

Astringents.—In certain cases more of an astringent action is required, and tannin, ergot, lead and bismuth may be added to meet different requirements.

Absorbents.—Again an absorbent effect is often desired in an ointment, and the preparations of iodin and mercury prove most valuable, as also tar and its various congenors.

Stimulants.—Stimulating ointments are also often called for, especially in more chronic conditions, and there are a large number of these which, however, must be used with caution and with a definite end in view.

Many of the ointments found in current literature may be thus classed, and while in skilled hands and applied just rightly, they can be used with safety and often

Digitized by Google

with advantage; in a large share of ordinary cases they will often irritate the skin unnecessarily and be worse than useless.

Parasiticides.—Lastly, antiparasitic ointments often present considerable difficulty to those not greatly accustomed to their use, and frequently to the experienced it is a difficult matter to secure an effective ointment which is not too stimulating. Especially to the scalps of children the ointments often suggested are either too weak or too irritating. Chrysophanic acid, although a fairly efficient parasiticide, is being less and less used, owing to its objectionable staining of the skin, hair and clothes. The iodin preparations and soluble mercurial ointments, such as the oleate and diluted citrine ointment, together with salicylic ointments, afford the best results.

MODE OF APPLICATION.

The mode of application and removal of ointments are often very important matters, about which far too little thought is given, for these have much to do with their good or bad effect. It is rare to find that specific directions have been given to patients, and yet, as it is often their first experience in this procedure, it is hardly to be expected that they will understand exactly the way to apply them in order to get the best results. The usual direction is simply to apply some of the ointment morning and night; and very commonly patients will diligently wash off one application before the next one is made, and not infrequently their faulty method of treating the skin will do much to counteract the benefit from the ointment used.

The mode of application of an ointment must vary greatly, according to the purpose for which it is used. Thus, when an ointment is used for lubricating, as in ichthyosis, xeroderma, or in a slight general eczematous state, the soft ointment should be taken on the palms and the body freely anointed, with friction, morning and

Digitized by Google

night, until much of the ointment has been absorbed. Also in the treatment of scabies the appropriate ointment should be rubbed in, with the palms, over all the affected parts, and even for half an hour, until it has well penetrated the furrows made by the insect, and a considerable quantity should be left on, so that the underclothing becomes pretty well saturated with it.

On the other hand, however, on a more or less raw, eczematous surface such a procedure would be anything but beneficial, and the ointment should be thickly spread on the woolly side of lint and firmly bound on the part with as light a gauze bandage as possible. The same is true when it is applied to such a lesion as pemphigus or an ulcerating surface. In this latter case, however, it is often well to spread the ointment on very thin layers of absorbent cotton, held on the hand, which may be made to fit an uneven surface, and on removal they will come off easier, without tearing the newly formed granulations. This method is also peculiarly satisfactory in eczema about the anus, and in hemorrhoids, as it can be well tucked in and keeps its position.

Between these two extremes there are varying degrees of active application of ointments, and patients must be instructed just how to use them or much of the benefit will be lost. Thus, in parasitic diseases of the scalp, after clipping the hair very short, it is often well to apply the ointment with a stiff stencil brush, with considerable friction, working it well into the follicles, and the same mode of application is valuable in hard patches of psoriasis on all parts of the body.

Again, in old patches of eczema there is often much benefit from a greater or less friction with the finger, or often with a bit of flannel with the ointment, after which the patch is covered with the same spread on the woolly side of lint and bound firmly in place. In many cases of eczema or psoriasis about the hands it is almost impossible to make any progress unless the proper ointment is

Digitized by Google

kept bound on the affected part all the time, night and day, for a while.

In itching conditions it may be necessary to renew the applications of ointment many times daily, and in eczema of small children the direction should be to replace it as often as it is rubbed off or the dressing becomes at all deranged.

In general itchy conditions, as pruritus and urticaria, it may be necessary to make applications of an antipruritic ointment many times day and night.

Often one sees very poor results in the using of ointments, resulting from the coverings or dressings which are placed over them. It is not at all uncommon to see a diseased surface to which ointment has been applied, covered with old linen or surgical gauze, which readily absorbs the greasy portion of the ointment very shortly, and leaves the affected portion dry, perhaps coated only with the mineral or other ingredient. This is not at all conducive to the healing of the part.

As has been already mentioned, the best results are obtained when the proper ointment has been spread thickly on the woolly side of surgical lint, or spread on very thin layers of absorbent cotton, and bound firmly on the part.

Many errors continually occur unless careful and explicit directions are given by the physician in regard to the removal of ointments and the subsequent treatment of the diseased surface. It seems to be the universal idea that such should be frequently washed, and one continually finds healing prevented by the application of soap and water, daily or oftener, when with proper use of the same ointment good results followed.

Rarely, is it advisable to wash surfaces which are at all raw, and all the cleansing necessary may be accomplished by the gentlest wiping with absorbent cotton. Much harm is also often done by a rough removal of ointments and dressings. When the latter adhere too closely it is generally because there has been too little ointment

Digitized by Google

used or an improper covering made. If on removal of a dressing there is much ointment on the skin which it is desirable to remove, this can often be best accomplished by means of a dull knife, if gentle wiping with absorbent cotton is not effective.

INDICATIONS AND CONTRAINDICATIONS FOR THE USE OF OINTMENTS.

It is not always an easy matter to know just the exact indications for the employment of this or that kind or strength of ointment, or, for any ointment, in preference to some other kind of dressing, and disappointment will occasionally follow the best directed efforts. In some acute inflammatory conditions of the skin lotions and powders suit far better than ointments of any kind, while in the more chronic conditions, with dry, rough skins, ointments are, of course, called for.

The exact kind and strength of ointment can be determined only after a careful study of the skin, lesions present, and their acute or chronic state or condition, and also after a full appreciation of the character of the skin of the individual under treatment.

In general, a thin, delicate skin, especially in one with a light complexion and hair, will bear and require much milder applications than a thick, tough skin, especially in a brunette.

The single or localized patch of chronic eruption will, of course, bear and require much stronger applications than an acute or generalized eruption. While the sensations of the patient will commonly determine the continuance or disuse of an ointment, and great harm is not often done by too strong applications, our efforts should undoubtedly be directed to securing an application which will be effective and accomplish the end desired, if that be at all possible.

Every point in a case should, therefore, be carefully weighed and the indications and contraindications looked for and appreciated, before determination is

Digitized by Google

made as to the proper ointment to apply. The almost universal use of zinc ointment is largely explained by its relative harmlessness, on the principle of the Irishman's holy water, who explained that, "if it does you no good it will do you no harm." This, however, is a poor principle to go on in the treatment of diseases of the skin, which often require very active measures for their removal; and, as before remarked, he is very poorly equipped for their treatment who knows only zinc ointment.

In concluding these brief practical notes on the use and abuse of ointments, for the general physician, I must utter the caution that we have been considering only one side of the great subject of the treatment of diseases of the skin, and one which is often the least important. All local measures are constantly found to be ineffective unless proper and adequate internal and general treatment is adopted and earnestly and faithfully carried out.

Digitized by Google

LINEAR NEVI.

A FEW CLINICAL AND PATHOLOGIC CONSIDERATIONS IN REFERENCE TO NEVI IN PARTICULAR AND TO DERMATOLOGY IN GENERAL.

M. L. HEIDINGSFELD, M.D.

CINCINNATI.

Inasmuch as the entire subject of nevi is still a dermatologic dark Africa, and linear nevus forms an intricate and obscure division, I will endeavor to confine myself in this paper to a few brief, chiefly histologic considerations, and their application to linear nevi in particular and dermatology in general. So many anomalies, e. g., pigmentations, albinism, hirsuties, angiomata, teratomata, keratomata, atheromata, port-wine stains, defects, etc., are included under the technical term nevus, that it is unfortunate that its original lay character should have acquired scientific value. Additional confusion has attended this unfortunate interchange of terms, by the fact that identical lesions escape classification if their distribution is general instead of limited, and that their development need not be coincident with birth, but months or even years after. Linear nevi not only share in the confusion which attaches itself to nevi in general, but that due to a verbose redundant terminology, replete with almost every variety of dermatologic phrase or term, such as nevus congenitalis, zoniformis, herpetiformis, linearis, papillaris, lichenoid, ichthyotic, eczematous, keratotic, pigmented, piliferous, hystrix, nigricans, papillomatous, verrucosus, etc., to suit almost every variety of clinical condition.

Digitized by Google

This unfortunate redundant terminology has been rendered permissible by the great clinical variations which exist in individual instances; at the same time the general characteristics of the affection are so clean cut and definite, and stamp it so individually and unmistakably, that any great digression in nomenclature ap-

Fig. 1.—Case 1. Linear nevus, showing marked spontaneous regressive changes. Dendriform lesions. Photo Jan. 16, 1901.

pears unpardonable. Additional latitude is likewise afforded by an equally variant histology, and though this special feature of the affection has not as yet been extensively elaborated, enough has already been produced to demonstrate that in this distinctly one affection many varieties of pathologic lesions are readily found, making

Digitized by Google

its pathology when strictly interpreted as complex and unintelligible as the clinical history. With all this, nevus linearis is a dermatologic affection, *sui generis,* possessing a complete entity, and for the most part a very easily recognizable identity. With these characteristics it serves an interesting and instructive example of the foibles and weakness of present dermatology,

Fig. 2.

namely, the tendency to individualize and thereby complicate, rather than generalize, and thereby simplify single types in classification; and secondly, the tendency to give to dermatologic histopathology a diagnostic rather than mere confirmatory value. In other words, there are many cases in dermatologic literature, which are reported as special and distinctive types of affection, by authors who doubtless could readily find

Digitized by Google

a place for them in the already overelastic nosology, if less attention were directed to individual traits and more to general description.

According to Morrow,[1] the distinguishing characteristics of linear nevus are: 1, Its linear disposition in the form of continuous or broken bands or streaks following the long axis of the limb or transversely on the trunk; 2, its unilateral disposition (with some exceptions); 3, papillary or verrucose character, constituted by a hypertrophy of the epidermal and papillary structures; 4, congenital origin, usually present at birth or several months afterward, rarely not before adolescence; 5, sensory disturbances, such as itching, and usually resulting from external irritation; 6, the affection may increase in extent, remain stationary, regress or undergo degenerative or malignant transformation. These features of the affection, gathered from the cases from the literature and from Morrow's own cases, present variations, and are by no means constant. In fact, the character of the affection is so distinctive that it requires but few of Morrow's characteristics to form a tripod on which the diagnosis can unmistakably and securely rest.

The following three cases, which were presented to the Cincinnati Academy of Medicine, Jan. 28, 1904, are briefly reported:

CASE 1.—(Fig. 1.) W. M., male, aged 20 years. The lesions are firm, hard, papular, somewhat elevated and keratotic, sharply circumscribed in character and brownish-red in color. They are sharply limited to the right half of the body, and are distributed in linear form directly over the great sciatic nerve, from its point of origin at the ischio-sciatic foramen, along its entire course, down the posterior aspect of the thigh, to its division into the internal and external popliteal branches. From this point it is distributed in broken segments along the internal popliteal nerve, over the posterior aspect of the calf of the leg, and also along the external popliteal nerve over the external and anterior aspects of the leg, near the fibula. The second distribution is over the right half of the penis and scrotum, which are richly covered with a large number of linear filaments, none of which, however, transgress the median line.

1. Morrow: New York Med. Jour., 1898.

Digitized by Google

The third distribution is over the right aspect of the forehead and nose and consists of a few relatively faint linear filaments, that are sharply arrested at the median line. According to statements of both the intelligent mother and patient, the congenital lesions were not present at birth, but developed a few years later, and have persisted ever since, with relatively little change. The only subjective symptom has been an occasional pruritus, but not very annoying in character. The objective disfigurement, coupled with the fear that the lesions

Fig. 3.—Case 3. Linear nevus of sharp unilateral character, with multiform lesions. Photo March 12, 1900.

might terminate into something more serious, induced him to seek medical attention. He maintains that his case was never thoroughly understood nor any medical relief afforded until the present diagnosis was established four years ago. Figure 1 shows the condition one year later. During that year the case showed marked retrogressive changes, the lesions having spontaneously disappeared over the middle third of the thigh. The linear distribution and dendritic or branching character of the lesions are well marked in this photograph.

Digitized by Google

Since then there has been a gradual and spontaneous recurrence of the lesions until the distribution at the present time corresponds closely to the distribution as observed when the patient was first seen. It is noteworthy to mention that the lesions always recurred exactly over their former site.

CASE 2.—(Fig. 2.) J. S., aged 38 years, male, presented himself for the first time July 30, 1902, when the accompany-

Fig. 4.—Case 3. Showing great multiplication of lesions in short time. Photo Jan. 23, 1904.

ing photograph was taken. The nevus in this case is situated over the left antero-lateral aspect of the scalp, covering a relatively large, irregularly shaped area, not corresponding to the distribution of any particular artery, nerve, metamere, or line of Voight. In this case the presence of the nevus dates to the birth of the patient, and was yellowish in color and smooth in

Digitized by Google

character. It has remained without material change, with the exception that it has grown decidedly warty in recent years.

CASE 3.—H. C., aged 10 years, female, presented herself four years ago, March 12, 1900, with a nevus, present from birth, showing no material change, and with a distribution over the left side of the neck, as recorded by the accompanying photograph (Fig. 3). The lesions for the most part were small, papular and sharply circumscribed, smooth, non-elevated in character, reddish-brown in color, and scattered irregularly

Fig. 5.—Case 1. Chief pathologic change is heaped up layers of imperfectly keratinized epithelial cells.

over the affected area. A few were dark and pigmented; on the forehead and scalp the lesions were yellowish in color and preserved a linear arrangement, but were so closely grouped that they formed an irregular, diffused, sharply defined area about the size of a silver half-dollar. Some of the lesions at the time were successfully removed by electrolysis. On Jan. 23, 1904, patient presented herself for the second time, when the next accompanying photograph was taken. (Fig. 4.) At this time a material change was noted. The former smooth, yellowish patch on the forehead had become rough and warty, and was

Digitized by Google

studded with several papillomatous prolongations. The lesions over the neck and cheek had greatly multiplied in number and now extended down over the chest in great numbers as far as the nipple. The new lesions for the most part were small, sharply defined, darkly pigmented papules, having individually a close analogy to common moles, or, on the whole, a more striking resemblance to the cutaneous metastases of a pigmented sarcoma. The unilateral character was still sharply maintained and the median line was not transgressed.

If we group these three cases together, the most striking characteristic common to all is congenital origin. Even this character requires in Case 1 the more recent and liberal interpretation of congenital lesions, which the most conservative (Besnier included) are nowadays willing to grant, and that is that their visible appearance need not date from birth, but months or years later. By far the vast majority of cases reported in the literature are present at birth or shortly afterward. Among those who report a later development are Leven[2] (fourth week), Dyer[3] (sixth week), Ransom[4] (sixth month), Lanz[5] (first year), Werner[6] (first year), Buri[7] (second year), Köbner[8] (second year), Phillipson[9] (second year), Hagen[10] (third year), Gerhardt[11] (third year), Fox[12] (tenth year), Touton[13] (sixteenth year), Dyer[3] (seventeenth year), Hallopeau and Jeanselme[14] (twentieth year). Jadassohn[15] (p. 372) states that the lesions of this affection are due to general causes, that it is impossible to give to it an anatomic ensemble, and, therefore, the term nevus is an indispensable one.

The next most noteworthy feature of the cases is the

2. Leven: Deut. med. Woch., 1897, No. 41.
3. Dyer: Jour. Cutaneous and Genito-Urinary Diseases, vol. xvii.
4. Ransom: Jour. Cutaneous and Genito-Urinary Diseases, 1896, xiv, p. 141.
5. Lanz: Dermatolog. Zeitschr., vol. i, No. 2, 1894.
6. Werner: Arch. f. Derm. u. Syph., vol. xxxiii, p. 341.
7. Buric: Monatsh. f. prakt. Dermat., July 1, 1899.
8. Köbner: Arch. f. Derm. u. Syph., vol. xxxiii, p. 393.
9. Phillipson: Monatsh. f. prakt. Derm., vol. ii, 1890, p. 338.
10. Hagen: Münch. med. Woch., 1897, No. 19.
11. Gerhardt: Jahrb. f. Kinderheilk., iv, 1871, p. 270.
12. Fox: Brit. Jour. Derm., 1902, p. 56.
13. Touton: Vehr. d. Deut. Derm. Gesell., Fifth Congress, p. 418.
14. Hallopeau and Jeanselme: Annal. de Dermatol., 1894, p. 1273.
15. Jadassohn: Arch. f. Derm. u. Syph., vol. xxxiii, p. 359.

Digitized by Google

unilateral distribution of the lesions which, though extremely well marked in two of the cases, is not so apparent in the third (Case 2), because the median line is not approached.

Most of the cases in the literature possess a distinctly unilateral character, the lesions in most instances rarely transgressing the median line anteriorly or posteriorly. The most prominent exceptions are reported by Dyer[3] (3 cases), Pringle[16] (1 case), Spietschka[17] (1 case) Gerhardt[11] (1 case), Ransom[4] (1 case), Köbner[18] (1 case).

The next most salient characteristic is its linear character and disposition,[19] or rather lack of disposition along nerves, lines of Voight, lymph-vessels or other structure.

The disposition along structural elements is likewise apparent only in Case 1, and here closely follows, in rather remarkable manner, the great sciatic nerve and its branches.

These variations in form and distribution conform with the general report of cases. Among those who report a nerve distribution are Saalfeld,[20] Jadassohn[21] (4 cases), Köbner,[18] Simon,[22] Barensprung,[23] Lommel,[24] Etienne[25] (3 cases), Brocq,[26] Campana[27] (11 cases). Among those who maintain a line of Voight distribution are Hagen,[10] Phillipson,[28] Peterson,[29] Galewski,[30]

16. Pringle: Brit. Jour. Derm., 1896, p. 330.
17. Spietschka: Arch. f. Derm. u. Syph., vol. xxvii, p. 27.
18. Köbner: Arch. f. Derm. u. Syph., 1888, pp. 393-394-933.
19. A pronounced linear character, is well marked only in Case 1, and is at best only faintly indicated in the two remaining cases.
20. Saalfeld: Alleg. med. Centralz., 1892, No. 102.
21. Jadassohn: Arch. f. Derm. u. Syph., 1888, p. 917.
22. Simon: Arch. f. Derm. u. Syph., 1872.
23. Barensprung: Charité Annalen, 1863, vol. iii, No. 2, pp. 91-95.
24. Lommel: Munich med. Woch., 1903, No. 36.
25. Etienne: Nouv. Icon. d. l. Saltpel., 1897, Abst. Brit. Jour. Derm., 1898, p. 28.
26. Brocq: Annal. de Dermatol., 1894, p. 791.
27. Campana: Giorn Ital. d. Mal. Ven. e delta pella, October, 1896.
28. Phillipson: Monats. f. prak. Derm., vol. ii, p. 337.
29. Peterson: Arch. f. Derm. u. Syph., 1892, pp. 919-930.
30. Galewski: Monats. f. prak. Derm., vol. xvii, p. 402, Soc.

Digitized by Google

Pecirka,[31] Buri.[7] Meissner[32] reports a distribution along lymph vessels. Lanz,[5] Abraham,[33] Pringle[16] and others are opposed to nerve and line of Voight distribution, or any particular form in general. (Kaposi[34] states in his text-book "that there is a close relationship between nerves and linear nevi can not be denied from their oft-distinct zoster-like unilateral distribution, and their

Fig. 6.—Case 2. Chief pathologic change of this case is a papillomatous structure.

parallel course over the nerves of the extremities, but an absolute proof is still wanting." He believes that their presence can be more easily accounted for by developmental error than by innervation influences, and that the term "nerve nevi" is merely conventional and without neuropathic importance.) Galewski[35] reported a case of nevus linearis, with a line of Voight dis-

31. Pecirka: Monats. f. prak. Derm., vol. xiii, 1891, p. 170.
32. Meissner: Derm. Zeitsch., vol. ii, No. 5.
33. Abraham: Brit. Jour. Derm., 1902, p. 182.
34. Kaposi: Hautkranheiten, 1893, pp. 590-591.
35. Galewski: Vehand. d. Dent. Dermat. Gesell., Fifth Congress.

Digitized by Google

tribution, before a congress of German scientists, at Nuremburg in 1893, and Saalfeld[20] in discussion questioned the character of the distribution, and Galewski in reply admitted that he could not state in the case in question, whether the distribution followed the lines of cleavage, nerves or Voight's lines.

The remaining so-called distinguishing characteris-

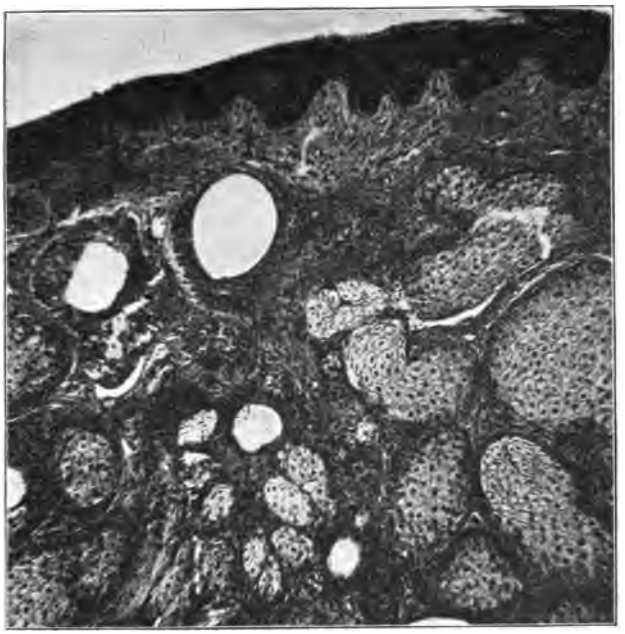

Fig. 7.—Case 3. Adenoma of the sebaceous glands from yellowish lesion of the scalp.

tics of the affection also showed some clinical variations. Stability of the lesions were only marked in Case 2; in Case 1 they constantly recurred and retrogressed, and in Case 3 there was an extensive and rapid development in four years' time. Sensory disturbances were entirely absent in two cases, and only slightly (mild pruritus, not constant) present in Case 1. The individual lesions, though for the most part warty and papular,

Digitized by Google

presented wide differences in size, consistency, arrangement and location, even showing almost every degree of variation in one patient (Case 3).

The variations in stability, above mentioned, are frequently encountered in the literature, and reference to specific examples seems superfluous. Some marked instances in the clinical appearance of the lesions are instanced by Selhorst,[36] Mendes da Costa,[37] and Thibierge,[38] who report lesions which closely resemble commedones or acne. Köbner[8] describes a case with xanthoma-like lesions. Jadassohn[39] reports that two of his cases were incorrectly diagnosed pityriasis versicolor. Touton[13] reports a case under the name "neurodermatitis linearis chronica," which is pronounced linear nevus by Jadassohn and Galewski. Robinson,[40] on the other hand, reports a case "nevus linearis," which is pronounced by Lutz keloid or papilloma. Fox[41] records an apparent case under the name localized ichthyosis. Brocq[26] a case as lichen simplex chronicus. Hallopeau[14] reports one as nevus linearis lichenoides, which he would have diagnosed, on account of its late appearance (twentieth year), lichen planus, had not the slight prodromal itching ceased entirely. Fox[12] reports the lesions of one case as probable myomata. Fox,[42] in another case occurring in the scalp, states that many cases of so-called white moles and congenital alopecias are probably "nevi linearis."

From the foregoing brief clinical descriptions, and the superficial survey of the literature, the very complex, diverse clinical nature of this affection is readily apparent. And yet in spite of its multifold nature, its

36. Selhorst: Brit. Jour. Derm., November, 1896.
37. Mendes da Costa: Nederland Tijdsch. v. Geneesk, Deel, No. 7, Abst. Brit. Jour. Derm., 1897, p. 207.
38. Thibierge: Annales, 1896, p. 1298.
39. Jadassohn: Arch. f. Derm. u. Syph., loc. cit., 1888, p. 933.
40. Robinson: Jour. Cutaneous and Genito-Urinary Diseases, vol. iv; Monats. prak. Derm., 61, p. 536.
41. Fox: London Derm. Soc., Oct. 13, 1897; Brit. Jour. Derm., November, 1897.
42. Fox: Brit. Jour. Derm., 1898, p. 21.

Digitized by Google

burdensome nomenclature, the endless variety of lesions, their obscure and variegated distribution, and their varying stability and instability, there is something to the clinical ensemble that is clear, distinctive and clean-cut, and readily gives the affection an unmistakable identity. It is strange to state, that however diverse its clinical history, its histopathology presents a still more diversified character. There is scarcely an element of the skin, epidermis, dermis or glandular element that is not involved in some form of pathologic change; stratum corneum, rete spinosum, papillæ, lymph and blood vessels, sebaceous and sudoriferous glands, pigment cells, hair and their follicles are all variously and unequally involved in some form of change. Pathologic variations and differences exist not only in separate individual cases of this distinctly one affection, but often in one and the same case, so wide in range and sweeping in character as to almost precipitate us in an abyss of histologic agnosticism. Not only is there a marked lack of analogy of the lesions for each other, but there exists at times the most striking analogy for affections totally different in character; warts, moles, adenomata, sarcomata, clavus, false and true keloid, xanthoma, etc., are so closely imitated in histologic structure that a discrimination is deceptive, if not impossible.

In Case 1 the chief pathologic change (Fig. 5) is a hyperkeratosis, consisting at times of a single heaped-up layer of only partially keratinized epithelial cells which, for the most part, retain a fairly well-developed nucleus; at times there are several successive layers of these partially keratinized cells of varying thickness and showing different degrees of keratinization. The papillæ of the skin and the interpapillary processes of the rete show a moderate amount of elongation under the hyperkeratotic area, and the involved papillæ show a moderate amount of leucocytic infiltration, commensurate with the corresponding inflammation from simple me-

Digitized by Google

chanical pressure. The general histopathologic appearance bears a very close resemblance to ordinary clavus, from which, as far as microscopic evidence shows, it is practically indistinguishable.

In the *Journal of Cutaneous and Genito-Urinary* Diseases (Vol. xviii, p. 495), there is a photogravure, in an article on "Leucopathium Unguim,"[43] representing a single layer of imperfectly keratinized hyperkeratosis, taken from this particular case. Touton[18]

Fig. 8.—Case 3. Papillomatous structure of warty excrescences.

reports a case of almost identical histologic structure under "Dermatitis Linearis Chronica," which Jadassohn and Galewski, in discussion, call "nevus linearis."

In Case 2, the chief histopathologic change (Fig. 6) in the yellowish-white, slightly papillomatous, hair-denuded lesion of the scalp (lesions which Fox[41] states are probably often reported as congenital alopecias, or white

43. Heidingsfeld: Jour. Cutaneous and Genito-Urinary Diseases, January, 1903.

Digitized by Google

moles), was a papillary hypertrophy, hyperkeratosis and acanthosis, in most respects identical and indistinguishable from the histologic structure of common and venereal warts. In other respects there were no important or characteristic changes.

In Case 3 the most interesting and varied pathologic changes are encountered. The yellowish-white, hair-denuded scalp lesion, which is analogous in size, color, location and distribution to the similar lesion in Case 2, showed a very extensive adenoma of the sebaceous glands, which consisted of huge masses of lobules, closely crowded together and occupying almost the entire cutis. (Fig. 7.) The structure and nuclei of the sebaceous cells were well maintained. The other changes were of slight character and not of noteworthy mention, except a few papillomatous excrescences, which had only recently made their appearance, and which showed the same warty papillomatous structure as Case 2. (Fig. 8.) This latter applies merely to the excrescences, and not to the adenomatous base from which they spring. This structural dissimilarity between clinically similar lesions is more striking, by reason of the fact that the lesion in Case 2, according to the patient's history, was originally smooth like that of Case 3, and the papillomatous masses had also likewise been secondarily acquired. This observation refutes Jadassohn's[15] dictum that lesions which preserve the same clinical characteristics in "nevus linearis" also maintain the same histologic structure.

Jadassohn[44] reports a similar adenoma of sebaceous glands in two cases of nevus linearis, and states that doubtless many cases reported in the literature, under the names of sebaceous adenomata, etc., can be properly classed with the linear nevi. Pollitzer's[45] case, which is reported under the name of "adenoma sebaceum," can probably be correctly quoted as an example of such

44. Jadassohn: Loc. cit., vol. xxxiii, pp. 362-363.
45. Pollitzer: Jour. Cutaneous and Genito-Urinary Diseases, vol. xi, p. 475.

Digitized by Google

incongruity. Bandler[46] reports two cases, in both of which the lesions were located on the scalp, and in both of which there were adenomata sebacea, in all respects similar in histologic structure to Case 3. Moeller[47] states that adenoma of the sebaceous glands is one of the forms of histologic change.

The lentiginous lesions of Case 3 presented various forms of histologic structure, the firm, glistening, yellowish-red, slightly elevated lesions showed a dense connective tissue hypertrophy which extensively invaded the entire cutis and pars papillaris, filling these structures with a dense meshwork of connective tissue fibers,

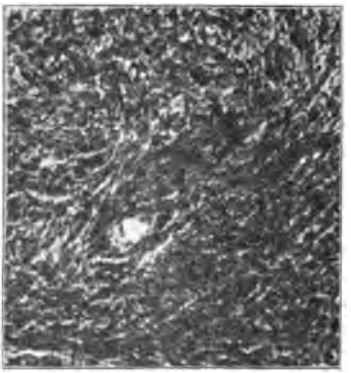

Fig. 9.—Case 3. Keloid-like structure of fibro-connective tissue, from a glistening yellowish-red lentiginous lesion.

which closely enveloped the few remaining hairs, vessels and glandular elements. (Fig. 9.) In general, the histologic appearance closely resembled and was practically indistinguishable from false or true keloid.

The slightly elevated, oval-shaped, hairy lesions, which in gross appearance resembled ordinary pigmented moles, presented the characteristic histologic structure of these lesions, a moderate cellular infiltration of the papillæ, pigment accumulation and hypertrichosis. (Fig. 10.)

46. Bandler: Arch. f. Derm. u. Syph., xlix, July, 1899, No. 1.
47. Moeller: Arch. f. Derm. u. Syph., vol. lxii, No. 1, 1902, p. 55.

Digitized by Google

The small round, darkly pigmented lesions, which were rapidly multiplying on the face and particularly on the neck and chest, showed an extensive spindle-shaped invasion of the pars papillaris (Fig. 11) connective tissue, numerous thin-walled capillaries, and a marked asymmetry of structure and arrangement that closely resembled and was practically indistinguishable

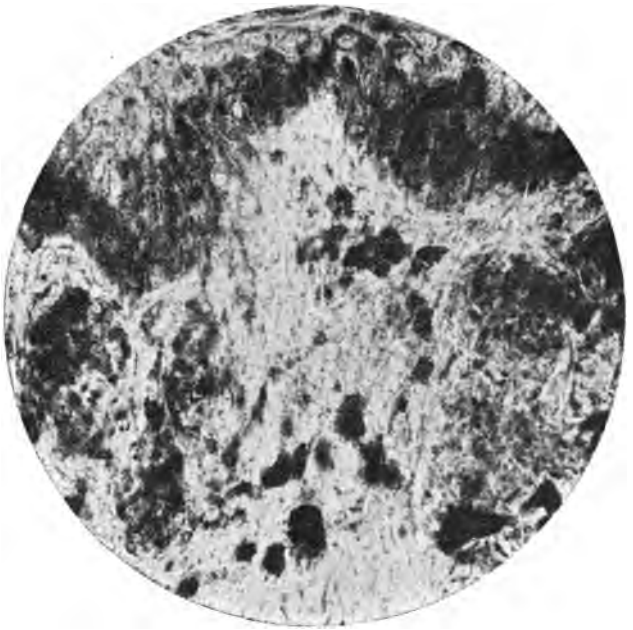

Fig. 10.—Case 3. Pigment accumulation from a small mole-like lesion.

from sarcoma cutis. (Fig. 12.) In this particular case, then, the various lesions show the most marked variety of histologic structure, varying in analogy from sebaceous adenoma to common and venereal warts, false and true keloid, moles and sarcoma, and if Case 1 is included, the histologic analogy also showed clavus.

Other histologic anomalies of linear nevi encountered in the literature, include "Adenoma of the Sudoriferous

Digitized by Google

Glands," by Peterson,[29] Elliot,[48] Beirer,[49] Selhorst[36] reports his case as histologically indistinguishable from acne vulgaris, which affection it also resembles clinically. Meissner[32] reports the histologic changes of his to consist largely of proliferated and infiltrated lymph vessels. Köbner[50] reports the histologic structure of his case, similar to that of xanthoma, and containing the yellowish-brown pigment of the latter affection, and styles it a xanthoma multiplex nevus. Although lesions contain an abundance of connective tissue and vascular elements, he objects to classifying the affection with the fibromata, because he regards the latter as invariably springing from newly formed and not pre-existing tissue. The lesions in a case reported by Fox[12] are myomatous, though they apparently lack histologic confirmation. Bertamini[51] reports spherical concretions on the surface of the skin, involving the sweat-duct orifices, and containing bodies resembling psorosperms.

It is evident that linear nevus presents clinical and histologic variations of such complex and diversified nature that if each be given special or undue significance the resulting confusion would readily permit an uncertain and doubtful classification of cases. It is this highly developed feature of present-day dermatology which encourages flagrant excesses and causes an unnecessary and unfortunate multiplication of disease. Peterson[29] utters the incrimination when he states in reference to this very condition that "it is an example of how many different forms are still gathered together under the collective name of nevus; it is high time to break the frail and elastic bonds which loosely hold together the papilloma, fibroma, adenoma, pigmented moles, etc., under a congenital mask, and name each in accordance with its histologic structure." It is the

48. Elliott: Jour. Cutaneous and Genito-Urinary Diseases, 1893, vol. xi, p. 168.
49. Beier: Arch. f. Derm. u. Syph., vol. xxxi, No. 3.
50. Köbner: Arch. f. Derm. u. Syph., 1888, 404.
51. Bertamini: Arch. f. Derm. u. Syph., vol. lxii, pp. 35-39.

Digitized by Google

converse of this proposition which is true. The present demands that the frail and too elastic bands be not ruptured, but strengthened and reinforced. It is their frailty and inelasticity that permits in great measure the unnecessary disparity in the existing classification, and to base its nomenclature on histologic structure would precipitate the affection into an inextricable state of chaos.

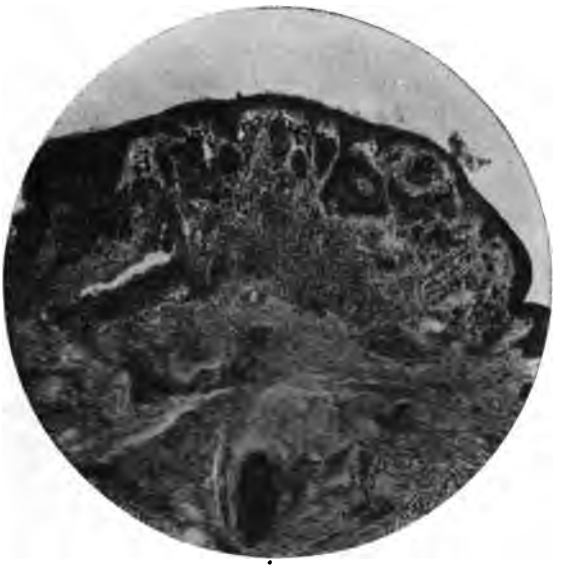

Fig. 11.—Case 3. Extensive cellular infiltration and epithelial proliferation, resembling sarcoma, from one of the rapidly multiplying pigmented lesions.

Brocq[26] reports an apparent case, with a distribution over the small sciatic and external saphenous nerve, under "Lichen Simplex Chronicus." Hallopeau and Jeanselme[14] report a case which, on account of its extreme late appearance (twentieth year), they would have diagnosed "lichen planus," had not the slight prodromal itching ceased later entirely. Robinson[52] reports an apparent case as "lichen planus," and Lutz calls a

52. Robinson: Jour. Cutaneous and Genito-Urinary Diseases, 1893, p. 286.

Digitized by Google

case presented by Robinson "keloid," or "papilloma," and takes exception to the term nevus unless applied too strictly to vascular lesions. Touton[12] reports a case as "neurodermatitis linearis chronica," which Jadassohn and Galewski pronounce "nevus linearis." Spiegelberg[53] describes a typical case under "Congenital Papilloma," and another under "Localized Ichthyosis." Flittner[54] describes a case under "Ichthyosis Cornea," Leven[2] under "Dermatitis Linearis Neuropthica," and Lommel[24] reports two apparent cases under "Chronic Zoniform Eruption," and Bertamini[51] a case as "Linear Disease."

This affection well illustrates that reformed dermatology of the future should strive for a simpler and more collective classification. It also aptly illustrates that the efforts of Phillipson[55] and others[56] to establish a reformed dermatology on purely histopathologic genetic basis is hopeless and insuperable.[43] Jadassohn, Unna[57] and Peterson have all made vain efforts to establish linear nevi on a purely histopathologic basis. Unna[57] states that he "strove to establish the conception of nevi on a series of purely anatomic considerations. The discovery that new growths pass through a very peculiar development, in which the first and last stages differ so materially in histopathology, revealed that this was an utterly impractical measure." He[58] also states that if nevi lineares are topographically similar and clinically and histopathologically different, they are not an entity, and can not be collectively grouped with nevi, and this very affection will form the starting point for an entire new study of the nevus question.

My personal impressions lead me to believe that these

53. Spiegelberg: Munich med. Woch., 1896, No. 30.
54. Flittner: Arch. f. Derm. u. Syph., 1870, p. 653.
55. Phillipson: Arch. f. Derm. u. Syph., vol. xlviii.
56. Torok: Allg. Diagnos. d. Hautkr. Veg. auf Path. Anat., Weisbaden, 1895.
57. Unna: Histopathologie der Haut., 1894. p. 1145.
58. Unna. Monats. f. prak. Derm., xii, p. 296, xx, p. 477. Report of Deut. Naturforch.

Digitized by Google

differences virtually exist, and though their explanation is not forthcoming, it is both dangerous and fallacious to establish solely for such reason new types of affection. Any three or more characteristics, as tabulated by Morrow, or gleaned from carefully reported and well-observed cases, is a sufficient tripod to rest a secure diagnosis. The affection exquisitely demonstrates the unreliable aid of the microscope, yet Unna admits that he would have diagnosed one case a chronic eczema

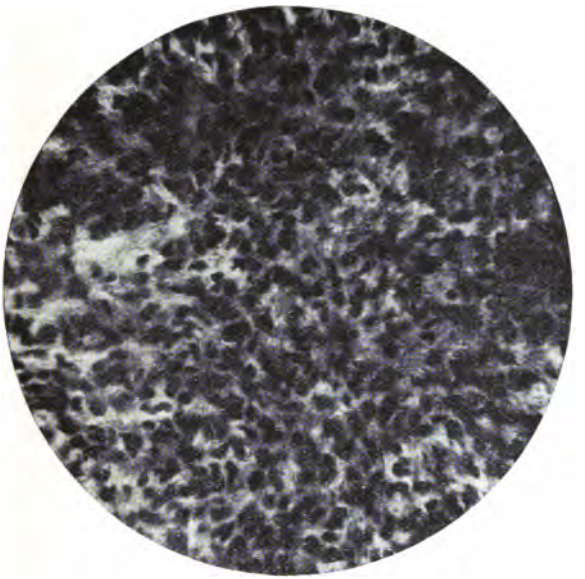

Fig. 12.—Case 3. Same as Figure 11, strongly magnified, showing character of cellular infiltrate.

had not the organism been absent. Magnus Moeller[47] reports a case, the diagnosis of which wavered between linear nevus and lichen planus, until firmly established by the microscope, and Bertamini[51] reports a case whose clinical diagnosis was lichen planus, and the histologic linear nevi. I do not believe that our present histopathologic knowledge, in spite of assurances to the contrary, has advanced to such a degree that the exact na-

Digitized by Google

ture of a disease can be readily determined by mere pathologic examinations. If the greatest conflict of opinion arises at times from the mere description of a cell (Plasma Cells, Unna, Marschalko,[59] Neisser,[60] Jadassohn, Almkoist,[61] et al), it is not suprising that an utter lack of uniformity should attain in the histologic considerations of general conditions, attributable to more than a varied location, duration, secondary changes, therapeutic influences and technic. In the effort to give histopathology its greatest degree of importance, it is being robbed of much practical value by imparting to it too much intricate detail. With all its classic interest and all its intrinsic worth, nevus linearis clearly illustrates that it possesses at best mere confirmatory value.

To briefly recapitulate, linear nevus is a dermatologic affection, for the most part easily recognized as a type of *sui generis,* possessing an unmistakable identity. Great variations in clinical appearance, location, duration, distribution, development and secondary changes have permitted an endless amount of unnecessary confusion in classification, and an unfortunate redundant nomenclature. It also possesses an exceedingly varied pathology. Great disparity in histologic structure exists between lesions that are clinically similar; great disparity exists between lesions in close proximity from the same patient; a deceptive histologic resemblance often exists between lesions of linear nevi and types of dermatologic affection, totally different in character. The affection aptly illustrates some foibles of present-day dermatology, namely, the tendency to individualize and thereby complicate, rather than generalize and thereby simplify single types in classification; and secondly, to give to dermatologic pathology an inflated diagnostic rather than a mere confirmatory value.

59. Marschalko: Arch. f. Derm. u. Syph., xxx, p. 3.
60. Neisser: Arch. f. Derm. u. Syph., xxxi, p. 387.
61. Almkoist: Arch. f. Derm. u. Syph., lviii, p. 91.

Digitized by Google

THE TREATMENT OF LUPUS ERYTHEMATOSUS BY REPEATED REFRIGERATION WITH ETHYL CHLORID.

M. B. HARTZELL, M.D.

Associate in Dermatology, University of Pennsylvania; Dermatologist to the Methodist Hospital of Philadelphia and to the Philadelphia Hospital.

PHILADELPHIA.

A distinguished teacher of dermatology was in the habit of saying to his class, when presenting a case of erythematous lupus: "Gentlemen, I show you an example of a disease which, although not incapable of recovery, is the most refractory to treatment of all cutaneous affections." And I am sure that all who have had any experience, even a limited one, in the treatment of this obstinate malady will agree with that teacher. The long list of remedies to be found in every text-book of diseases of the skin said to be more or less useful (usually less than more) in this disease is additional evidence, if any were needed, of its refractoriness to treatment, for the curability of any disease is usually in inverse proportion to the number of remedies proposed for its cure. So many forms of treatment, both internal and external, have had their praises loudly sung in this affection, only to be cast aside as their uselessness became apparent, that it requires no little courage to propose a new one; and I hasten to say that the method of treatment which I am about to describe briefly is not brought forward as an infallible cure for erythematous lupus, but as one which I have found very useful in a number of cases, after the failure of other methods.

Digitized by Google

The method of treatment to which I wish to call your attention consists in the repeated freezing of the patches of lupus at short intervals by means of ethyl chlorid spray. The diseased areas should be thoroughly frozen and kept so for five to eight minutes, and the freezing should be repeated at intervals of two to three days. Occasionally considerable inflammatory reaction follows, in which event the intervals between the freezings may be made longer—four to five days, or even more. After ten days to two weeks of this treatment considerable desquamation occurs, and the diseased areas grow much paler; and at the end of six weeks to two months small and superficial patches of recent origin may completely disappear. As illustrating this method of treatment and its results, I shall very briefly relate a few cases which have been thus treated during the past three years.

CASE 1.—The first case to be treated by refrigeration was a woman, about 40 years old, who had a number of typical patches of erythematous lupus on the cheeks, nose, forehead, behind the ears and on the scalp, causing in the last situation extensive areas of baldness. The disease on the cheeks was of the florid, superficial type, being bright red rather than violaceous, but on the scalp was much deeper. The patient had had treatment of various kinds, without any material benefit, for two or three years. When she came under my care she was at once put on large doses of quinin internally and frequent applications of strong alcohol locally. Under this treatment improvement was for a time very marked, but after a while the patches on the cheeks, which had almost disappeared, again became active. It was then decided to try the effect of repeated freezing, the patches behind the ears being selected for the experiment. At first the freezing was done at intervals of four or five days, but owing to the difficulty in securing the patient's regular attendance it was frequently a week between the séances. A favorable effect was at once manifest; the patches gradually grew paler and finally disappeared. The lesions on the cheeks were then subjected to the same treatment, and improvement was also soon manifest here, but less marked than in the patches first treated. After three months of such treatment the patient left the city for her summer home, and the applications of the ethyl chlorid were unwisely trusted to members of the patient's family, with the usual unsatisfactory result. On the patient's return in the autumn but little further improvement was noticed, and the freezing

Digitized by Google

was given up—unwisely, as I think—for the *x*-ray, which was entirely without favorable effect. The patient soon after passing from my care, the further course of the disease is unknown. Although carried out under somewhat unfavorable circumstances, the treatment was undoubtedly beneficial up to a certain point.

CASE 2.—D., a clerk, 35 years old, came to the skin dispensary of the University Hospital some two years ago for the treatment of a dime-sized patch of erythematous lupus situated on the bridge of the nose, of several months' duration. After some months of the usual treatment without any visible result, freezing with ethyl chlorid was begun. Owing to the fact that the patient lived some distance from the city and could not always obtain leave of absence from his place of business, the treatment was carried out in very irregular fashion, there being frequently periods of three or four weeks or more during which no applications of the spray were made. Notwithstanding this, a steady, although slow, improvement was manifest. When last seen, a few months ago, there was practically no trace of active disease, there being only a slight amount of the scar-like atrophy common after this affection.

CASE 3.—Miss M. S., 52 years old, had numerous patches of erythematous lupus on the scalp, nose, cheeks, sides of the neck, mucous membrane of the lower lip and backs of the hands. The disease had lasted eight years and had been treated by the family physician without benefit. The patch on the scalp was the largest, being about the size of a silver dollar; this was selected for the application of the ethyl chlorid spray. After the second application some slight improvement was visible, and after the fourth, to quote from my note-book, "remarkable improvement" was noted. Unfortunately, the patient found the freezing of the scalp extremely painful—so much so, that the treatment had to be given up. It may be said here that, while a certain amount of pain follows the freezing, it is rarely severe enough to cause much complaint from the patient. In this case, notwithstanding the small number of the applications of the spray, the improvement was immediate and marked.

CASE 4.—J. W., 29 years old, a stonemason by occupation, had a marked erythematous lupus of thirteen years' standing, affecting the ears and the cheeks. The disease was most severe on the ears, where it had produced a marked scar-like atrophy, the lobes having practically disappeared. This patient had been under the care of a distinguished dermatologist of Edinburgh for a considerable period, but had derived but little benefit from treatment. The use of the ethyl chlorid spray at intervals of five days to one week, which was as often as the patient could be induced to come for treatment, in six weeks' time produced decided change for the better; and this improve-

Digitized by Google

ment continued until, at the end of three months, the small patches on the cheeks had disappeared. While there was some improvement in the condition of the ears, the favorable effects of the treatment in this situation were much less marked than on the cheeks. It may be noted that the use of the spray on the ears was attended by considerable, but not unbearable, pain.

CASE 5.—W. B., 25 years old, a clerk by occupation, has patches of erythematous lupus on both cheeks, on lower lids, and behind ears, the first of which made its appearance eighteen months ago. The patches on the cheeks and on the lower lids have been treated by freezing with ethyl chlorid during the past three months, at intervals of three to four days. After six weeks of this treatment the patch beneath the right eye, on which the freezing had been begun, was so much paler as to be scarcely noticeable, and the smaller of the two patches on the cheeks had likewise almost disappeared. That the improvement was due to the freezing is evident from the fact that there was no perceptible change under other local treatment employed prior to the use of ethyl chlorid. This case is still under treatment.

While it is difficult to draw any very positive conclusions from observations based on the treatment of so small a series of cases, yet I think we may conclude that repeating freezing of patches of erythematous lupus has a decidedly beneficial effect. In not a single one of the cases in which I have tried it has it failed to produce a more or less marked improvement, and in some it was followed by the complete disappearance of the disease in limited areas. In conclusion, I believe that, when employed in conjunction with large doses of quinin internally, repeated refrigeration is an extremely useful procedure in the treatment of this usually very intractable disease.

DISCUSSION.

DR. M. L. HEIDINGSFELD, Cincinnati—I wish to report my results from a preparation which I have been using for the treatment of this affection with a great deal of success and satisfaction for the past three or four years. It is the local application of 40 per cent. resorcin in gelanthum, applied once weekly or even fortnightly by means of a probe wrapped with a small pledget of cotton. Inasmuch as the gelanthum is somewhat troublesome to obtain, and is easily contaminated

Digitized by Google

by molds, I have substituted the following linamentum exsiccans as a solvent vehicle for the resorcin:

℞.	Gum tragacanth	grs. xxx	2
	Glycerini	ʒiss	6
	Acidi salicylici	grs. xv	1
	Aquæ destil, q. s. ad	℥iiiss	105

M. Coque. Ft. fluid. gelat.

This 40 per cent. resorcin preparation is easily applied, invisible, rapidly cleanses and detergates the inflamed surface, and is soothing and unirritating in character. I have often applied it in close proximity to the mucous membrane of the eye without the slightest irritation or discomfort to the patient. I have effected an apparently complete and permanent cure in several cases and very favorable results in a number of others who are still under observation or treatment. Dr. Hartzell's remedy certainly merits our attention, and is worthy our careful consideration, in the light of his highly satisfactory results.

Dr. C. W. Allen, New York City—There is no question that freezing is very beneficial in lupus erythematosus. You can freeze a patch with liquid air with great benefit, but since liquid air is not available to all, it is well we should know about ethyl chlorid, which can be obtained by any practitioner anywhere. There are very many methods of successfully treating lupus erythematosus and it is, on the whole, a rather interesting disease to treat. I approve of curettage, which usually is not mentioned and not much practiced. If the curetting is done in a particular way it is not very painful. If the border of the patch is undermined and the curetting done from within outward it can be done with comparatively little pain and with great success if followed up and carried out carefully. I have succeeded in that way in curing patients without other treatment. Dr. Hartzell mentioned the internal use of quinin in conjunction with the external use of ethyl chlorid. I think the internal use of quinin for the wandering cases, the scattering patches, the coming and going forms, is of advantage, and it can be used in connection with various external applications, one of them being iodin, which has been more or less exploited.

Dr. David Lieberthal, Chicago—I had an opportunity to treat a case of lupus erythematosus with alcohol and ether, as employed by H. v. Hebra. I prescribed each separately, advising him to mix them before application. During the course of his treatment the bottle of alcohol was broken and the patient continued the use of the ether alone. The improvement was more apparent than before, which was no doubt due to the ether having a lower point of evaporation than the alcohol.

Digitized by Google

Therefore, Dr. Hartzell's successful employment of ethyl chlorid seems very plausible.

Dr. J. B. Kessler, Iowa City, Iowa—It is difficult to treat this protean disease. I have tried scarification with good results and without result and have found from my limited experience that the form of treatment that is best for cases which involve the follicles sufficiently deep to produce pus, is the *x*-ray, but with the more superficial variety I have used the *x*-ray to a considerable extent without any benefit whatever. I remember one old man in our town, a constant rounder, who will receive treatment at any and all times if you do not charge him, who had a patch on his hand, nose and ear. He had some proprietary preparation for his nose, but we have healed the hand two or three times with the *x*-ray. I recall one man in particular who had a patch on his nose that was crusted with some pus beneath the crust. I used all the remedies I could think of in the way of carbolic acid, scarification, and other things. After eight or ten applications of the *x*-ray this remained healed and the skin was smooth. I saw the man a year after and the result was perfect.

Dr. Isadore Dyer, New Orleans—In the past year I have cured two cases of deep-seated lupus erythematosus with the *x*-ray; in the irregularity of clinics in a large city I find that ichthyol in collodion gives me the best service. A 20 per cent. solution will remove the patch within ten or twelve days in the simple superficial types.

Dr. Mortimer A. Moses, New York City—I have seen ethyl chlorid used in Lassar's clinic in Berlin in the treatment of superficial epitheliomas. The effects were good and I am surprised that no reports have been sent out from that clinic. The treatment mentioned by Dr. Allen, iodin locally and quinin internally, I have seen used in one case of severe, rather deep-seated lupus erythematosus, and there resulted an almost perfect cure within five or six months. The lupus was very extensive, almost every part of the face was involved and there was considerable thickening of the tissues.

Dr. A. Ravogli, Cincinnati—Dr. Hartzell's plan is a modification of the method of Hollander of Berlin, who spoke of this method at the International Congress last year in the Section of Dermatology. By the use of iodin and the internal administration of large doses of quinin I have treated a number of patients in my private and hospital practice, but I must say I did not get the improvement that Hollander claimed to have obtained. I think we should be careful in distinguishing the different varieties of lupus erythematosus. If we have one of the superficial forms of the disease, sometimes it disappears by itself, or with very little application, but after a while these cases come back and take the terrible proportions which we

Digitized by Google

know as lupus erythematosus diffusus. I am treating a musician now whom I have treated three times on different occasions, the disease yielding under pyrogallic acid, resorcin and ichthyol; but when nearly well he would let go, and then be back again with the disease in a much more severe form. I have treated him recently with good results, by applying a paste of formo-resorcin, 3 per cent., but although greatly improved, I have not much faith that he will be entirely cured. The treatment of this disease is one of the most difficult questions with which dermatology has to contend.

Dr. H. C. Baum, Syracuse, N. Y.—Cases of lupus erythematosus I find respond well to various sorts of treatment, but what is successful in one case often does not relieve another. I have had good results recently from the application of high-frequency currents, but how permanent these results will be I can not say, the oldest case since treatment being not more than four months. In two or three cases I was not able to complete the treatment from the fact that the patients were satisfied with the relative improvement. Those that continued seemed to have the patches cleared up entirely. In making this treatment I use the vacuum electrodes.

Dr. W. S. Gottheil, New York City—There seems to be hardly any remedy that will not occasionally cure cases of lupus erythematosus; and, on the other hand, there are some cases that no remedy will cure. I have been more impressed with a series of bad cases that had been treated with the cautious applications of trichloracetic acid, and which were shown by Dr. E. Pisko of New York, at the Manhattan Dermatologic Society last winter, than with any other therapeutic measures. A single light application of the deliquesced crystals was made, followed by wet applications or emollient salves. There was considerable though only temporary pain; and the resultant eschar left superficial scars behind. I should consider it applicable, however, only to advanced cases, in which cicatricial deformity is inevitable, or has already occurred. I have had cures from the use of the Finsen light, as I reported in the *International Journal of Surgery* last year. The treatment that Dr. Hartzell advocates, which is that which Dethlefsen proposes for lupus vulgaris, seems to be ideal.

Dr. F. J. Wallis, Philadelphia—I think the suggestion is worth trying in other cases beside lupus, provided we could lessen the irritation. Oil silk covering the lupus might give the same results.

Dr. M. B. Hartzell—In answer to Dr. Lieberthal's question regarding the applications made between the freezings, I would say that in some, perhaps most cases, no other applications at all were made. In a few absolute alcohol was mopped on. The only originality claimed for this treatment is its

Digitized by Google

use in this particular disease; as has been said, this was introduced by Dethlefsen in lupus vulgaris. I am very glad that Dr. Dyer finds ichthyol so effective. If I understood him aright he said he had no occasion to use anything else.

DR. DYER—In the superficial cases, the coming and going, evanescent cases.

DR. HARTZELL—The disease is usually a very obstinate one, but in some instances the patches disappear spontaneously. One of the most extensive cases I ever saw treated with some indifferent application got well in two or three months' time, and in two months more was worse than ever. This method is not offered as an infallible remedy for lupus erythematosus. Ethyl chlorid was used because it was the most convenient and most effective method of producing freezing of the skin.

Digitized by Google

A SECOND CASE OF CREEPING ERUPTION (LEE).

LARVA MIGRANS (CROCKER), HYPONOMODEMA (KAPOSIS), DERMAMYIASIS LINEARIS MIGRANS ŒSTROSA (KUNIBERG); WITH BRIEF REFERENCE TO THREE OTHER CASES UNPUBLISHED.

HENRY W. STELWAGON, M.D.

PHILADELPHIA.

It is apparently only recently that this extremely curious and distinctive malady has come under American observation. It would seem, in fact, likewise rare in other countries—Russia, judging from published reports, recording the most cases. In our own country, so far as I am aware, only a few cases have been observed. Van Harlingen[1] was the first, I think, of our American colleagues who, a few years ago, reported some cases. His paper was followed by my own report[2] of a case before this Section in 1903. More recently Hamburger[3] added one case, and reviewed those previously reported. Inasmuch as both Van Harlingen's and Hamburger's papers go into the subject of the literature and speculations as regards the particular parasite, and the latter discusses its relation to myiasis, I shall content myself by simply presenting a brief report of my second case.

1. Van Harlingen: Report of Three Cases of Creeping Larvæ in the Human Skin (Hyponomoderma, Kaposi), Amer. Jour. Med. Sci., September, 1902.

2. Stelwagon: A Case of Creeping Eruption, Trans. Section of Cutaneous Medicine and Surgery of the A. M. A. for 1903 and Jour. Cutan. Dis., November, 1903.

3. Hamburger: Creeping Eruption; Its Relations to Myiasis, Jour. Cutan. Dis., May, 1904.

Digitized by Google

In my paper of last year the larva discovered in some of the Russian cases was referred to. I might add that, excepting the Russian findings, no others have succeeded in getting hold of the organism.

The features of these remarkable cases are pretty much alike, varying as to the amount of inflammatory reaction, the surface traversed, and the duration of the malady. The notes of the second case that came under my observation last June, at the skin dispensary of the Jefferson Medical College Hospital, are necessarily brief. The patient, a male adult, a Pennsylvanian, had just returned from South America. It was before reaching here that his attention was called to a slight irritation on the dorsal aspect of his left foot, toward the inner side. This at first consisted of a short, elevated, slightly red line. It extended slowly from day to day. When he came under my care the eruption had, according to his statement, lasted ten days. The line was at this time about four to five inches long, and, as shown in the accompanying photograph, somewhat tortuous and irregular, and extended from the lower part of the instep up to a little above the ankle, having begun, as already noted, in the former region. As to its characters, it differed but slightly, if at all, from the case reported last year, except as to its limited extent and the presence of but one parasite. It will be recalled that in the case of last year both the back and the lower leg region were the seats of a similar eruption; on the back it was extensive, but had ceased to be active when the case came under my observation; while on the lower part of the leg there was an active and still extending line. As the back eruption, according to the boy's father, was still active when that on the ankle began, it was evident in that instance there were two parasites present. In the case I am now reporting there was but the one extending line, and, inferentially, but one parasite. When this case was first seen by me the beginning part of the line had already almost sunken to the normal skin level, and

Digitized by Google

the redness here in great part gone, leaving behind slight pigmentation. Further along the line-like ridge was quite noticeable, looking in some parts solid, in others vesicopapular and in others distinctly like a narrow, irregular linear vesicle, having, roughly speaking, a chain-like or bead-like aspect. Toward the extending end it was more of an erythematopapular nature, and at the

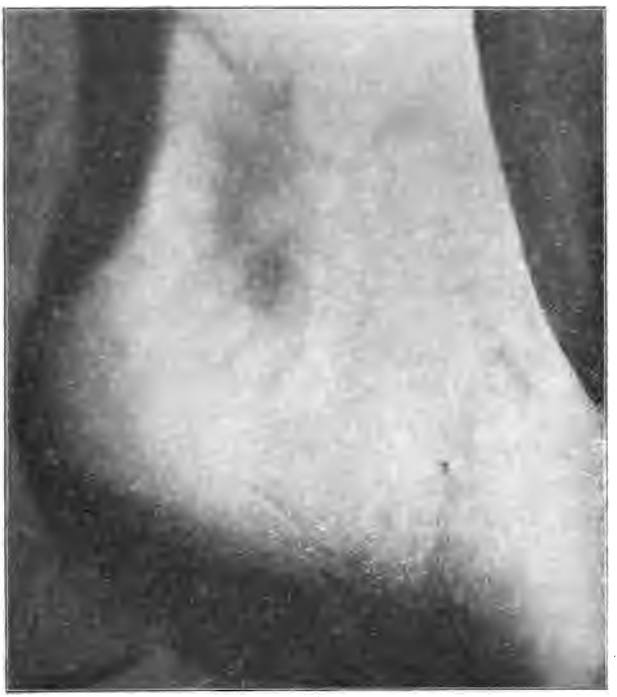

Larva migrans.

extreme end merely showed as a thread-like erythematous line, scarcely elevated. In this case, by pressing a piece of glass on the region of the extreme end of the line, and then using a magnifying glass, I could detect what seemed to be the parasite, appearing as a minute, grain-like grayish-black speck or dot just beyond the recognizable end of the line. Examined thus on three consecutive days, the same grain-like speck was seen, and

Digitized by Google

always slightly ahead of the extremity of the still extending line. Attempts made to secure it, however, were not successful, but the attempts were not of a very active kind, inasmuch as the patient would not permit an excision of a small section for this purpose.

The treatment of the case of last year consisted in the administration of asafetida, the cataphoretic application of a solution of corrosive sublimate to the suspected region, and touching the suspected site of the parasite with nitric acid. Although this polytherapeutic method was successful, it left me in doubt as to the effective agent. This being the fact, I began first in the present instance by employing the daily cataphoretic application of the corrosive sublimate solution for a period of three days, but with no apparent effect, the line continuing to extend as before, a fractional part of an inch daily. This was then discontinued, and an application of a minute droplet of nitric acid made to the suspected site of the parasite; this was followed by complete cessation of further progress, and the subsequent gradual disappearance of the ridge.

The opportunity of including brief descriptive references to the three other cases referred to in the title I owe to the kindness of Dr. Grover W. Wende of Buffalo, N. Y. In regard to these, Dr. Wende's letter may be quoted as follows:

I saw the patient but once, and wanted to make further examination before reporting. This was, however, denied me, as the patient was not again brought under my notice. The patient was a boy, aged 9. The condition began on the dorsal aspect of both hands, near the cleft of the thumb and forefinger, and in the space of about five months had traveled over both arms and the chest. The boy's mother said that the disease began in the fall, after a stay at a summer resort. She, too, had contracted the malady, which affected the sole of her right foot; it remained four weeks, disappearing after the repeated applications of vinegar and gunpowder. She also tried this home combination on the boy, but without result. It was then that she called at the Buffalo University Dispensary, but seemed to be suspicious of our intention when we wanted to remove a piece for examination, and left and failed to return.

Digitized by Google

The aspect of the eruption was so characteristic of the cases reported by Lee, Crocker, Neumann and Sokolow, of larva migrans, that I did not hesitate to make such a diagnosis. The lines were irregular and serpentine, and the epidermis elevated and roughened. They ran from the hands to the shoulder joints, and then on the chest, sometimes passing almost completely around the arms, the lines being broken in places. I regret that I was not able to follow up this interesting case.

As to the third case, Dr. Wende continues:

In July, 1901, Dr. F. B. Green of Elmira, N. Y., wrote me about a case, which from its description was undoubtedly one of larva migrans. In this instance the entire back was involved in such a way that the lines strangely crossed and recrossed each other.

It will be observed that in the extensive case which came under Dr. Wende's observation, beginning on both hands, there were evidently two parasites also present. Possibly it is only a curious coincidence, and scarcely worth particular mention, but it will be noted that in one of Van Harlingen's cases and in two of my own the malady began at or after a visit to the sea or seashore. In the two cases noted by Dr. Wende it began at or immediately after a visit to a summer resort; whether, however, connected with a watering place is not stated, but being in the neighborhood of Buffalo, it probably was.

Another point of interest, as shown in these cases, as well as in others reported, is that the eruption is almost always observed to have its origin on those parts of the body most exposed to inoculation and invasion—hands or lower part of the forearms, the feet or lower part of the leg, and the buttocks or adjacent part of the back.

DISCUSSION.

Dr. J. F. Schamberg, Philadelphia—About a year ago a patient, a young woman, exhibited on the arms and hands a bullous eruption which in places was characterized by long vesicular trails arranged in a whiplike manner, with loops of the so-called whip coiled on themselves, suggesting the burrowing of a parasite. This condition lasted a number of weeks, appeared to get well under treatment, subsequently relapsed and the patient disappeared. The character of these peculiar vesicular trails has suggested to me, since seeing Dr.

Digitized by Google

Stelwagon's photographs, that possibly the case was one of larva migrans.

Dr. J. W. Lord, Baltimore—I exhibited a patient with larvæ migrans in 1897, a Bohemian who had been in this country for many years. She came to us after being in the country picking berries. The eruption at the time was of six weeks' duration. The lower part of the eruption was about an inch in extent. I made a microscopic examination but could find nothing. The eruption stopped at that point and the woman recovered.

Dr. Louis P. Hamburger, Baltimore—The Russian observers find the larva with great facility. It is the larva of the bot fly inhabiting the stomach of the horse, the *Gasterophilus equi*. The Russian patients are usually peasants who work in the fields and are thereby exposed to the infection. In my patient a larva could not be detected. Here, as well as in many other cases, the buttock has been the starting point of the disorder. This fact suggests that the toilet may be the source of the infection, either directly through a privy fly, or, perhaps, secondarily, to an intestinal infection, the stool being the carrier of the larva. Although the larva of the horse bot fly has been demonstrated in the Russian examples of the disease, it is probable that the same larva is not responsible for all the cases.

Digitized by Google

EXECUTIVE SESSION.

TUESDAY, JUNE 7.

The Section was called to order by the Chairman at 2 p. m.

Dr. Henry G. Anthony, Chicago, then read the Chairman's Address, "The Developmental Defects of the Skin and Their Malignant Growths." Discussed by Drs. Fordyce, Ravogli, Corlett, Heidingsfeld, Montgomery and Anthony.

"Falling of the Hair," by Dr. R. A. McDonnell, Connecticut. Discussed by Drs. Ludwig Weiss, Kessler, Cox, Ravogli and McDonnell.

Dr. John A. Fordyce, New York, read a paper entitled "Report of a Case of Paget's Disease of the Gluteal Region." Discussed by Drs. Stelwagon and Pusey.

"Radium and Its Therapeutic Possibilities," by Dr. William Allen Pusey, Chicago. Discussed by Drs. Schamberg, Bulkley, Heidingsfeld and Pusey.

"Linear Nevi," by Dr. M. L. Heidingsfeld. Discussed by Drs. Pusey and Heidingsfeld.

Dr. John V. Shoemaker, Pennsylvania, exhibited a "Remarkable Case of Xanthoma," which was discussed by Drs. Brayton, Pusey, Lieberthal, Cox, Schamberg, Montgomery, Heidingsfeld, Bulkley, Anthony and Shoemaker.

Under "New Business," Dr. W. L. Baum, Chicago, stated that the American Dermatological Association had appointed Dr. Stelwagon to use his best efforts toward securing the meeting of the International Dermatological Congress, three years hence, for New York City, and made a motion that this Section give similar instructions to Dr. Stelwagon. Motion carried.

WEDNESDAY, JUNE 8.

The Section was called to order by the Chairman at 2 p. m.

The Chairman announced as a Nominating Committee Drs. Baum, Kessler and Corlett.

"A False or Cicatricial Keloid," by Dr. A. Ravogli. Discussed by Drs. Gottheil, Baum (New York), Wallis, Moses, Heidingsfeld and Ravogli.

The Chairman introduced Dr. Charles B. Cooper, Honolulu, Hawaii, who said: "I do not make any pretense at being a dermatologist; I am a general practitioner. In the territory of Hawaii we have had charge of the leper stations. Leprosy was first discovered among the islanders in 1848, and it spread to such an alarming extent that in 1864 or 1865 the legislature decided that all persons having the disease must be segregated.

Digitized by Google

A place on the island of Molokai was picked out, comprising an area of 7,000 acres, hemmed in by high mountains from 2,000 to 4,000 feet high, and which can only be approached by a very narrow pass, which is constantly guarded. Since 1864 there has been sent to the settlement about 5,000 cases of different nationalities, over 55 per cent. being Hawaiians and not over 50 per cent. Caucasians. It is a great burden on the taxpayers to keep up the settlement, and especially so since the annexation to the United States, by which the income of the territory is depleted of $120,000 a month, which goes to the federal treasury. We are very anxious that something more should be done than we are able to do for the scientific investigation of this disease, and it was with that idea that I made this trip. I attended a meeting of the state and territorial officers in Washington a few days ago, and have come here in hopes that this Section would be interested to take up the matter. I feel sure that something will be done for the scientific research work in finding a cure for the disease. I have a collection of photographs of different types of the disease, also views of the settlement, showing their homes and how they live, with their surroundings."

In reply to a question Dr. Cooper said further: There is no doubt about leprosy being very mildly contagious, and it is less so among Caucasians, who live in proper hygienic surroundings, than among the natives, who eat with their fingers out of the same bowl, rub their noses together when they kiss and become inoculated through the mucous membrane. Only about 49 Americans have taken the disease since 1864; at the same time I do not think any chances should be taken. The only safety lies in absolute segregation. The Hawaiian Islands are known to have been inhabited for hundreds of years. A hundred years ago there were probably 400,000 inhabitants; to-day there are 55,000. There is no record of leprosy among them previous to 1848, and their diet has been the same from time immemorial. Leprosy is supposed to have been brought to the islands by Chinese coolies about 1840, or it might be by ships from the South Sea Islands, where leprosy existed. But the general belief is that it was brought in by the Chinese, and to-day it is called by the natives "Chinese sickness."

Dr. Cooper's report was discussed by Drs. Montgomery, Schamberg, Corlett and Cooper.

"Psorospermosa Cutanée Vegetante Folliculaire: Darier's Dermatosis; Keratosis Follicularis (White)," by Dr. David Lieberthal, Chicago. Discussed by A. Ravogli, Bulkley and Lieberthal.

Dr. Henry Stelwagon, Philadelphia, read a paper entitled "A Second Case of Larva Migrans." Discussed by Drs. Schamberg, Lord and Hamburger.

Digitized by Google

"Acne Keratosa," by Dr. W. S. Gottheil. No discussion.

"Cover-Glass Cultures, and Their Possibilities in Studying the Epidermic Fungi," by Dr. J. Frank Wallis. Discussed by Drs. Schamberg, Gottheil, Bulkley and Wallis.

"Prurigo (Hebra), as Observed in the United States," by Dr. W. T. Corlett. Discussed by Drs. Ravogli, Stelwagon, Weiss, Bulkley and Corlett.

Dr. William L. Baum, Chicago, read a paper on "Iodin Absorption and Elimination." On motion of Dr. Heidingsfeld, discussion on this paper was deferred until Thursday.

Dr. Jay F. Schamberg read a paper on "The Diagnosis of Scarlet Fever and Scarlatinoid Affection," which was illustrated by lantern slides. Discussed by Dr. Corlett.

The Chairman called the attention of the members to the desirability of subscribing to the printed transactions of the Section.

Dr. Jay F. Schamberg moved that the American Medical Association urge on the federal authorities an appropriation for the scientific investigation of leprosy in the Hawaiian Islands, looking toward the cure of the disease. Motion carried.

On motion, a vote of thanks was extended to the proprietors of the Shelburne Hotel for courtesies shown the Section.

Thursday, June 9.

The Section was called to order by the Chairman at 9:30 a. m.

Report of the Nominating Committee: Chairman, Dr. D. W. Montgomery, San Francisco; Secretary, Dr. R. R. Campbell, Chicago; Delegate, Dr. A. W. Brayton, Indianapolis. On motion, the Secretary was instructed to cast the unanimous ballot of the Section for these gentlemen.

On motion of Dr. Baum, Illinois, the Chairman appointed as a committee to gather statistics and information regarding skin diseases, and the general work of the Section, Drs. Baum, New York; Schamberg, Sumney, Morros, Shelmire, Lieberthal, Heidingsfeld and Roussell, with instructions to report at the next annual session of the Section.

The discussion of Dr. W. L. Baum's paper was by Drs. Corlett, Currier, Coxe and Baum.

"The Treatment of Lupus Erythematosus by Repeated Refrigeration with Ethyl Chlorid," by Dr. M. B. Hartzell, Philadelphia. Discussed by Drs. Heidingsfeld, Allen, Lieberthal, Kessler, Dyer, Moses, Ravogli, Baum, New York; Gottheil, Wallis and Hartzell.

"An Instance Where Cutaneous Acrodermatitis Was Controlled by the *X*-Ray," by Dr. D. W. Montgomery, San Francisco. Discussed by Drs. Baum, New York; Pusey, Allen, Ravogli and Montgomery.

Digitized by Google

"A Case of Dermatitis Herpetiformis Treated with the *X*-Ray," by Dr. William Thomas Corlett, Cleveland. Discussed by Dr. Carrier.

"Comparison of Phototherapy, Radiotherapy and High-Frequency Therapy in Skin Diseases," by Dr. C. W. Allen, New York City. Discussed by Drs. Corlett, Gottheil, Hartzell, Price, Schamberg, Skinner, New York; Currier, Varney, Bulkley, Kessler and Allen.

"*X*-Ray Therapy in Skin Diseases," by Dr. G. E. Pfahler, Philadelphia. Discussed by Drs. Hartzell, Price, Brayton, Allen and Bulkley.

"The Consideration of Late Hereditary Syphilis," by Dr. R. R. Campbell, Chicago. Discussed by Drs. Brayton, Bulkley, Allen, Moses, Baum, New York, and Campbell.

Dr. W. T. Corlett, Ohio, suggested that the newly-elected Chairman and Secretary appoint a committee to investigate and report at the next annual session on the use of iodin.

On motion of Dr. Schamberg the Chairman and Secretary were instructed to request the House of Delegates to appoint a delegate from the Section on Cutaneous Medicine and Surgery to the International Dermatological Congress at its next meeting, in Berlin, during the summer.

The newly-elected Chairman, Dr. D. W. Montgomery, San Francisco, was then conducted to the chair, and made a few remarks in appreciation of the honor conferred on him.

Digitized by Google

LIST OF MEMBERS.

List of members of the American Medical Association who are making a specialty of cutaneous medicine and surgery:

(The numbers "2," "3" and "4" after the name indicate that the member registered in the Section in 1902, 1903 or 1904 respectively.)

Allen, Charles W., (2-4), 30 E. 33d St., New York City.
Anthony, H. G., (2-3-4), 465 Dearborn St., Chicago.
Baldwin, L. Blake, 481 Wabash Ave., Chicago.
Barstow, G. W., (4), Three Bridges, N. J.
Baum, William L., (2-4), 103 State St., Chicago.
Biddle, A. P., 57 W. Fort St., Detroit.
Blount, E. A., (3) Nacogdoches, Texas.
Blue, W. R., (4), Norton Bldg., Louisville, Ky.
Booth, Bradford A., (4), 6111 Scranton Ave., Pittsburg.
Bradford, G. D., (2) Homer, N. Y.
Brayton, A. W., (3-4), 24½ E. Ohio St., Indianapolis.
Breneman, P. P., (4), Lancaster, Pa.
Bulkley, Lucius D., (2-3-4), 531 Madison Ave., New York City.
Bull, T. M., (4) Naugatuck, Conn.
Campbell, R. R., (2-3-4), 204 Dearborn St., Chicago.
Cabot, Follen, (4), 129 E. 31st St., New York City.
Carrier, A. E., (4), 423 Stevens Bldg., Detroit.
Carman, J. H., (4) Plainfield, N. J.
Cocks, E. L., (2 4), 156 W. 119th St., New York City.
Collings, H. P., (4), Hot Springs, Ark.
Collings, S. P., Hot Springs, Ark.
Corlett, William T., (2-4) 553 Euclid Ave., Cleveland.
Duncan, John H., (3), Marion-Sims Medical College, St. Louis.
Dunn, J. C., 208 Winebiddle Ave., Pittsburg.
Dyer, Isadore, (3-4), 124 Baronne St., New Orleans.
Elliott, Thos., (4), Sharon, Pa.
Ewing, W. B., 32 Westinghouse Bldg., Pittsburg.
Firman, F. W., (2), Findlay, Ohio.
Fletcher, C. L., (4), Wings Station, N. Y.
Fordyce, J. A., (3-4), Larchmont, N. Y.
Foster, Burnside, Lowry Block, St. Paul, Minn.
Friedrichs, E. D., (3), New Orleans.
French, T. T., 366 Commonwealth Ave., Boston.
Frick, William, 301 Rialto Bldg., Kansas City, Kan.
Geist, J. W., (4) Wilkesbarre, Pa.
Gilchrist, Thomas Casper, 317 N. Charles St., Baltimore.
Gold, J. D., (4), Bridgeport, Conn.
Gotthell, W. S., (2-4) 144 W. 48th St., New York City.
Griffin, J. F., (3), Tiptonville, Tenn.
Hamlin, O. D., (4), Oakland, Cal.
Hartzell, Milton B., (2), 3634 Chestnut St., Philadelphia.
Hay, E. C., (4), Hot Springs, Ark.
Heidingsfeld, M. L., (2-3-4), Lancaster Bldg., Cincinnati.
Henderson, R. G., (3), Memphis, Tenn.
Hoffman, J. Y., (4), Reading, Pa.
Hopkins, Ralph, (3-4), 124 Baronne St., New Orleans.
Horck, Max Vander, (3) Minneapolis.
Hurlburt, S. R., 626 Dearborn Ave., Chicago.
Hutchins, Miller Bone, 1007 Century Bldg., Atlanta, Ga.
Hyde, James N., 100 State St., Chicago.
Kessler, J. B., (3-4), Iowa City, Iowa.
Langfitt, N. J., (4), Allegheny, Pa.
Lieberthal, D., (2-4), 103 State St., Chicago.
Linville, M., (4), Newcastle, Pa.
Lord, J. W., 1011 N. Charles St., Baltimore.
McDonnell, R. A., (4), New Haven, Conn.
McGehee, E. P., (4), Lake Village, Ark.
Mewborn, A. D., 224 W. 52d St., New York City.
McNeil, E. K., (3), Jackson, Tenn.
Menage, H. E., (3), New Orleans.

Digitized by Google

Montgomery, Douglas W., (4), 1301 Van Ness Ave., San Francisco.
Montgomery, Frank H., 100 State St., Chicago.
Minor, J. C., (3), Hot Springs, Ark.
Peterkin, G. S., (4), 48-49 Haller Bldg., Seattle, Wash.
Pfahler, G. E., (4), 1409 Spruce St., Philadelphia.
Piffard, H. G., (4), 256 W. 57th St., New York City.
Pollitzer, Sigmund, 64 E. 58th St., New York City.
Price, J. C., (4), Scranton, Pa.
Pusey, William Allen, (2-4), 65 Randolph St., Chicago.
Quirk, John J., 103 State St., Chicago.
Ravogli, A., (2-4), 5 Garfield Pl., Cincinnati.
Reade, T. M., (4), Springfield, Ohio.
Robinson, Andrew Rose, 159 W. 48th St., New York City.
Rosenthal, M. S., (4), 211 W. Franklin St., Baltimore.
Roussel, J. Numa, (3), 5333 Coliseum, New Orleans.
Schamberg, J. F., (2-3-4), 1636 Walnut St., Philadelphia.
Schmidt, L. E., (2), 424 N. State St., Chicago.
Sherwell, Samuel, (2), 33 Schermerhorn St., Brooklyn.
Shelmire, J. B., (3), Dallas, Tex.
Shoemaker, John V., 1519 Walnut St., Philadelphia.
Stearns, B. W., (4), Binghamton, N. Y.
Stern, Charles S., (4), 137 W. 126th St., New York City.
Stelwagon, Henry W., (2-4), 1634 Spruce St., Philadelphia.
Sumney, H. C., 305 Karbach Block, Omaha.
Swarts, G. T., (2-3-4), Providence, R. I.
Swoboda, L., (4), 301 Paxton Block, Omaha.
Tice, Frederick, 1453 W. Monroe St., Chicago.
Varney, H. R., (2 3-4), 420 Woodward Ave., Detroit.
Varney, M. E., (2) Saratoga Springs, N. Y.
Wallis, J. Frank, (2-4), 245 Pine St., Philadelphia.
Wayland, A. B., (4), Crozet, Va.
Wende, Grover William, (2), 471 Delaware Ave., Buffalo.
Weiss, Ludwig, (2-3-4), 77 E. 91st St., New York City.
Whaley, T. P., 113 Wentworth St., Charleston, S. C.
Wolf, W. B., (4), 13 W. Franklin St., Baltimore.
Wolff, H. D., (3), 1374 35th St., Chicago.
Young, J. K., (4), 222 S. 16th St., Philadelphia.
Zeisler, Joseph, 100 State St., Chicago.

Digitized by Google

INDEX.

PAGE.

Acne Keratosa 112
Allen, C. W., Comparison of Phototherapy, Radiotherapy and High-frequency Therapy in Skin Diseases..... 165
Allen, C. W., discussion on continuous acrodermatitis, 153; on late hereditary syphilis, 208; on lupus erythematosus, 265; on phototherapy in skin diseases, 182; on *x*-ray therapy in skin diseases, 193.
Anthony, H. G., Skin Defects..... 9
Anthony, H. G., discussion on skin defects, 25; on xanthoma, 226.
Baum, H. C., discussion on continuous acrodermatitis, 153; on keloids, 92; on late hereditary syphilis, 208; on lupus erythematosus, 267; on phototherapy, etc., in skin diseases, 178; on xanthoma, 226.
Brayton, A. W., Diabetes Insipidus..... 129
Brayton, A. W., discussion on late hereditary syphilis, 207; on xanthoma, 223; on x-ray therapy in skin diseases, 193.
Bulkley, L. D., Use and Abuse of Ointments..... 227
Bulkley, L. D., discussion on cover-glass cultures, 148; on Darier's disease, 78; on hyperidrosis pedum, 111; on late hereditary syphilis, 207; on phototherapy, etc., in skin diseases, 180; on prurigo, 128; on radium, 63; on xanthoma, 226; on *x*-ray therapy in skin diseases, 194.
Campbell, R. R., Late Hereditary Syphilis..... 195
Campbell, R. R., discussion on late hereditary syphilis, 208.
Cocks, E. L., discussion on falling of the hair, 39; on prurigo, 126; on xanthoma, 225.
Continuous Acrodermatitis 150
Corlett, W. T., Prurigo (Hebra)..... 123
Corlett, W. T., discussion on phototherapy, etc., in skin diseases, 176; on prurigo, 128; on radium, 62; on scarlet fever, 164; on skin defects, 24.
Cover-glass Cultures and Their Possibilities in Studying Epidermic Fungi 127
Creeping Eruption (Lee), Second Case of..... 269
Currier, A. E., discussion on phototherapy, etc., in skin diseases, 180.
Cutaneous Manifestations in Diabetes Insipidus..... 129
Darier's Disease, Case of..... 66
Developmental Defects of the Skin and Their Malignant Growths 9
Diabetes Insipidus, Cutaneous Manifestations of..... 129
Discussion on continuous acrodermatitis..... 153
Discussion on cover-glass cultures..... 147
Discussion on creeping eruption..... 273
Discussion on Darier's disease..... 78
Discussion on falling of the hair..... 37
Discussion on hyperidrosis pedum..... 111

Digitized by Google

PAGE.
Discussion on keloids..... 92
Discussion on late hereditary syphilis..... 207
Discussion on lupus erythematosus..... 265
Discussion on phototherapy, etc., in skin diseases..... 176
Discussion on prurigo (Hebra)..... 126
Discussion on radium..... 62
Discussion on scarlet fever..... 164
Discussion on skin defects..... 23
Discussion on xanthoma..... 223
Discussion on x-ray therapy in skin diseases..... 191
Dyer, I., discussion on lupus erythematosus, 266.
Executive session 275
Falling of the Hair..... 28
False or Cicatricial Keloid..... 80
Fordyce, J. A., discussion on skin defects, 23, 25.
Gottheil, W. S., Acne Keratosa..... 113
Gottheil, W. S., discussion on cover glass cultures, 147; on keloids, 92; on lupus erythematosus, 267; on photo-therapy, etc., in skin diseases, 177.
Hair, Falling of the..... 28
Hamburger, L. P., discussion on creeping eruption, 274.
Hartzell, M. B., Ethyl Chlorid in Lupus Erythematosus..... 261
Hartzell, M. B., discussion on lupus erythematosus, 267, 268; on photo-therapy, etc., in skin diseases, 178; on x-ray therapy in skin diseases, 191.
Hay, E. C., discussion on hyperidrosis pedum, 111.
Heidingsfeld, M. L., Linear Nevi..... 239
Heidingsfeld, M. L., discussion on keloids, 93; on skin defects, 25; on radium, 64; on xanthoma, 225.
Hyperidrosis Pedum and Its Treatment by Baths of Permanganate of Potash..... 95
Kessler, J. B., discussion on falling of the hair, 37; on lupus erythematosus, 266.
Lieberthal, D., Darier's Disease..... 66
Lieberthal, D., discussion on Darier's disease, 79; on lupus erythematosus, 265; on xanthoma, 223.
Linear Nevi 239
List of Members..... 279
Lord, J. W., discussion on creeping eruption, 274.
Lupus Erythematosus Treated by Repeated Refrigeration with Ethyl Chlorid..... 261
McDonnell, R. A., Falling of the Hair..... 28
McDonnell, R. A., discussion on falling of the hair, 40.
Montgomery, D. W., Continuous Acrodermatitis..... 150
Montgomery, D. W., discussion on continuous acrodermatitis, 154; on keloids, 92; on skin defects, 25; on xanthoma, 225.
Moses, M. A., discussion on Darier's disease, 78; on keloids, 93; on late hereditary syphilis, 208; on lupus erythematosus, 266.
Ointments, Their Use and Abuse..... 227
Pfahler, G. E., X-ray Therapy in Skin Diseases..... 184
Photo-therapy, Radio-therapy and High-frequency Therapy in Skin Diseases, Comparison of..... 165
Price, J. C., discussion on x-ray therapy in skin diseases, 192.

Digitized by Google

PAGE.
Prurigo (Hebra) as Observed in the United States..... 123
Pusey, W. A., Radium..... 41
Pusey, W. A., discussion on continuous acrodermatitis, 153; on radium, 64; on xanthoma, 223.
Radium and Its Therapeutic Possibilities..... 41
Ravogli, A., False or Cicatricial Keloid..... 80
Ravogli, A., discussion on continuous dermatitis, 154; on falling of the hair, 39: on Darier's disease, 78; on hyperidrosis pedum, 112; on keloids, 93; on lupus erythematosus, 266; on prurigo, 127; on skin defects, 23, 24.
Scarlet Fever and Scarlatinoid Affections, Diagnosis of..... 155
Schamberg, J. F., Scarlet Fever..... 155
Schamberg, J. F., discussion on cover-glass cultures, 147; on creeping eruption, 273; on photo-therapy, etc., in skin diseases, 179; on radium, 62; on xanthoma, 225.
Shoemaker, J. V., Xanthoma..... 210
Skin Defects and Malignant Growths, Developmental..... 9
Skinner, C. E., discussion on continuous acrodermatitis, 150; on photo-therapy, etc., in skin diseases, 180.
Stelwagon, H. W., Case of Creeping Eruption..... 269
Stelwagon, H. W., discussion on prurigo, 127.
Syphilis, Consideration of Late Hereditary..... 195
Varney, H. R., discussion on photo therapy, etc., in skin diseases, 180.
Wallis, J. F., Cover-glass Cultures and Their Possibilities in Studying Epidermic Fungi..... 137
Wallis, J. F., discussion on cover-glass cultures, 148; on keloids, 92; on lupus erythematosus, 267.
Weiss, L., Hyperidrosis Pedum..... 95
Weiss, L., discussion on falling of the hair, 37; on hyperidrosis pedum, 112; on prurigo, 127.
Xanthoma 210
X-ray Therapy in Skin Diseases..... 184

Digitized by Google

Digitized by Google

Digitized by Google

Digitized by Google